

Title	Female wide urethra masquerading as a urethral diverticulum in association with ectopic ureterocele
Author(s)	KONAMI, Teruo; WAKABAYASHI, Yoshihiko; TAKEUCHI, Hideo; TOMOYOSHI, Tadao
Citation	泌尿器科紀要 (1988), 34(8): 1437-1441
Issue Date	1988-08
URL	http://hdl.handle.net/2433/119667
Right	
Type	Departmental Bulletin Paper
Textversion	publisher

FEMALE WIDE URETHRA MASQUERADING AS A URETHRAL DIVERTICULUM IN ASSOCIATION WITH ECTOPIC URETEROCELE

TERUO KONAMI, Yoshihiko WAKABAYASHI, Hideo TAKEUCHI
and Tadao TOMOYOSHI

*From the Department of Urology, Shiga University of Medical Science
(Director: Prof. T. Tomoyoshi)*

A rare case of wide urethra in a female infant mimicking as a urethral diverticulum in association with ectopic ureterocele is reported. The ureterocele terminated just below the bladder neck, but the diverticulum-like structure everted from the wide urethra, protruding towards the ureterocele. Weakness of the urethral wall, distal to the actual ureterocele may produce such an abnormal radiologic finding. The pertinent literature is reviewed.

Key words: Ectopic ureterocele, Wide urethra, Female, Urethral diverticulum

INTRODUCTION

An ectopic ureterocele may demonstrate variable radiologic abnormalities of the lower urinary tract. Urethral dilatation in association with prolapsed and/or ballooning ureterocele or one due to distal urethral stenosis is well known. However, in females, megalourethra and urethral diverticulum are uncommon and usually considered as an acquired lesion. Although there are several reported cases which present as a urethral diverticulum associated with an ectopic ureterocele¹⁻⁶⁾, true diverticulum of the urethra is extremely rare. The case reported herein had a wide atonic urethra without distal urethral stenosis and with diverticulum-like dilatation of its posterior wall, distal to the actual ureterocele. We could find only case simulating that of William's¹⁾ in the pertinent literature. Possible explanations of this abnormality are discussed.

CASE REPORT

M.K., a 3-month-old female infant was hospitalized for recurrent attacks of pyelonephritis, vomiting and failure to thrive. Urine specimens revealed many white cells with significant growth of *Escherichia coli*. Physical examination was normal except for the patulous external urethral

meatus, opening above the vaginal introitus (Fig. 1). An excretory urogram (IVP) demonstrated a faint right pelvicalyceal system, which shows a drooping flower sign, with a filling defect in the bladder. Transurethral catheterization was difficult because of resistance about 3 cm proximal to the external urethral meatus. Injection of the contrast media showed a wide urethra with a round diverticulum-like shadow protruded up toward the bladder (Fig. 2, A, B). By sounding the urethra, a 12F, Foley catheter could be introduced

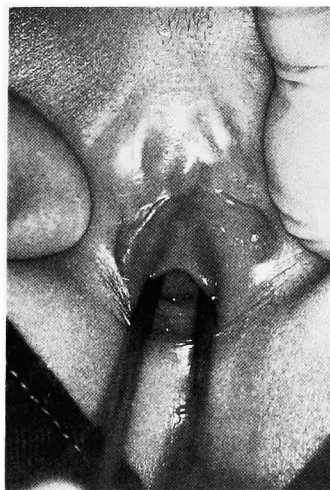

Fig. 1. Patulous external urethral meatus opening above the vaginal introitus.

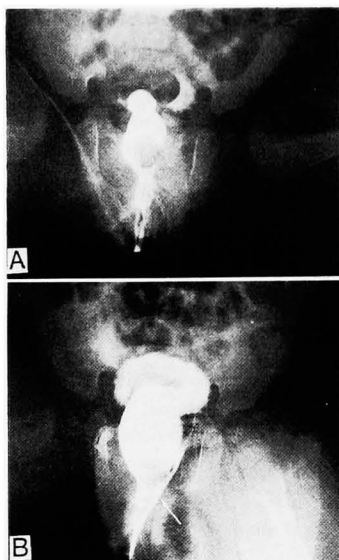


Fig. 2. Retrograde urethrograms.

- A; Dilatation of the urethra was demonstrated with round protrusion of the right upper portion toward the bladder.
 B; More contrast media instilled into the urethra. Urethral dilatation was clearer. White arrow shows the catheter introduced into the vagina.

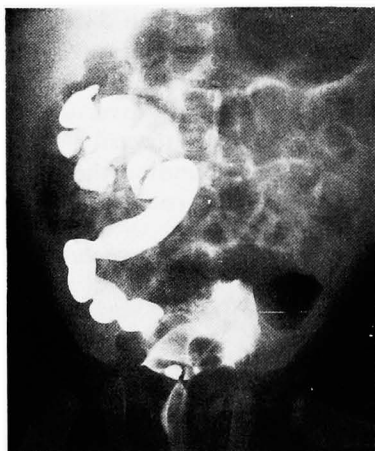


Fig. 3. Cystography shows massive VUR to the lower kidney. Intubated catheter is displaced to the left and wide urethra with round head is demonstrated.

into the bladder. The catheter was displaced to the left and a massive vesicoureteral reflux into the lower segment of the right kidney was demonstrated by the cystography (Fig. 3). The vaginogram showed no abnormal findings. Urethrocystoscopy revealed a wide urethra with a bulging of

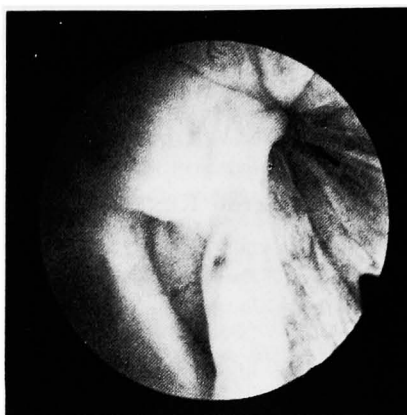

Fig. 4. Urethroscopy shows a bulging of the thinner wall with gutter formation at the right posterior aspect of the urethra, clearly demarcated from the normal urethral mucosa. Black arrow shows the internal urethral meatus.

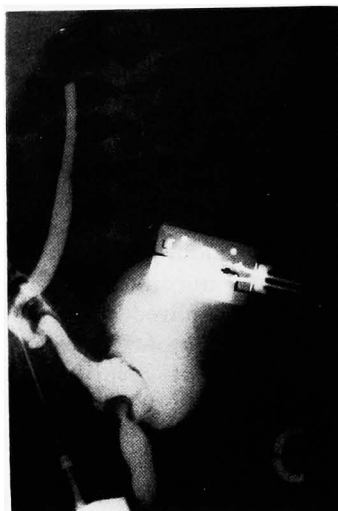


Fig. 5. Intraoperative ureterography, injected of contrast media through needle puncture into the upper ureter, demonstrates a large ureterocele producing a dome-like shadow defect at the base of its, which lumen is communicating with the urethra.

the thinner wall sectioned into several compartments by gutter formation at the right posterior aspect of the urethra, clearly demarcated from the main urethral wall (Fig. 4). This bulging gradually disappeared and the urethral wall extended posteriorly, when the urethral cavity was filled with water. Cystoscopy confirmed

the presence of a ureterocele which terminates just below the bladder neck but did not disclose the exact site of the orifice of the ureterocele. Because repeated renal scintigraphies showed no uptake of the right kidney and recurrent urinary tract infection continued, right nephroureterectomy was performed without removal of the ureterocele. During the operation, contrast media instilled through the upper ureter demonstrated a large ureterocele producing a dome-like shadow defect at the base of bladder, which lumen had communication with urethra (Fig. 5). The bladder was opened, and a large ureterocele was found on the right side extending to the bladder neck, where a small orifice was found at the bladder neck. The surgical specimen showed that the upper pole kidney was dysplastic and lower pole kidney showed remarkable pyelonephritic change. At the age of 3 she was readmitted for evaluation of urinary continence and cystourethroscopy. She voided with slight difficulty but urinary continence was almost completely preserved. Cystourethroscopy revealed the same bulging of urethral wall as the previous examination but ureterocele significantly decreased its size being located at the lateral vesical wall.

DISCUSSION

Possible anatomical conditions, which present as a urethral diverticulum in association with ectopic ureterocele are listed in the table. The first possibility is a false urethral diverticulum. Occasionally a dilated ectopic orifice located in the urethra with dilated ureter may

be mistaken for a urethral diverticulum¹⁻⁶. As Emmet⁷ suggested, the dilatation in such instances may result from infection. The second possibility is the eversion of the ureterocele. An everting ureterocele is a relatively new concept, characterized by a diverticulum-like protrusion outside the general contour of the bladder or urethra^{8,9}. Williams and associates²⁰ have described that occasionally the ectopic ureterocele exhibits not only ureterocele dilatation within the bladder but a second saccular dilatation lying posterior to the urethra. Koyanagi and associates⁹ have classified the everting ureterocele into 2 types; type 1 is designated when ureterocele is everting intraluminally into dilated ureter, which is issuing in bladder or urethral wall through enlarged hiatus, type 2 is designated when an ureterocele is everting exteriorly along cranial aspect of ureteral wall through loose hiatus. The eversion is clinically not uncommon, but a protrusion solely of the urethra, not of the ureterocele, can not be found in the pertinent literature. The third is the cecoureterocele, uncommon variety of ureterocele termed by Stephens^{10,11} characterized by upward migration of the developing large and incompetent ectopic ureteral orifice leaving a tongue of more distal ureter underneath the urethral mucosa demonstrating the diverticulum-like appearance in the urethra. The fourth is the ruptured ureterocele, which may be distinguishable by urethroscopy and or urethrography. Another possible anatomical condition which presents as a urethral diverticulum is a congenital urethral diverticulum. Urethral diverticuli in females are believed to be acquired lesions from infection and abscess formation in the periurethral glands¹². Although several cases of ureteral ectopia into a Wolffian ducts remnant (Gartner's duct or cyst) has been reported¹³⁻¹⁸, almost all of these cases are associated with single ectopic ureter, and the communication with bladder or urethra is rare¹⁷. The case reported herein can not be classified into any of the entities described above. The weakness

Table 1. Possible anatomical conditions of case presenting as a urethral diverticulum associated with ectopic ureterocele.

- | |
|--|
| 1 .False urethral diverticulum. |
| 2 .Everting ureterocele. |
| 3 .Cecoureterocele. |
| 4 .Ruptured ureterocele. |
| 5 .Ectopic ureter into the Gartner's duct or cyst. |
| 6 .Weakness of urethral wall. |

of the right urethral wall and the bladder neck may have resulted in a marked protrusion of the urethra outside and posterior with a patulous external urethral meatus, resembling megalourethra or urethral diverticulum. A review of the literature revealed only one case like that of William's¹⁾, which presents similar, bizarre dilatation distal to the actual ureterocele. Ectopic ureterocele sometimes involves distortion or dissection of trigone or bladder neck muscle. Several cases of the diverticulum of the floor are reported as a result of muscular defect, which produced secondary obstruction of the bladder outlet during the act of voiding¹⁹⁻²⁰⁾.

Morphological studies of the ureterocele and ureter were provided by Tokunaka and associates²¹⁾, who showed a lack of thick microfilaments in the dome of the ureterocele, concluding that the ureterocele is a segmental embryonal arrest of the most distal portion of the ureter. However, the anatomical details of the urethra associated with an ectopic ureterocele are not well understood.

Weakness of the urethral wall, clinically encountered in a prolapsed ureterocele, has been generally believed to be a result of a progressive enlargement of the ureterocele within the urethral wall¹⁹⁾. Gomez and Stephens¹¹⁾ studied the structure of the ureterocele and the accompanying vesicourethral sphincter in an autopsy case, which had a right cecoureterocele and a left sphincteric ureterocele. They demonstrated that the bladder neck and the both involuntary and voluntary sphincters were attenuated or devoid of muscle in the quadrant beneath the ureterocele and its cecal extension. We suspect that maldevelopment of the urethral wall are not so uncommon in cases with a large ectopic ureterocele, sometimes making prolapse into the posterior urethra or external urethral orifice.

It is important to distinguish the anatomical and functional abnormalities of the urethra, such as described above, when consider the operative management in the cases, which present as a urethral diver-

ticum associated with ureterocele. While in our case, the base of the ureterocele was thin and attached to the urethral wall closely, unroofing may be dangerous injuring the urethral wall or causing a more pronounced protrusion of the urethra.

REFERENCES

- 1) Williams DI and Woodard JR: Problems in the management of ectopic ureteroceles. *J Urol* **92**: 635-651, 1964
- 2) Williams DI, Fay R and Lillie JG: The functional radiology of ectopic ureterocele. *Br J Urol* **44**: 417-433, 1972
- 3) Willmarth CL: Ectopic ureteral orifice within an urethral diverticulum: report of a case. *J Urol* **59**: 47-49, 1948
- 4) Vanhoutte JJ: Ureteral ectopia into a Wolffian duct remnant (Gartner's ducts or cysts) presenting as a urethral diverticulum in two girls. *AJR* **110**: 540-545, 1970
- 5) Curry NS: Ectopic ureteral orifice masquerading as a urethral diverticulum. *AJR* **141**: 1325-1328, 1983
- 6) Wyly JB and Lebowitz RI: Refluxing urethral ectopic ureters: recognitions by the cyclic voiding cystourethrogram. *AJR* **142**: 1263-1267, 1984
- 7) Emmett JL: *Clinical Urography*, vol. 2, 4th ed. Philadelphia: Saunders, 1977, p. 700
- 8) Weiss RM and Spackman TJ: Everting ectopic ureteroceles. *J Urol* **111**: 538-540, 1974
- 9) Koyanagi T, Hisajima S, Goto T, Tokunaka S and Tsuji I: Everting ureteroceles: radiographic and endoscopic observation, and surgical management. *J Urol* **123**: 538-543, 1980
- 10) Stephens D: Cecoureterocele and concepts on the embryology and etiology of ureteroceles. *Aust NZJ Surg* **40**: 239-248, 1971
- 11) Gomez F and Stephens FD: Cecoureterocele: morphology and clinical correlations. *J Urol* **129**: 1017-1019, 1983
- 12) Ginsburg DS and Genadry R: Suburethral diverticulum in the female. *Obstet Gynecol Surv* **39**: 1-5, 1984
- 13) Schülman CC: The single ectopic ureter. *Eur Urol* **2**: 64-69, 1976
- 14) David MD and Duckett Jr JW: Single vaginal ectopic ureter: a case report. *J Urol* **120**: 493-495, 1978
- 15) Kjaeldgaard A, Fianau S, Thorgeirsson T, Ekman P: Single bifid ectopic left ureter presenting clinically as a vaginal cyst. *Diag.*

- Gynecol Obstet 3: 321-324, 1981
- 16) Sorenson CW Jr and Middleton AW Jr: The single ectopic ureter: 3 case reports. J Urol 129: 132-134, 1983
- 17) Kjaeldgaard A, Fianau S: Classification and embryological aspects of ectopic ureters communicating with Gartner's cysts. Diag Gynecol Obstet 4: 429-273, 1982
- 18) Ellerker AG: The extravescical ectopic ureter. Br J Surg 145: 344-353, 1958
- 19) Leadbetter GW Jr: Ectopic ureterocele as a cause of urinary incontinence. J Urol 103: 222-226, 1970
- 20) Ashcraft KW and Hendren WH: Bladder outlet obstruction after operation for ureterocele. J Pediat Surg 14: 819-824, 1979
- 21) Tokunaka S, Gotoh T, Koyanagi T and Tsuji I: Morphological study of the ureterocele: a possible clue to its embryogenesis as evidenced by a locally arrested myogenesis. J Urol 126: 726-729, 1981
- (Accepted for publication August 17, 1987)

和文抄録

異所性尿管瘤に伴い憩室様拡張を示した女児 wide urethra の1例

滋賀医科大学医学部泌尿器科学教室 (主任: 友吉唯夫教授)
 神波 照夫, 若林 賢彦, 竹内 秀雄, 友吉 唯夫

先天的女子尿道憩室あるいは、拡張尿道は極めて稀である。これまでに、尿管瘤に伴って、憩室様の変化を示した症例は数例報告されているが、その大多数が、尿道内に開口する拡張した尿管を誤って憩室と判定したものであり、他は、尿管瘤の poor backing のための eversion や、Gartner's cyst との交通によるものである。今回われわれは、3カ月の女児で、

特に右側尿道の著明な拡張を示し、この憩室様の拡張が尿管瘤内に翻転を示す症例を経験したので報告した。本症例は内視鏡的にも手術時の所見からも、尿管瘤は膀胱頸部以下には認められず、発生学上右側後部尿道の形成不全が関与したものと考えられた。

(泌尿紀要 34: 1437-1441, 1988)