

Title	Metastasis to the spermatic cord as the first sign of bladder carcinoma
Author(s)	Ishida, Akira; Watanabe, Jin; Takeuchi, Hideo; Konami, Teruo; Pak, Kyun; Tomoyoshi, Tadao
Citation	泌尿器科紀要 (1988), 34(7): 1269-1271
Issue Date	1988-07
URL	http://hdl.handle.net/2433/119627
Right	
Type	Departmental Bulletin Paper
Textversion	publisher

METASTASIS TO THE SPERMATIC CORD AS THE FIRST SIGN OF BLADDER CARCINOMA

Akira ISHIDA and Jin WATANABE

*From the Department of Urology, Uji-Tokushukai Hospital
(Chief: Dr. A. Ishida)*

Hideo TAKEUCHI, Teruo KONAMI, Kyun PAK and Tadao TOMOYOSHI

*From the Department of Urology, Shiga University of Medical Science
(Director: Prof. T. Tomoyoshi)*

An unusual case of a metastatic tumor of the spermatic cord, which was the first manifestation of bladder cancer, is reported.

Key words: Metastatic spermatic cord tumor, Bladder carcinoma, First sign

INTRODUCTION

Spermatic cord tumors are rather rare and primary tumors are usually sarcomas such as leiomyosarcoma, rhabdomyosarcoma, fibrosarcoma and liposarcoma¹⁾. Metastatic tumors of the spermatic cord are very rare and approximately 50 cases have been documented in the literature²⁻⁶⁾. Primary sites of these tumors are the stomach (28 cases), prostate (6 cases), kidney (5 cases), colon (5 case), pancreas (2 cases), rectum (1 case), testis (1 case), and epididymis (1 case). The bladder as the primary site of metastatic tumors to the spermatic cord is not included in the literature. An extensive review of autopsies of bladder cancer in the literature showed that the spermatic cord is not reported as the location of metastasis⁷⁾. Here, we report a case of the metastatic spermatic cord tumor which was the first manifestation of bladder carcinoma.

CASE REPORT

A 71-year-old man was admitted to our hospital with the complaint of a painless firm mass in the right inguinal region on February 27, 1984. He had noted the tumor a few months prior to admission. He had noted neither inguinal pain nor gross hematuria. Past history and family history were not contributory. Physical examination

revealed a nontender, firm, round mass with a somewhat irregular surface in the right inguinal region. The mass measured 2×3 cm, showed negative transillumination and was not fixed to the skin. Bilateral scrotal contents were normal and the digital examination of the prostate was unremarkable. Superficial lymph nodes were not swollen. Results of laboratory data including carcinoembryonic antigen and alpha-fetoprotein were within normal limits and unalysis was negative. A chest x-ray and excretory urogram were normal.

Upon the diagnosis of the spermatic cord tumor, a high inguinal orchiectomy was performed on the right side. During the operation, a whitish, hard mass was identified just below the external inguinal ring and the scrotal contents were normal. The surgical specimen weighed 40 grams and the section of the tumor showed a whitish homogeneous surface (Fig. 1). Histological examination revealed undifferentiated carcinoma (Fig. 2). Therefore, the other primary site of the tumor had to be investigated. Abdominal CT scans and ultrasonograms were normal. The patient had been complaining of frequent urination and occasional nocturnal enuresis. As urinary cytology showed class V, a cystoscopy was performed. It disclosed multiple nonpapillary tumors at the posterior wall of the bladder and the

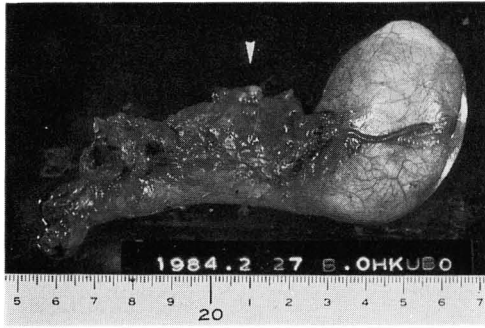


Fig. 1. Specimen obtained at right high inguinal orchietomy. Note a tumor in the cord (arrowheads).

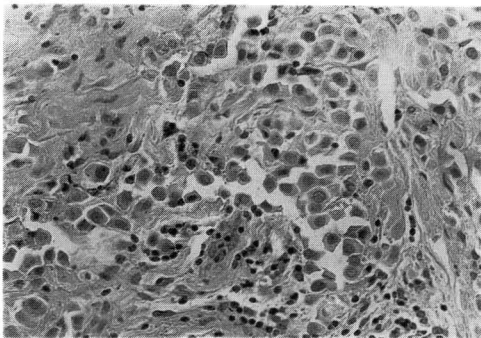


Fig. 2. Light micrograph of the spermatic cord tumor showing poorly differentiated carcinoma suspected of metastatic tumor.

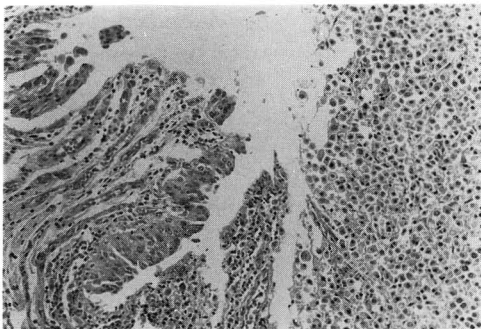


Fig. 3. Light micrograph of the bladder tumor showing transitional cell carcinoma in situ and poorly differentiated carcinoma.

capacity of the bladder was reduced to barely 150 ml. As histological examination of the biopsied specimen revealed poorly differentiated carcinoma, a subsequent total cystectomy and bilateral cutaneous ureterostomies were performed on April 12, 1984. The histopathological diagnosis was verified by Armed Forces Institute of

Pathology (AFIP, 1929783-7) as follows: (1) bladder, transitional cell carcinoma, grade II~III, in situ and poorly differentiated carcinoma, infiltrating muscle and perivesical fat, and with superficial lymphatic invasion (Fig. 3); (2) right spermatic cord, metastasis, poorly differentiated carcinoma.

Postoperative irradiation or chemotherapy was not performed because of liver dysfunction and ileus. Six months after the operation, the patient complained of a left inguinal mass, and a left high inguinal orchietomy showed metastasis of bladder cancer to the spermatic cord. He died of disseminated intravascular coagulation on February 14, 1985 and an autopsy was refused.

DISCUSSION

The usual sites of metastasis of bladder cancer are reported in order of decreasing frequency by statistical survey of 2,561 autopsy cases as follows; lymph nodes 1,110 (43.3%), lung 877 (34.2%), liver 792 (30.9%), bones 431 (16.8%), perivesical cavity 299 (11.7%), peritoneum 289 (11.3%) and adrenals 228 (8.9%)⁷⁾. No cases of metastasis to the spermatic cord are included in this analysis.

There are six possible routes of metastasis to the spermatic cord; (1) retrograde lymphatic extension, (2) retrograde venous extension or embolism, (3) arterial embolization, (4) retrograde ductal extension, (5) extension by direct peritoneal implant, (6) direct invasion from contiguous growths⁸⁻¹⁰⁾. For instance, metastasis from the stomach is supposed mainly by route (1) and (5), that from the prostate by routes (1), (2), (3) and (4), and that from the kidney by routes (1) and (2). Metastasis of bladder cancer to the intrascrotal contents is infrequent, and it is generally accepted that the route of metastasis of bladder cancer to the testis is via the prostate invaded by carcinoma. In this case, the prostate, vessels of the cord and the spermatic duct were not invaded by tumor cells. Therefore, retrograde lymphatic extension is a possible route of metastasis of bladder cancer to

the spermatic cord.

This case is unique because a mass in the spermatic cord was the first manifestation of bladder cancer. This patient did not note gross hematuria which is the most common symptom of bladder cancer, and this was the reason why diagnosis was delayed. In cases of carcinoma in situ, however, symptoms such as frequency, urgency and dysuria are the most characteristic symptoms. In this case, the patient complained only about abnormal voiding frequency with enuresis, probably due to decreased capacity.

Pathological findings were also interesting enough, that out of the two components of transitional cell carcinoma and undifferentiated carcinoma identified in the bladder, the latter metastasized to the spermatic cord. When spermatic cord tumor is histologically carcinoma, the primary site should be investigated because carcinoma of the spermatic cord is mostly metastatic.

REFERENCES

1) Blitzer PH, Dosoretz DE, Proppe KH and Shipley WV: Treatment of malignant tumors of the spermatic cord: a study of 10 cases and a review of the literature. *J Urol* **126**:

- 611, 1981
- 2) Monn L and Poticha SM: Metastatic tumors of spermatic cord. *Urology* **5**: 821 1975
 - 3) Algaba F, Santaularia JM and Villavicencio H: Metastatic tumor of the epididymis and spermatic cord. *Eur Urol* **9**: 56, 1983
 - 4) Markovic B, Opric M, Prica V, Colovic V, Mandic R and Jeremic A: Metastasis to the funiculus spermaticus as the first sign of renal cell carcinoma. *World J Surg* **7**: 669, 1983
 - 5) Ohi T, Tabayashi Y and Tuchiya A: Metastatic tumors of the spermatic cord: case report. *Jpn J Clin Urol* **24**: 631, 1970
 - 6) Nishimura K, Yoshimura N, Yamamoto S, Nakagawa T and Miyaoka T: A case of a metastatic tumor of the spermatic cord from cecal cancer. *Acta Urol Jpn* **29**: 907, 1983
 - 7) Saitoh H, Hida M, Wakabayashi T, Iida T and Satoh T: Metastasis of urothelial tumors of the bladder: correlation between sites and number of organs involved. *Tokai J Exp Clin Med* **7**: 517, 1982
 - 8) Pienkos EJ and Jablolkow VR: Secondary testicular tumors. *Cancer* **30**: 481, 1972
 - 9) Johnson DE, Jackson L and Ayala AG: Secondary carcinoma of the testis. *South Med J* **64**: 1128, 1971
 - 10) Lewis LG, Goodwin WE and Randall WS: Carcinoma of the spermatic cord and epididymis extension from primary carcinoma of the stomach. *J Urol* **51**: 75, 1944

(Accepted for publication July 20, 1987)

和文抄録

原発巣（膀胱癌）の診断に先行し発見された転移性精索腫瘍の1例

宇治徳洲会病院泌尿器科（医長：石田 章）

石田 章*, 渡辺 仁**

滋賀医科大学泌尿器科学教室（主任：友吉唯夫教授）

竹内 秀雄, 神波 照夫, 朴 勺, 友吉 唯夫

転移性精索腫瘍は稀な疾患である。今回われわれは、膀胱癌を原発とし、原発巣の診断に先行して発見され

た転移性精索腫瘍の1例を経験したので報告する。転移性精索腫瘍の原発巣としてはほとんどが消化器癌であり、膀胱癌を原発巣としたものは自験例が本邦第1例目と思われる。

*現：滋賀医科大学泌尿器科学教室

**現：郡立高島病院