

Title	Thomsen-Friedenreich antigen in bladder cancer tissues detected by monoclonal antibody
Author(s)	YOKOYAMA, Masayoshi; OHOKA, Hiroji; ODA, Hideaki; ODA, Takashi; TAKEUCHI, Masafumi; UTSUMI, Sayaka
Citation	泌尿器科紀要 (1988), 34(2): 255-258
Issue Date	1988-02
URL	http://hdl.handle.net/2433/119472
Right	
Type	Departmental Bulletin Paper
Textversion	publisher

THOMSEN-FRIEDENREICH ANTIGEN IN BLADDER CANCER TISSUES DETECTED BY MONOCLONAL ANTIBODY

Masayoshi YOKOYAMA, Hiroji OHOKA, Hideaki ODA,
Takashi ODA, Sayaka UTSUMI and Masafumi TAKEUCHI

*From the Department of Urology (Director: Prof. M. Takeuchi) and Microbiology
(Director: Prof. S. Utsumi) Ehime University School of Medicine*

Monoclonal antibodies against Thomsen-Friedenreich antigen (T-Ag) were obtained by the hydridoma technique. The expression of T-Ag in 73 specimens of bladder cancer was examined by the immunofluorescence method using these monoclonal antibodies. Seventeen (53%) of grade I, 18 (44%) of grade II and 5 (50%) of grade III were diffusely stained with anti-T. Of the T-negative tumors, 14 (44%) of grade I and 13 (32%) of grade II showed positive staining after neuraminidase treatment (cryptic T-positive) while only 1 (10%) of grade III was cryptic T-positive. On the contrary, only 1 case (3%) of grade I was cryptic T-negative while 10 (24%) of grade II and 4 (40%) of grade III (were). The T-antigen expression and the histological grades correlated significantly ($p < 0.05$). Twenty-eight (70%) of the T-positive cases and 9 (60%) of the cryptic T-negative cases recurred while only 3 (11%) of the cryptic T-positive cases did ($p < 0.01$). The monoclonal antibodies were more useful than peanut lectin (PNA) or conventional polyclonal antibodies on the detection of T-antigen.

Key words: Thomsen-Friedenreich antigen, Monoclonal antibody, Bladder cancer

INTRODUCTION

Thomsen-Friedenreich antigen (T-antigen) is composed of a non-sialated disaccharide side chain, D-galactose (beta 1-3)N-acetyl-D-galactosamine and mostly attached to serine or threonine of carrier proteins such as glycophorin of erythrocyte. Springer and collaborators first observed that the T-antigen is expressed by the majority of breast adenocarcinoma, whereas it is poorly expressed by normal tissues. Normal tissues in turn carry fully sialated oligosaccharides in which T-antigen is masked by the sialic acid residue and becomes exposed only after neuraminidase treatment (cryptic T positive-ness)¹⁻³. This has prompted subsequent investigations with carcinomas of various tissues and the evidence for the expression of T-antigen by bladder carcinoma has been accumulated as examined with peanut agglutinin as specific ligand⁴⁻⁶. We have previously observed that rabbit anti-

body, raised to desialated glycophorin A and made specific T-antigen by extensive absorption, gives more distinct immunofluorescence staining of bladder cancer tissues and is more useful for predicting the prognosis of bladder cancer than peanut lectin⁷. In the present study, we have prepared mouse monoclonal antibodies to T-antigen and re-examine our previous results with these more specific reagents.

MATERIALS AND METHODS

Glycophorin (GP) was isolated from ghosts of pooled human erythrocytes of types O, NN, by the lithium diiodosalicylate-phenol method of Marches⁸. GP was desialated by mild hydrolysis with 1N HCl at 17°C for 1 hour⁹ which removed 80% of sialic acid residues, as judged by Warren's method¹⁰. The desialated material was adsorbed on a column of PNA conjugated gel (PNA-GEL, EY Laboratories) at 20 mg protein/5 ml column. After ex-

tensive washing, the column was eluted with 0.2 M D-galactose in Tris-buffered saline (TBS) containing 0.2% Triton X-100 at pH 7.4.

Balb/c mice were immunized by one iv followed 7 days later by another iv injection each with 0.5 mg of desialated glycoporphin. Spleen cells from the immunized mice were fused with the mouse myeloma cells (SP2/0) by the standard polyethylene glycol method¹¹⁾. Three antibody-producing hybridomas were cloned by limiting dilution and their culture supernatants were used as the source of monoclonal antibodies. The reactivity of monoclonal antibodies was tested by the hemagglutination test with desialated red blood cells and enzyme-linked-immunoassay (ELISA) with PNA-column purified desialated glycoporphin⁷⁾.

Eighty-three operative specimens were obtained from patients bearing bladder tumors of various grades. These were fixed with neutral formalin and embedded in paraffin. After being deparaffinized, hydrated and washed thoroughly in PBS (pH 7.4), sections were covered with undiluted culture supernatants containing monoclonal antibodies at an IgG concentration of 0.5 mg/ml and incubated for 1 hour at room temperature. Sections were then washed extensively and incubated for another 1 hour with FITC-labeled anti-mouse IgG as the second antibody, washed 3 times with PBS, and were examined by the fluorescein microscopy.

RESULTS

None of the normal urothelial tissues examined as control were stained directly with anti-T monoclonal antibodies, but all gave positive staining for the cryptic T-antigen after the neuraminidase treatment. Forty of 83 urothelial tumors were stained positively with either of the three anti-T monoclonal antibodies tested.

Staining patterns of urothelial tumors with anti-T antibodies could be classified into three categories; (1) tumors which were directly stained with anti-T without neuraminidase pretreatment, (2) those

stained only after neuraminidase treatment (cryptic T positive) and (3) those not stained at all with anti-T, regardless of the neuraminidase treatment (Fig. 1). With most of the T-positive specimens, diffuse and uniform staining of tumor masses was observed. The positive or negative staining after neuraminidase treatment was also uniform over the whole area of any given tumor specimen.

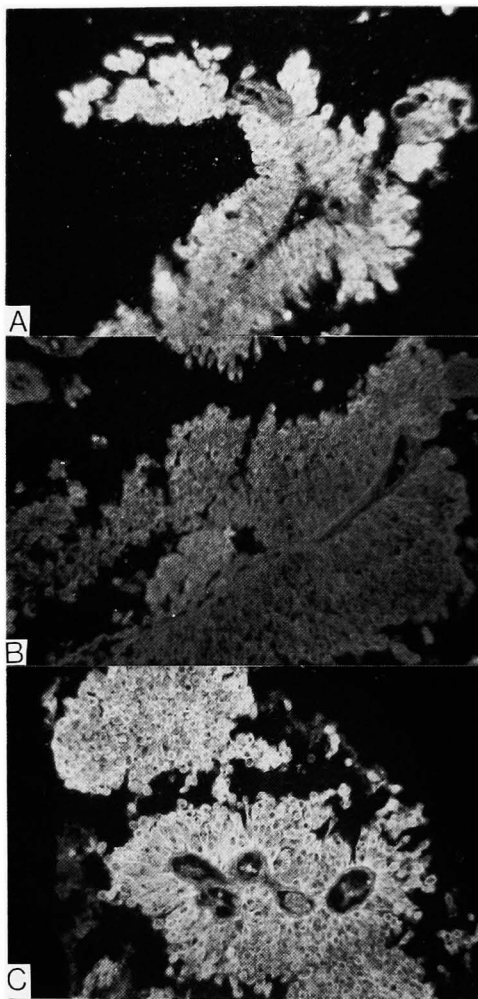


Fig. 1. A; Grade 2 transitional cell cancer tissue, which was stained with anti-T monoclonal antibody without neuraminidase treatment. B; Grade 1 transitional cell cancer tissue, which was not stained before neuraminidase treatment. C; The same case showed positive staining after neuraminidase treatment.

Such staining patterns contrasted sharply to spotty or focal staining patterns with PNA (Fig. 2). As summarized in Table 1, 17 (53%) of grade I, 18 (44%) of grade II and 5 (50%) of grade III were diffusely stained with anti-T. Of the T-negative tumors, 14 (44%) of grade I and 13 (32%) of grade II showed positive staining after neuraminidase treatment (cryptic T-positive) while only 1 (10%) of grade III was cryptic T-positive. On the contrary, only 1 case (3%) of grade I was cryptic T-negative while 10 (24%) of grade II and 4 (40%) of grade III were. The T-antigen expression and the histological grades correlated significantly ($p < 0.05$). Seventy percent of T-positive tumors and 60% of T-negative and cryptic T-positive tumors recurred, while only 3 (11%) of 28 cryptic-T positive tumors did (Table 2). No difference in the intensity or pat-

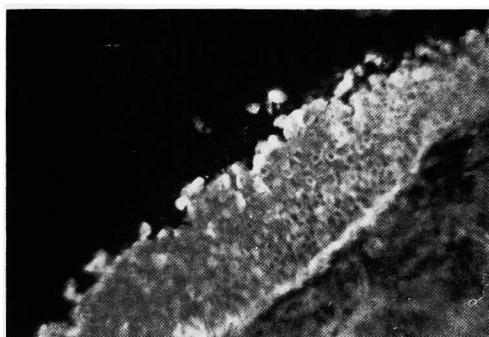


Fig. 2. Grade 1 transitional cell cancer tissue, which was stained with PNA. Note the uneven staining pattern within the tissue.

Table 1. Correlation between the grades and T-Ag expression

grade of tumor	T (+)	cry-T (-)	cry-T (+)
I	17 (53%)	1 (3%)	14 (44%)
II	18 (44%)	10 (24%)	13 (32%)
III	5 (50%)	4 (40%)	1 (10%)
total	40 (100%)	15 (100%)	28 (100%)

($p < 0.05$)

Table 2. Correlation between the tumor recurrence and T-Ag expression

	T (+)	cry-T (-)	cry-T (+)
recurrence (+)	28 (70%)	9 (60%)	3 (11%)
(-)	12 (30%)	6 (40%)	25 (89%)

($p < 0.01$)

tern of staining was observed among the three monoclonal antibodies used when they were used at the same IgG concentrations.

DISCUSSION

We have reexamined our previous observation with conventional rabbit anti-T antibody that bladder cancer patients can be classified with respect to T-antigen expression⁷⁾ now by using anti-T monoclonal antibodies. The frequency of T-antigen expression as revealed by the fluorescence antibody technique with our monoclonal antibodies correlated well to the histological grades and the clinical prognoses of the patients. The results were largely in concert with the previous observation⁷⁾. However, there were also several cases which gave discrepancies between results obtained with rabbit antibody and the present mouse monoclonal antibodies. Two cases were T-antigen positive with monoclonal but negative with polyclonal antibodies, while one case vice versa. The former cases may imply that the IgG monoclonal antibodies here had higher affinity to the T-antigen than the polyclonal antibody employed in the previous study. The affinity of antibody is crucial especially when only a small part of the sialic acid residues on the tumor cell membrane is deleted and hence bivalent binding of antibody is limited. In such a case a sufficiently high affinity of antibody will be required to survive the extensive washing during the staining procedure. Yuan *et al.* reported that their IgM monoclonal antibody, in spite of its specificity, did not give satisfactory staining avidity¹²⁾. This failure of IgM antibody may well be ascribed to the inherent low affinity and low T-antigen density on the cell membrane which will not allow IgM antibody to assume polyvalent binding.

ACKNOWLEDGMENT

This work was supported by a Grant-in-Aid for Scientific Research (No. 60570752). We thank Miss Rie Yoshimura for her

secretarial assistance.

REFERENCES

- 1) Springer GF, Desai Pr and Banatwala I: Brief Communication: Blood group MN antigens and precursors in normal and malignant human breast glandular tissue. *J Natl Cancer Inst* 54: 335-339, 1975
- 2) Springer GF, Desai PR and Banatwala I: Blood group MN specific substance in normal and malignant human breast tissues. *Naturwissenschaften* 61: 457-458, 1974
- 3) Springer GF, Desai PR, Murthy MS, Tegtmeyer H and Dcanlon EF: Human carcinoma-associated precursor antigens of the blood group MN system and the hosts's immune responses to them. *Prog, Allergy* 26: 42-96 1979
- 4) Coon JS, Weinstein RS, Summers JL: Blood group precursor T-antigen expression in human urinary bladder carcinoma. *Am J Clin Pathol* 77: 692-69, 1982
- 5) Limas C and Lange P: Altered reactivity for A,B,H antigens in transitional cell carcinomas of the urinary bladder. *Cancer* 46: 1366-1373, 1980
- 6) Summers JI, Coon Js, Ward RM, Falor WH, Miller III AW and Weinstein RS: Prognosis in carcinoma of the urinary bladder based upon tissue blood group ABH and Thomsen-tumor. *Cancer Res* 43: 934-939, 1983
- 7) Ohoka H, Shinomiya H, Yokoyama M, Ochi K, Takeuchi M and Utsumi S: Thomsen-Friedenreich antigen in bladder tumors as detected by specific antibody: A possible marker of recurrence. *Urol Res* 13: 47-50, 1985
- 8) Marchesi VT and Andrews EP: Glycoproteins: Isolation from cell membranes with lithium diiodosalicylate. *Science* 174: 1247-1248, 1971
- 9) Springer GF and Desai PR: Human blood group MN and precursor specificities: structural and biological aspects. *Carbohydr Res* 40: 183-192, 1975
- 10) Warren L: The thiobarbituric acid assay of sialic acids. *J Biol Chem* 234: 1971-1975
- 11) Fazekas DG and Scheidegger D: Production of monoclonal antibodies; Strategy and tactics. *J Immunol Meth* 35: 1-8, 1980
- 12) Yuan M, Itzkowitz SH, Boland CR, Kim YD, Tomita JT, Palekar A, Bennington JL, Trump BF and Kim YS: Comparison of T-antigen expression in normal and antibody immunohistochemistry. *Cancer Res* 46: 4841-4847, 1986

(Accepted for publication February 26, 1987)

和文抄録

膀胱腫瘍におけるモノクローナル体を用いたT抗原の検索

愛媛大学医学部泌尿器科学教室 (主任: 竹内正文教授)

横山 雅好, 大岡 啓二, 織田 英昭

小田 剛士, 竹内 正文

愛媛大学医学部細菌学教室 (主任: 内海 爽教授)

内 海 爽

ヒトのO、MN型赤血球グリコフォリンをノイラミニダーゼ処理して得たT抗原に対し、細胞融合法によりモノクローナル抗体を作製した。73例の膀胱癌組織標本においてT抗原の有無をモノクローナル抗体を作製した。73例の膀胱癌組織標本においてT抗原の有無をモノクローナル抗体による免疫蛍光組織法で検索した。悪性度が低い腫瘍では17例(53%)、中等度の腫瘍では18例(44%)、悪性度の高い腫瘍では5例(50%)においてT-陽性であり悪性度と陽性率に差を認めなかった。しかしながら、T-陰性の腫瘍のうち、ノイラミニダーゼ処理後には悪性度が低い腫瘍で14例(44%)、中等度の腫瘍で13例(32%)が陽性(cryptic T-陽性)であったのに対し、悪性度が高度の腫瘍では、わずか1例(10%)が cryptic T-陽性であった。逆

に、ノイラミダーゼ処理後にもT-陰性(cryptic T-陰性)であったのは、悪性度の低い例ではわずか1例(3%)であるのに対し、中等度悪性例では10例(24%)、高度悪性例では4例(40%)と、組織学的悪性度とT抗原の表現形式には有意の相関がみられた($p < 0.05$)。またT-陽性群では28例(70%) cryptic T-陰性群では9例(60%)で再発をみたのに対し、cryptic T-陽性例では3例(11%)でしか再発しなかった($p < 0.01$)。

モノクローナル抗体によるT抗原の検索は鋭敏で確実であり従来のピーナツレクチン(PNA)やポリクローナル抗体を用いた方法に比較し、より有用と考えられる。