

Title	A case of virilizing adrenocortical carcinoma
Author(s)	TAKIUCHI, Hidekazu; OKA, Toshitsugu; NAMIKI, Mikio; ICHIKAWA, Yasuji; SONODA, Takao; KOGA, Masahumi; SATO, Bunzo; ONISHI, Shunzo; NAKAMURA, Takayuki; MATSUSHITA, Hajime
Citation	泌尿器科紀要 (1987), 33(12): 2090-2094
Issue Date	1987-12
URL	http://hdl.handle.net/2433/119379
Right	
Type	Departmental Bulletin Paper
Textversion	publisher

A CASE OF VIRILIZING ADRENOCORTICAL CARCINOMA

Hidekazu TAKIUCHI, Toshitsugu OKA, Mikio NAMIKI,
Yasuji ICHIKAWA and Takao SONODA

From the Department of Urology, Osaka University Hospital
(Director: Prof. T. Sonoda)

Masahumi KOGA and Bunzo SATO

From the Department of Third Medicine, Osaka University Hospital
(Director: Prof. S. Kishimoto)

Shunzo ONISHI

From the Department of Pathology, Osaka College of Bio-Medical Technology
(Director: Prof. S. Onishi)

Takayuki NAKAMURA

From the Department of Urology, Osaka Seamen's Insurance Hospital
(Chief: Dr. T. Nakamura)

Hajime MATSUSHITA

From the Department of Medicine, Osaka Seamen's Insurance Hospital
(Chief: Dr. H. Matsumoto)

A 36-year-old woman who had experienced two pregnancies consulted our hospital, because of scant menses and virilization. A 24-hour excretion of 17-ketosteroids and 17-hydroxy-corticosteroids demonstrated a decrease in 11-hydroxylase. A computed tomogram showed a huge inhomogenous tumefaction in the left adren. Left selective renal angiography revealed a large adrenal tumefaction. Selective adrenal venous samplings revealed that testosterone and dehydroepiandrosterone (DHA) were produced in response to stimulation by 0.25 mg exogenous adrenocorticotrophic hormone (ACTH). After left adrenalectomy was performed, a diagnosis of adrenocortical carcinoma was made by pathological examination. This is the first report of a patient with a virilizing adrenocortical carcinoma, which produced testosterone and DHA in response to exogenous ACTH stimulation.

Key words: Virilizing adrenocortical carcinoma, Virilization, Adrenocortical carcinoma

INTRODUCTION

Adrenocortical carcinoma is a rare malignant disease. According to the Third National Survey in USA, its incidence is approximately one case per 1,700,000 population, and accounts for 0.02% of all cancers. The same incidence is found in Japan. The tumor may be described as either "functioning" depending on clinical syndrome produced, or "non-functioning"

when there is no clinical evidence of hormonal excess. Non-functioning tumors and functioning tumors are equal in incidence.

Here we present a case of the virilizing adrenocortical carcinoma which produced testosterone and DHA in response to ACTH stimulation.

CASE REPORT

A 36-year-old woman who had experi-

enced two pregnancies had the complaint of scant menses since October, 1982. In August, 1983 she consulted the Department of Gynecology of Osaka University School of Medicine and the 17-ketosteroids were noted to be increased. The following month she complained of left vague epigastralgia, and double contrast examination of the stomach was performed by a physician. The stomach was extrinsically deviated anteriorly. Thus the patient was introduced to our hospital for detailed examination.

She was 150 cm in height and weighed 54 kg on admission. She had experienced a weight-loss of 4 kg during the last two months. Her body temperature was 36.6°C, pulse was 84 and blood pressure was 177/78. Masculine facial hair distribution was

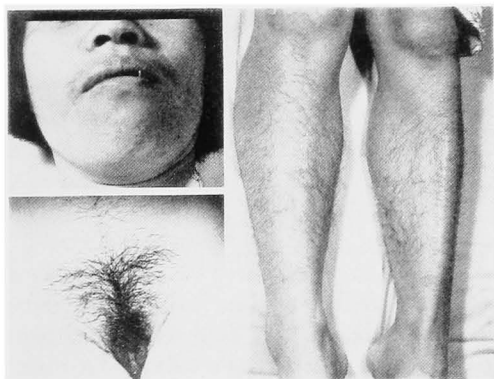


Fig. 1. Distribution of masculine facial hair is present as well as increased hair of dark, coarse character on legs and pubic area.

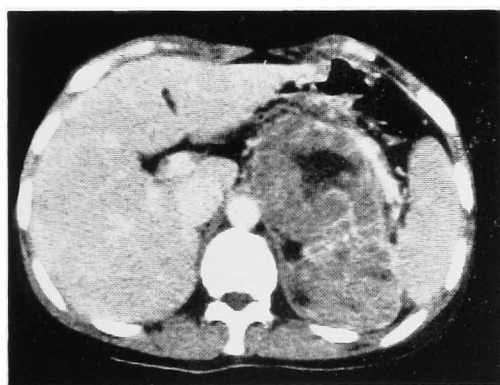


Fig. 2. A computed tomograph shows a huge inhomogenous tumefaction on the left side of abdomen.

present and increase was seen in hair of a dark, coarse character on the arms, legs and pubic area (Fig. 1). In addition, there were no striae, ecchymosis or abdominal fat deposits. Abdominal examination revealed a hard, immobile, nontender mass deep in the left upper quadrant near the midline. The serum electrolytes and urinalysis were normal. The 24-hour urinary excretion of 17-ketosteroids and 17-hydroxycorticosteroids demonstrated a decrease in 11β -hydroxylated products and an increase in the substrates of 11β -hydroxylase (Table 1). Selective adrenal venous samplings revealed that testosterone and DHA were produced in response to stimulation by 0.25 mg exogenous ACTH (Table 2). A drip infusion pyelogram demonstrated that the orientation of the left kidney was abnormally vertical and that the left kidney was displaced inferiorly. A computed tomogram showed a huge inhomogenous tumefaction on the left side (Fig. 2). Left selective renal angiography revealed a large adrenal tumefaction. On October 12, 1983, the patient underwent left adrenalectomy. After the operation, testosterone, DHA and urinary 17-ketosteroids excretion decreased to normal ranges. The pathologic study revealed a $5 \times 12 \times 24$ cm encapsulated tumor, 720 g in weight. The cut surface of the tumor showed small and dispersed hemorrhage and necrosis. Histologically, the presence of large pleomorphic cells with irregular nuclear chromatin distri-

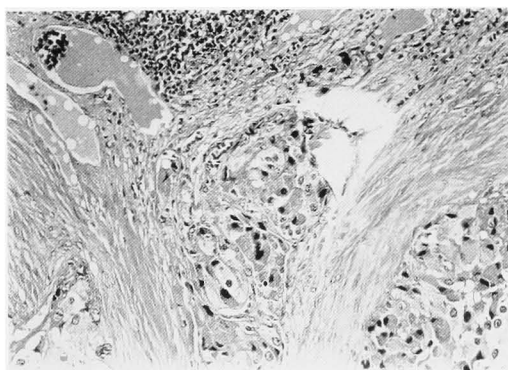


Fig. 3. Large pleomorphic cells are noted, and they show invasive growth into blood vessel walls and tumor's capsule.

Table 1. Endocrinological data of this case. Values in parentheses demonstrate normal ranges in our laboratory.

Urinary 17-OHCS	3.4	6.0 mg/day (2.5	6.4)
Urinary 17-KS	12.0	21.9 mg/day (3.0	8.0)
Urinary 17-KS fractionation			
Androsterone	6.27 mg/day (0.2	2.8)	
Etiocholanolone	4.60 mg/day (0.2	3.0)	
Dehydroepiandrosterone	13.00 mg/day (< 1.5)		
11-OH-Androsterone	0.04 mg/day (0.05	1.0)	
11-OH-Etiocholanolone	0.60 mg/day (< 1.5)		
11-OH-Ketoetiocholanolone	0.02 mg/day (0.05	1.0)	
Cortisol daily profile	normal pattern		
Dexamethasone suppression test			
Urinary 17-OHCS is suppressed			
Urinary 17-KS is not suppressed			
Steroid content of peripheral vein			
Pregnenolone	0.226 ng/ml (0.2	15.0)	
17-OH-Pregnenolone	4.54 ng/ml (0.1	4.0)	
DOC	0.269 ng/ml (0.02-	0.2)	
11-Deoxycortisol	8.23 ng/ml (0.2	1.2)	
Corticosterone	0.956 ng/ml (1.0	10.0)	
Aldosterone	8.7 ng/ml (2.0	4.0)	

Table 2. Steroid content of venous sampling as below. Values in parentheses demonstrate normal ranges in our laboratory.

Portion of sampling	Cortisol		Testosterone		DHA	
	(4.5	24 µg/dl)	(0.2	0.5 mg/dl)	(1.27	7.4 ng/ml)
1	3.3		1.7			
2	3.2		1.7		2.7	
3	4.3		3.5			
4	5.0		3.7		8.2	
Exogenous ACTH 0.25 mg I.v. stimulation (15 min. later)						
4	21.0		6.1		29	
1. Inferior vena cava at the level of the twelfth vertebra, that is proximal to left renal vein.						
2. Inferior vena cava at the connection of both common iliac veins						
3. Left renal vein						
4. Left adrenal vein						

bution was noted, and there was invasion into the blood vessel walls and tumor capsule (Fig. 3). The diagnosis of left adreno-cortical carcinoma was established. Two courses of combination chemotherapy

of adriamycin, cisplatinum, cyclophosphamide and 5-FU were carried out, followed by administration of o, p-DDD. Because the patient experienced vilirization as evidenced by increase in pubic hair at 6

months after the operation, a detailed search was made for metastasis. Computed tomography showed a 2 cm tumefaction in diameter near the pancreatic head, and serum testosterone had elevated to 1.3 ng/ml, while the values of serum DHA and androstenedione were still within normal limits. Countermeasures to prevent metastasis are still not clear among our urologist and physicians.

DISCUSSION

Adrenocortical neoplasms that produce glucocorticoids and/or 17-ketosteroids are active in hormone production in the absence of ACTH, which is in contrast to the ACTH dependence of normal adrenals. Also, the growth of these tumors is not dependent on the presence of ACTH. Although ACTH is the only hormonal preparation that stimulates normal adrenal adenylate cyclase, adenylate cyclase of adrenocortical tumor can be stimulated by epinephrine, norepinephrine, thyroid-stimulating hormone (TSH), luteinizing hormone (LH) and follicle-stimulating hormone (FSH), as well as ACTH¹⁾

There are some reports on this type of tumor defined as virilizing adrenocortical tumor, in one of which a virilizing adrenocortical adenoma is described which produced testosterone in response to exogenous human chorionic gonadotropin (HCG)²⁾. There is another report of a

patient whose adrenal carcinoma cells produced DHA in vitro by ACTH stimulation³⁾. In our case, testosterone and DHA were produced via adrenal vein in response to exogenous ACTH stimulation. An increase was seen in cortisol as well, and it appears that it was produced in the contralateral normal adrenal gland. This is thus the first report of an ACTH-responsive virilizing adrenocortical carcinoma.

As to the therapeutic method, only surgical resection of the tumor is effective; administration of adjuvant chemotherapy and o,p-DDD was in vain. Thereafter, a recurrence was suspected. Further studies to develop an effective therapy should be made.

REFERENCES

- 1) Schorr I, Rathnam P, Sarina BB and Ney RL: Multiple specific hormone receptors in the adenylate cyclase of an adrenocortical carcinoma. *J Biol Chem* 246: 5806~5817, 1971
 - 2) Miginley JI, Young IS, Pluang T, Dreyfus JC, Reckler JM and Peterson RE: Testosterone secreting adrenal cortical adenomas. *Int J Gynecol Obstet* 19: 421-428, 1981
 - 3) Cahan LA, Villee DB, Powers ML and Crigler JF: A virilizing adrenocortical tumor in a female infant: in vivo and a vitro biochemical characteristics. *J Clin Endocrinol Metab* 47: 300~306, 1978
- (Accepted for publication December 1, 1986)

和文抄録

男性化副腎皮質癌の1例

大阪大学医学部泌尿器科学教室（主任：園田孝夫教授）

滝内 秀和・岡 聖次・並木 幹夫
市川 靖二・園田 孝夫

大阪大学医学部第3内科学教室（主任：岸本 進教授）

古賀 正史・佐藤 文三

大阪大学医療技術短期大学病態病理学教室（主任：大西俊造教授）

大西 俊造

大阪船員保険病院泌尿器科（部長：中村隆幸）

中村 隆幸

大阪船員保険病院内科（部長：松下 肇）

松下 肇

症例は稀発月経と男性化を主訴とする36歳の経産婦で、17 KS, 17 OHCS の24時間尿中排泄で、11 β -ヒドロキシラーゼの基質物質の増加と産生物の減少を認めた。CT で左側の副腎腫瘍が疑われ、腎動脈造影で巨大な左副腎腫瘍と診断した。この際施行した静

脈サンプリングで testosterone および DHA が外因性の 0.25 mg ACTH 負荷に反応した。摘出標本の病理検査の結果、副腎皮質癌と診断した。外因性 ACTH に反応する男性化副腎皮質癌としては、われわれの症例が第1例目と考えられる。