

Title	Carcinosarcoma of the bladder diverticulum: a case report and review of literature
Author(s)	KOIZUMI, Hisashi; KUMAKI, Osamu; NAGANO, Kenichi; KOSAKA, Satoshi
Citation	泌尿器科紀要 (1987), 33(9): 1447-1449
Issue Date	1987-09
URL	http://hdl.handle.net/2433/119266
Right	
Type	Departmental Bulletin Paper
Textversion	publisher

CARCINOSARCOMA OF THE BLADDER DIVERTICULUM: A CASE REPORT AND REVIEW OF LITERATURE

Hisashi KOIZUMI, Osamu KUMAKI, Kenichi NAGANO and Satoshi KOSAKA

From the Department of Urology, Maizuru Kyosai Hospital

(Chief: Dr. S. Kosaka)

A 56-year-old man with carcinosarcoma of the bladder diverticulum is reported. Histologically, the tumor contained two elements: carcinomatous and sarcomatous components with a transitional phase between them. The related literature is also reviewed.

Key words: Carcinosarcoma, Bladder diverticulum

CASE REPORT

A 56-year-old man first consulted us for urological evaluation in January, 1983 after an episode of gross, painful hematuria. An excretory pyelogram showed left double pelvis and ureter as well as a small calcification at the lower end of the ureter. Cystoscopy revealed a diverticulum orifice surrounded by a smooth mucosa above the left ureteral orifice. A pelvic CT scan showed filling defect of the diverticulum. A chest X-ray exhibited a round mass in the right lower lobe. The laboratory data were within normal limits except for elevations of erythrocyte sedimentation rate and α_2 -globulin. Urine cytology was class V, and urine bacterial culture revealed *Ac. xylosoxidans*.

Segmental cystectomy was performed along with removal of the regional lymph nodes. The specimen contained a large polypoid tumor in the diverticulum and elevated flat tumors around it. The surface area and the central base of the polypoid tumor were composed chiefly of carcinomatous and sarcomatous components, respectively, with a region of gradual transition in the middle. In the carcinomatous component, highly heterogeneous cells including giant cells with bizarre giant nuclei formed squamoid patterns, and eosinophilic bodies were

scattered intra- and intercellularly. The sarcomatous components consisted of osteosarcomatous and chondrosarcomatous portions, and small areas of spindle cell sarcoma. From these observations, a diagnosis of carcinosarcoma was made. No metastases were detected in the lymph nodes surrounding the bladder. The elevated flat tumors were grade 1 or 2 transitional cell carcinomas.

The patient was treated postoperatively by chemotherapy, consisting of mitomycin C and Futrafal, but the round mass in the right lower lobe enlarged, and the patient died 2 months later due to acute cardiac failure. Autopsy was not performed.

DISCUSSION

Although there has been controversy over the definitions and concepts of carcinosarcoma, the currently most widely accepted, classification¹⁾ is that of Meyer¹⁾ who, categorized the tumor into the following three types, 1) collision tumors in which a carcinoma and sarcoma arise in contiguity and invade one another, 2) combination tumors in which carcinomatous and sarcomatous elements of the tumor arise from a totipotential cell, and 3) composition tumors in which both neoplastic elements arise simultaneously in the same tissue. Most of the carcinosarco-

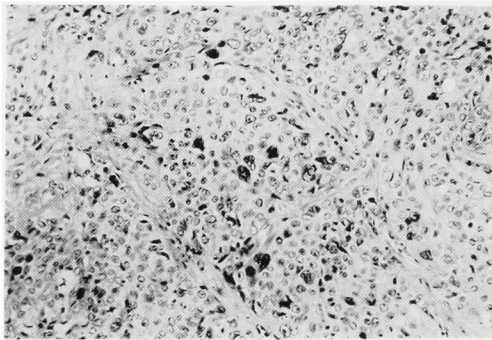


Fig. 1. Carcinomatous component ($\times 50$).

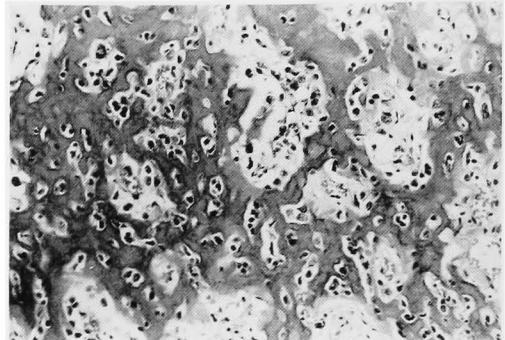


Fig. 2. Sarcomatous component ($\times 50$) (osteosarcoma).

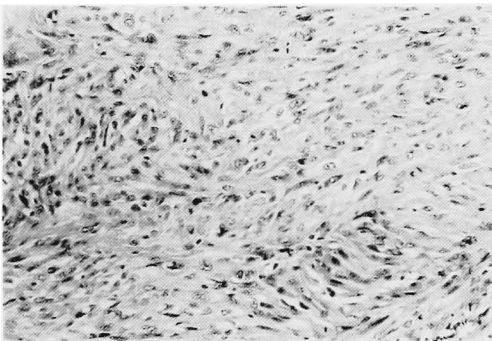


Fig. 3. Spindle cell sarcoma ($\times 50$).

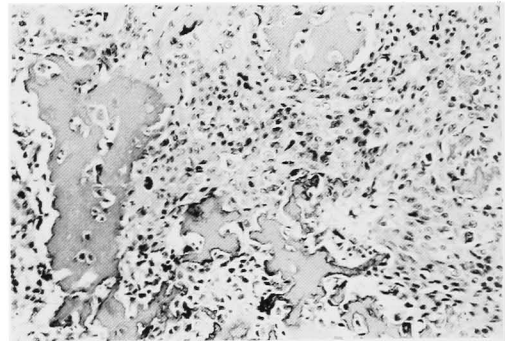


Fig. 4. Combination of carcinomatous component and sarcomatous component ($\times 50$).

mas reported in the literature are collision or composition tumors, and the present case is the second only to the one combination tumor described by Uyama et al.²⁾ Histologically, while the sarcomatous component of collision tumors, frequently originating in the bladder wall, are mostly myosarcomas, those of combination and composition tumors may be of various types including osteosarcoma and chondrosarcoma.

Over 30 cases of carcinosarcoma have been described to date since the first report by Gabe³⁾ in 1932. The tumor has been found in patients between the ages of 36 and 82 years, and 4~5 times more frequently in men than in women. The primary symptom is mostly gross hematuria, often accompanied by dysuria or pollakiuria. The sites of the most frequent occurrence are the trigone and the lateral walls; the present tumor seems to be the first to be detected in the diverticulum. Preoperative diagnosis of carcinosarcoma is extremely difficult, and in most cases,

histological examination, such as by transurethral resection, is necessary. Once the diagnosis is made, segmental or radical cystectomy is the conventional therapeutic course. A number of reports recommended radical cystectomy in view of the rapid advance of the disease. Prognosis is extremely poor: irradiation or chemotherapy performed in some cases as postoperative adjuvant therapy was practically ineffective. Most of the patients die within one year of surgery, the longest survival being 5 years. Local recurrence, or sepsis is a common cause of death. Metastases to lymph nodes and chest have also been reported. Interestingly, Smith et al.⁴⁾ presented 2 metastatic lesions in lymph nodes, one composed only of sarcomatous and the other only of carcinomatous elements. The thoracic lesion in our patient, probably metastatic, enlarged and was unaffected by chemotherapy. Its histological nature, however, was not identified.

As for causative factors of carcinosarcoma, Berdjis⁵⁾ proposed irradiation, and Uyama et al.²⁾ suggested chemotherapy, based on their observation that the tumor was found in rats in which carcinogenesis was induced with N-butyl-N-(4-hydroxybutyl) nitrosamine. To our knowledge, no such factors were involved in our patient.

REFERENCES

- 1) Meyer R: Beitrag zur Verständigung über die Namengebung in der Geschwulstlehre. Zbl Allg Path **30**: 291~296, 1920
- 2) Uyama T and Moriwaki S: Carcinosarcoma of urinary bladder. Urology **18**: 191~194, 1981
- 3) Gabe J: A case of sarco-carcinoma of the urinary bladder. Brit J Urol **4**: 145~155, 1932
- 4) Smith JA, Herr HW and Middleton RG: Bladder carcinosarcoma: Histologic variation in metastatic lesions J Urol **129**: 829~831, 1983
- 5) Berdjis CC: Pathology of irradiation. Baltimore: The Williams & Wilkins Co., 1971

(Accepted for publication September 1, 1986)

和文抄録

膀胱憩室に発生したカルチノザルコーマの1例

舞鶴共済病院泌尿器科 (部長: 小坂哲志)

小泉 久志・熊木 修・長野 賢一・小坂 哲志

症例は56歳男性で排尿痛および肉眼的血尿を主訴として来科した。KUB・DIP, 膀胱鏡にて左尿管口後方に憩室および同部のペルベット状変化が認められ

た。膀胱部分切除術施行, 組織学的にカルチノマトスな部分とサルコマトスな部分があり, 両者は相互に移行しておりカルチノザルコーマと診断された。