

Title	A case of penile tumor: combination of leiomyosarcoma and squamous cell carcinoma
Author(s)	KOIZUMI, Hisashi; NAGANO, Kenichi; KOSAKA, Satoshi
Citation	泌尿器科紀要 (1987), 33(9): 1489-1491
Issue Date	1987-09
URL	http://hdl.handle.net/2433/119257
Right	
Type	Departmental Bulletin Paper
Textversion	publisher

A CASE OF PENILE TUMOR: COMBINATION OF LEIOMYOSARCOMA AND SQUAMOUS CELL CARCINOMA

Hisashi KOIZUMI, Kenichi NAGANO and Satoshi KOSAKA

From the Department of Urology, Maizuru Kyosai Hospital

(Chief: Dr. S. Kosaka)

Leiomyosarcoma of the penis is a very rare malignant tumor. We describe a patient with a combination of leiomyosarcoma and squamous cell carcinoma, apparently the first case in the world, and review previous cases of leiomyosarcoma.

Key words Penile tumor, Leiomyosarcoma, Squamous cell carcinoma

CASE REPORT

A 53-year-old man visited our hospital with the chief complaints of penile pain. Local examination revealed an irregular map-like tumor arising from the glans (-dorsal, left side) sulcus and prepuce. Behind it, another polyp-like tumor arose. The biopsy of the tumor suggested sarcoma.

On May 18, 1983, partial penectomy and pelvic lymph node excision were performed. Histologically, the map-like tumor was found to be well differentiated squamous cell carcinoma (SCC) with keratosis, partially in situ, and partially invading the corpus situ, and partially invading the corpus cavernosum. The polyp-like tumor contained spindle cells with semi-spindle shaped nuclei and eosinophilic cytoplasm proliferating in a bundle pattern; this was diagnosed as leiomyosarcoma. These tumors were well demarcated from each other by fibrous tissue.

No lymph node involvement was found and surgical margin was intact. Post-operatively, peplomycin was administered and there has been no evidence of local recurrence or distant metastasis after one year.

DISCUSSION

Malignant tumors of the penis comprised

1~3% of all male malignant tumors, and most of them are SCC. The majority of the patients ranged in age from 40~60 years old and about half of the tumors occurred in the glans and sulcus, followed in order of frequency by the prepuce. Metastases were generally lymphogenic especially inguinal nodes, and radiation and bleomycin were found to be effective. Though this disorder is treated as conservatively as possible, lymph node excision was performed in cases of lymph node involvement¹⁾.

On the other hand, leiomyosarcoma of the penis is a very rare tumor. In 1930, Levi reported the first case, and since then less than 25 cases have been reported.

McKenzie Pratt and Ross²⁾ separated these tumors into 2 groups. The first group is those arising from the smooth muscle of the superficial tissues of the shaft of the penis. These are of low malignancy, show little tendency to invade deeper structures, are painless and are not accompanied by urinary symptoms. They tend to recur after local excision. The second group arises from the smooth muscle of the corpora. They are situated deeply at the root of the penis in close proximity to the urethra, show local invasion, especially to the corpora, and cause urinary symptoms due to compression of urethra.

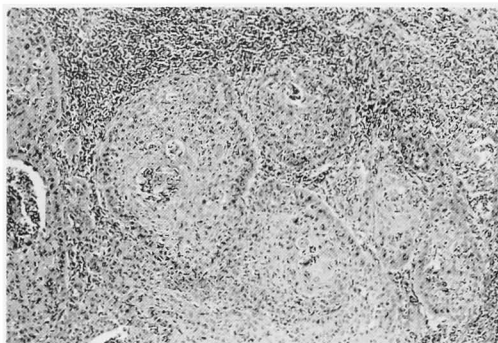


Fig. 1. Squamous cell carcinoma ($\times 25$).

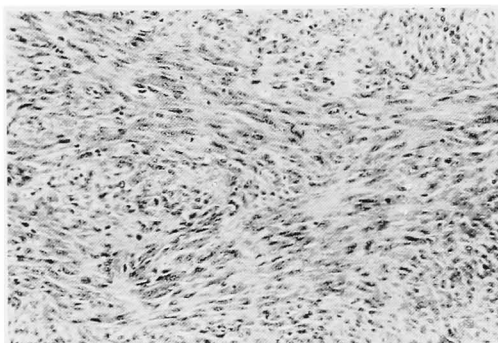


Fig. 2. Leiomyosarcoma ($\times 50$).

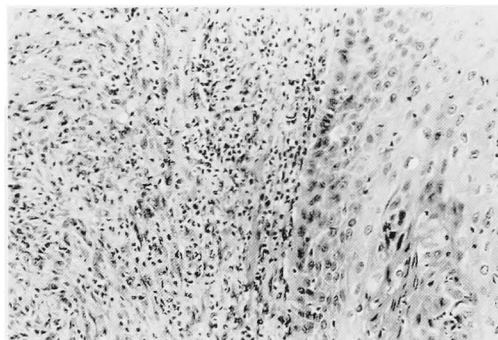


Fig. 3. Squamous cell carcinoma and leiomyosarcoma well-bordered by fibrous tissue. ($\times 50$).

Greenwood³⁾ suggested that these two groups require different therapeutic approaches. Radiotherapy has proven to be of no value in these cases and the primary

treatment must be surgical. Even for the superficially situated tumors, surgery of choice was radical excision, and for the deeply seated tumors, amputation of the penis.

The 22 patients reported to date including our case, were between 6 and 84 years old, but the majority were in their fifties (5 cases) or sixties (7 cases). The shaft, usually on the dorsum was the most commonly involved site (10 cases), followed by the glans (7 cases), root of the penis (3 cases) and prepuce (2 cases). Interestingly, the site of leiomyosarcoma differs from that of SCC.

Of the five patients who died, the tumor was situated in the shaft in 3 cases, and in the glans and root of the penis in 1 case. Radiation and chemotherapy were of no value, and the first choice of treatment was operation. Total penectomy was performed in 11 of the 22 cases, local excision in 7 cases, and partial penectomy in 4 cases. In our case, partial penectomy was performed to permit orthostatic urination.

Metastases were usually blood-borne and lung, bone metastases were reported⁴⁾. On the other hand, lymphatic dissemination occurred occasionally with inguinal node involvement in 3 cases.

REFERENCES

- 1) Kitagawa R: Penile cancer. *Cancer Chemother* 5: 519~524, 1978
- 2) McKenzie Pratt R and Ross RTA: Leiomyosarcoma of the penis. *Br J Surg* 56: 870~872, 1969
- 3) Greenwood N, Fox H and Edwards EC: Leiomyosarcoma of the penis. *Cancer* 29: 481~483, 1972
- 4) Hamal PB: Leiomyosarcoma of penis—Case report and review of the literature. *Br J Urol* 47: 319~324, 1975

(Accepted for publication September 1, 1986)

和文抄録

陰茎腫瘍の1例：平滑筋肉腫と扁平上皮癌の合併例

舞鶴共済病院泌尿器科（部長：小坂哲志）

小泉 久志・長野 賢一 小坂 哲志

症例は53歳男性で陰茎痛を主訴として来科した。肉眼的には亀頭背面左側を中心とした地図形形状の腫瘍とその後方に存在するポリープ状の腫瘍が認められた。陰茎部分切断術および骨盤腔内リンパ節廓清術を

施行、組織標本では地図形形状の部分は扁平上皮癌で、ポリープ状の部分は平滑筋肉腫で両者の移行型を示す細胞は認められなかった。術後ペブレオマイシンの投与を行ない現在にいたる。