

Title	A study of cryptorchidism. III: The histochemistry of complex carbohydrates in the testes of cryptorchid patients
Author(s)	GOTOH, Momokazu; MIYAKE, Koji; MITSUYA, Hideo
Citation	泌尿器科紀要 (1987), 33(6): 905-914
Issue Date	1987-06
URL	http://hdl.handle.net/2433/119163
Right	
Type	Departmental Bulletin Paper
Textversion	publisher

A STUDY ON CRYPTORCHIDISM

III: THE HISTOCHEMISTRY OF COMPLEX CARBOHYDRATES IN THE TESTES OF CRYPTORCHID PATIENTS

Momokazu GOTOH, Koji MIYAKE and Hideo MITSUYA

From the Department of Urology, Nagoya University School of Medicine

(Director: Prof. H. Mitsuya)

The complex carbohydrates in the undescended and contralateral scrotal testes of patients with cryptorchidism, were examined by light microscopic histochemical methods, in comparison with those of normal testes. In the undescended testes, histochemical reactions for acidic and neutral complex carbohydrates were apparently weaker than in the normal testes, especially pronounced in the seminiferous tubular walls. In the germinal and supporting cells of the undescended testes, the amount of galactose residues in the complex carbohydrates decreased from the prepubertal to post-pubertal periods. Periodic acid-Schiff reaction also revealed a decrease in the glycogen content in the germinal and supporting cells of the undescended testes from pre-pubertal to post-pubertal periods.

Key words: Cryptorchidism, Testis, Complex carbohydrates, Histochemistry

INTRODUCTION

Cryptorchidism is a common anomaly among endocrine glands¹⁾. Sterility is frequently associated with cases of cryptorchidism; 60 to 85% of all unilateral cryptorchids and 90 to 100% of all bilateral cryptorchids have been reported to be subfertile or sterile²⁾. The precise pathogenesis of impaired spermatogenesis in such testes, however, has not been elucidated. In previous light and electron microscopic studies on the testes of cryptorchid patients, morphological changes of the seminiferous epithelium have been precisely described, and additional recent morphological studies on the subepithelial connective tissue layers and the interstitial tissue components have proved that the pathological changes in such components also may be related to the impaired testicular functions³⁾. However, little information is available as to the histochemical changes occurring in the testes of cryptorchid patients. In the testes of patients with idiopathic male infertility, a series of histochemical changes have been noted; increase and decrease in amounts of periodic acid-Schiff (PAS) reactive

glycogen within the cytoplasm of Sertoli cells at respective stages of hypoplasia and atrophy⁴⁾, increase in thickness of the seminiferous tubular walls which contain both mucopolysaccharides and testicular hyaluronidase resistant glycoproteins^{5,6)}, and galactose deficiency in such testes⁷⁾. These findings strongly suggest that complex carbohydrates are important substances which might be related to testicular dysfunction. In the cryptorchid testes, however, few histochemical studies of the undescended testes have been reported. In his histochemical study on cryptorchid testes Mancini (1964)⁸⁾ found no apparent difference between undescended testes and normal testes. Herein, we examined the complex carbohydrates histochemically by means of currently available methods of light microscopy.

MATERIALS AND METHODS

Specimens were obtained by biopsy^{9,10)}, from 23 undescended testes of 23 cryptorchid patients between 3 and 37 years old (12 pre-pubertal, 3 pubertal and 8 post-pubertal), and from 7 contralateral scrotal testes, and were immediately fixed in 1% cetylpyridium chloride (CPC) in

Carnoy's fluid for 2 hours at room temperature. As normal controls, biopsy specimens were obtained from the testes of 6 healthy fertile men at vasectomy (26 to 59 years old). After fixation, all the tissue specimens were dehydrated in an ethanol series and embedded in paraffin. Sections were cut at 4 μ m in thickness, deparaffinized in xylene, hydrated through an ethanol series and then stained by means of hematoxylin-eosin for general observation and by the following histochemical methods for demonstration of complex carbohydrates. (1) Alcian blue (AB) (pH 1.0)¹¹⁾, (2) AB (pH 2.5)¹²⁾, (3) aldehyde fucin (AF), (4) periodic acid-Schiff (PAS), (5) Concanavalin A-peroxidase-diaminobenzidine (ConA-PO-DAB)¹³⁾, and (6) peroxidase-labeled Ricinus communis agglutinin-diaminobenzidine (PO-RCA-DAB)¹⁵⁾. For identifying individual acidic and neutral carbohydrates, the following procedures of enzyme digestion were performed upon some tissue sections prior to histochemical stains; (a) sialidase (neuraminidase) (Boehringer GmbH, West Germany) prior to staining with AB (pH 2.5)¹⁶⁾, (b) Streptomyces hyaluronidase (Amano Pharmaceut Co. Ltd., Japan) prior to staining with AB (pH 2.5)¹⁷⁾, (c) testicular hyaluronidase (Seikagaku Chem. Indust. Co. Ltd., Japan) prior to staining with AB (pH 1.0) or AB (pH 2.5) or AF¹⁸⁾, (d) chondroitinase ABC (Seikagaku Chem. Indust. Co. Ltd., Japan) prior to

staining with AB (pH 1.0) or AB (pH 2.5) or AF^{19,20)}, (e) chondroitinase AC (Seikagaku Chem. Indust. Co. Ltd., Japan) prior to staining with AB (pH 1.0) or AB (pH 2.5) or AF^{19,20)} and (f) alpha-amylase (Wako Pure Chem. Indust. Co. Ltd., Japan) prior to staining with PAS¹⁹⁾.

RESULTS

In normal individuals, the testis parenchyma consisted of seminiferous tubules of uniform diameter with thin tubular walls and interstitial tissues surrounding the tubules (Fig. 1). In the undescended testes of the pre-pubertal patients, seminiferous tubules were still small in diameter containing immature spermatogonias and Sertoli cells. Thickening of the seminiferous tubular walls was not evident at this period, and intertubular interstitial spaces did not show any increase in extent. In the undescended testes of the pubertal patients, thickening of the tubular walls and expansion of the intertubular spaces had begun. After puberty, in the undescended testes, thickening of the tubular walls was marked and intertubular spaces were increased (Fig. 2). In the undescended testes of the pubertal and post-pubertal patients, the activity of spermatogenesis was highly impaired, and the seminiferous tubules were still rather small in diameter and contained Sertoli cells and a small number of spermatogonias, or only Sertoli cells; Johnsen's score was 2 or 3 (Fig. 2).

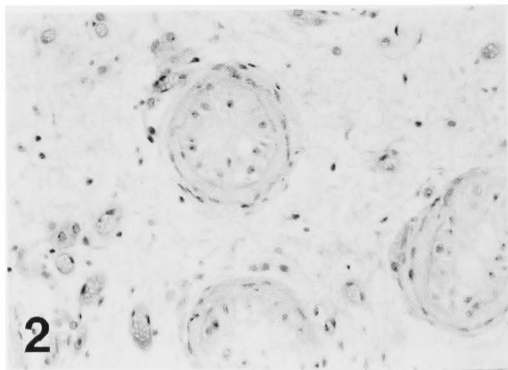
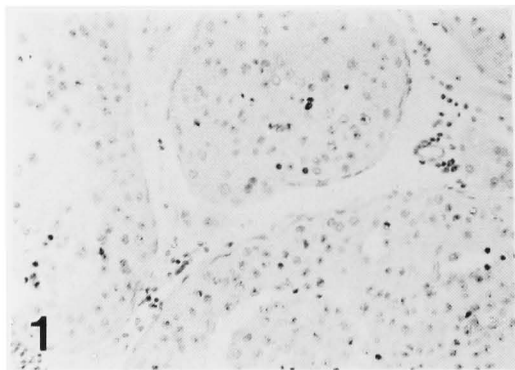
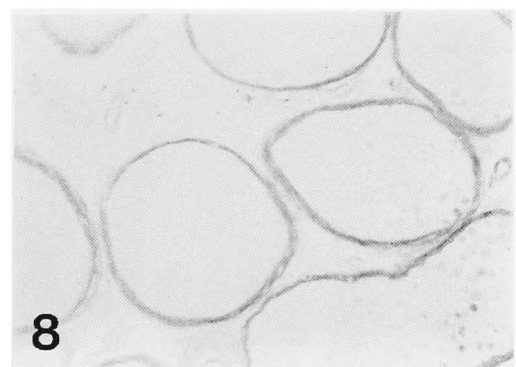
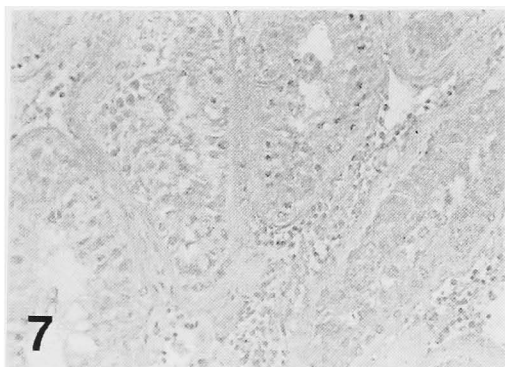

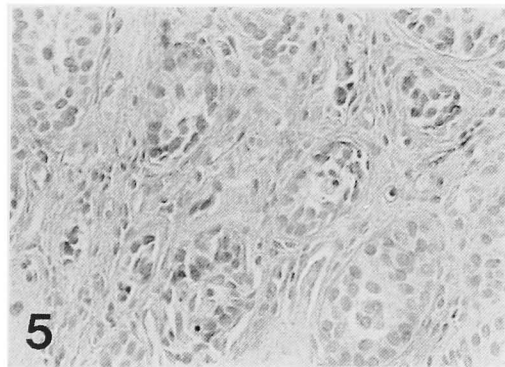
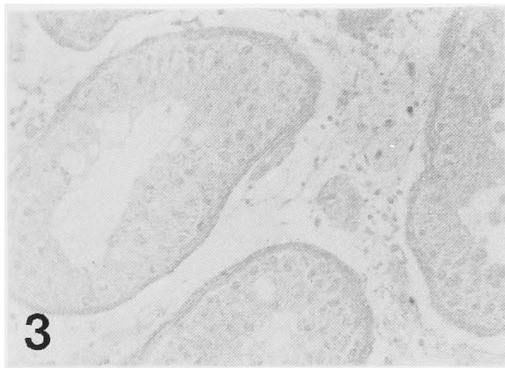
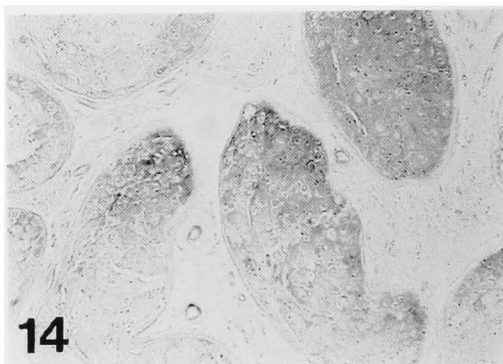
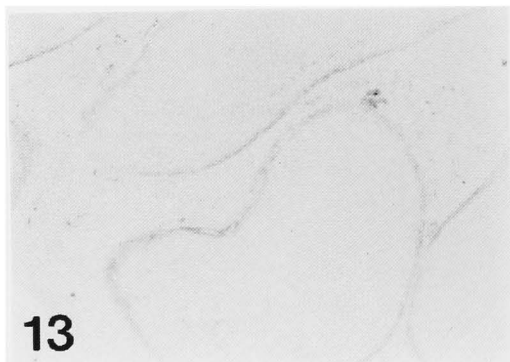
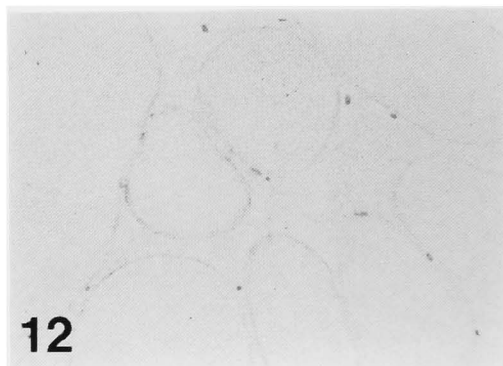
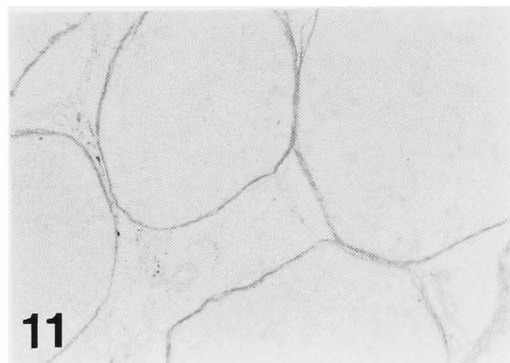


Fig. 1. The testis of a normal fertile adult stained with hematoxylin-eosin.

Fig. 2. The undescended testis of a post-pubertal cryptorchid patient (26 years old) stained with hematoxylin-eosin. Seminiferous tubules are reduced in diameter, and surrounded by thick tubular walls and abundant interstitium.



- Fig. 3. The testis of a normal fertile adult stained with AB (pH 2.5). Seminiferous tubular walls and interstitium show alcianophilia of appreciable intensity.
- Fig. 4. The undescended testis of a post-pubertal cryptorchid patient (21 years old) stained with AB (pH 2.5). The alcianophilia of seminiferous tubular walls and interstitium is apparently weaker in intensity than in those of control individuals.
- Fig. 5. The undescended testis of a pre-pubertal patient (5 years old) stained with AB (pH 2.5). The alcianophilia of seminiferous tubular walls is markedly weaker, while that of the interstitium is stronger than those in the testes of post-pubertal patients.
- Fig. 6. The testis of a normal fertile adult stained with AB (pH 2.5) following digestion with chondroitinase ABC. The enzyme digestion markedly weakened the AB (pH 2.5) reaction in all of the histologic components of the testis.
- Fig. 7. The testis of a normal fertile adult stained with AB (pH 2.5) following digestion with chondroitinase AC. The enzyme digestion lead to a slight decrease in intensity of AB (pH 2.5) reaction.
- Fig. 8. The testis of a normal fertile adult stained with AF. Seminiferous tubular walls exhibit a strong AF reaction.

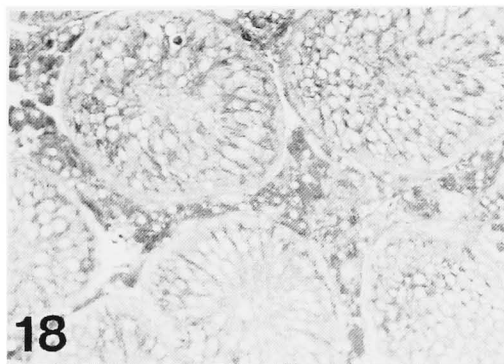

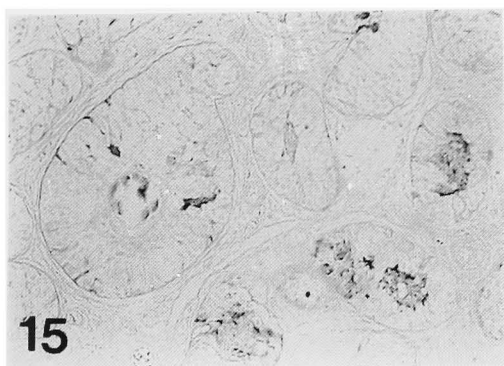


- Fig. 9. The undescended testis of a post-pubertal cryptorchid patient (26 years old) stained with AF. The AF reaction of tubular walls is much weaker than that in normal controls.
- Fig. 10. The undescended testis of a pre-pubertal cryptorchid patient (6 years old) stained with AF. The AF reaction of the tubular walls is apparently weaker than that in the normal fertile adults.
- Fig. 11. The contralateral scrotal testis of a post-pubertal cryptorchid patient (26 years old) stained with AF. Seminiferous tubular walls react to AF to the same intensity as those in the normal controls.
- Fig. 12. The testis of a normal fertile adult stained with AF following digestion with chondroitinase ABC. The enzyme digestion lead to a diminished AF reaction of seminiferous tubular walls.
- Fig. 13. The testis of a normal fertile adult stained with AF following digestion with chondroitinase AC. The AF reaction of seminiferous tubular walls is only slightly affected.
- Fig. 14. The testis of a normal fertile adult stained with PAS. The germinal and supporting cells in seminiferous tubules, tubular walls and interstitium exhibit a positive PAS reaction.

In the contralateral scrotal testes of the patients, however, even after puberty, thickening of the tubular walls and expansion of the intertubular spaces were not seen and spermatogenic activity was well maintained.

In the testes from normal fertile adults, the seminiferous tubular walls exhibited moderate to strong AB (pH 1.0), AB (pH 2.5) (Fig. 3) and AF (Fig. 8) reactions, and the interstitial tissue showed moderate or strong AB (pH 2.5) (Fig. 3) and mild or moderate AB (pH 1.0) and AF (Fig. 8) reactions. In the undescended testes from cryptorchids, the seminiferous tubular

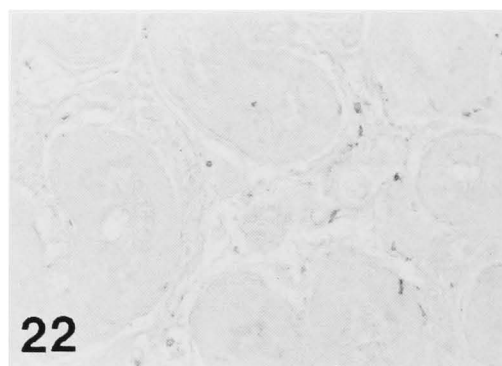
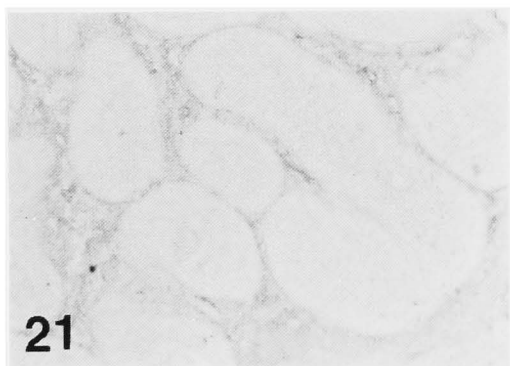
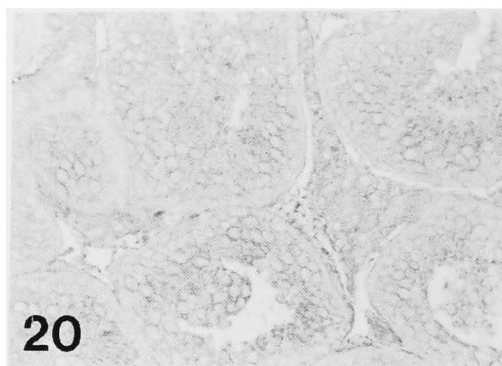
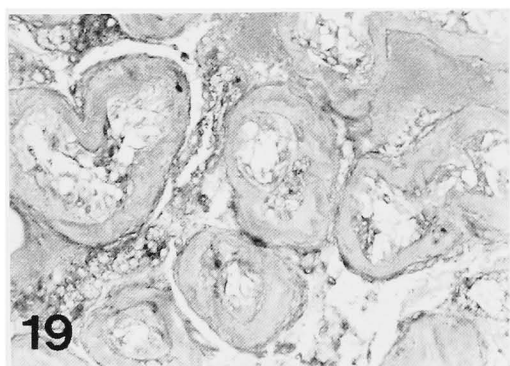
walls and interstitial tissues reacted positively with AB (pH 1.0), AB (pH 2.5) (Fig. 4) and AF (Fig. 9), but these reactions were apparently weaker in intensity than those seen in the tissue from normal individuals, and these changes were especially pronounced in the seminiferous tubular walls. In the undescended testes, although the seminiferous tubular walls reacted more weakly in pre- and post-pubertal cryptorchids than in normal adult testes, the interstitial tissues reacted more weakly in pubertal and post-pubertal patients than in pre-pubertal patients (Fig. 5 & 10). In the contralateral scrotal



- Fig. 15. The testis of a post-pubertal cryptorchid patient (30 years old) stained with PAS. Tubular walls and interstitium exhibit a positive PAS reaction, while germinal and supporting cells in the tubules show a markedly weaker PAS reaction, than in those of the normal controls.
- Fig. 16. The testis of a normal fertile adult stained with PAS following digestion with alpha-amylase. The PAS reaction of germinal and supporting cells is abolished by the enzyme digestion, but the reaction of seminiferous tubular walls and interstitium is only slightly affected or unaffected by the digestion.
- Fig. 17. The undescended testis of a post-pubertal cryptorchid patient (30 years old) stained with PAS following digestion with alpha-amylase. The enzyme digestion produces the same result as that in the testes of normal controls.
- Fig. 18. The testis of a normal fertile adult stained with Con A-PO-DAB. Germinal and supporting cells, seminiferous tubular walls and interstitium exhibit a positive Con A-PO-DAB reaction.

testes studied in the present study, the seminiferous tubular walls and the interstitial tissues reacted almost in the same manner as in those from normal fertile adults (Fig. 11). Digestions with sialidase and *Streptomyces* hyaluronidase failed to induce any notable changes in intensity of AB (pH 2.5) reactions in the tissues from either normal controls or cryptorchids. Digestion with testicular hyaluronidase diminished appreciably the intensity of AB (pH 1.0 and 2.5) and AF reactions in the testes from normal individuals and a similar suppressive effect of digestion with the enzymes was also noted in the tissues

from cryptorchid patients (undescended and contralateral scrotal testes). Digestion with chondroitinase ABC resulted in an apparent weakening in AB (pH 1.0 and 2.5) (Fig. 6) and AF (Fig. 12) reactions in the tissue of normal individuals, and this suppressive effect of enzyme digestion was much more marked in the tissues from the undescended testes of cryptorchid patients. In the testes of normal individuals and undescended testes from cryptorchids, digestion with chondroitinase AC led to a rather slight decrease in intensity of AB (pH 1.0 and 2.5) (Fig. 7) and AF (Fi. 13) reactions. In the series of enzyme



- Fig. 19. The testis of a post-pubertal cryptorchid patient (27 years old) stained with Con A-PO-DAB. The reaction of each histologic component shows no apparent difference from that in the testes of normal controls.
- Fig. 20. The testis of a normal fertile adult stained with PO-RCA-DAB. Germinal and supporting cells, seminiferous tubular walls and interstitium show a positive PO-RCA-DAB reaction.
- Fig. 21. The testis of a pre-pubertal cryptorchid patient (8 years old) stained with PO-RCA-DAB. Seminiferous tubular walls and interstitium show a positive PO-RCA-DAB reaction, while germinal and supporting cells exhibit an extremely weak or negative reaction.
- Fig. 22. The testis of a post-pubertal cryptorchid patient (26 years old) stained with PO-RCA-DAB. Thickened seminiferous tubular walls and interstitium show a positive PO-RCA-DAB reaction, while germinal and supporting cells exhibit a markedly weaker reaction than in normal controls.

digestion, descended contralateral testes of the unilateral cryptorchids showed a reaction similar to that of the testes of normal controls.

In the seminiferous tubules of the testes of the normal controls, the germinal and supporting cells exhibited a positive PAS reaction (Fig. 14). In the undescended testes from the pubertal and pre-pubertal cryptorchids, the germinal and supporting cells in the seminiferous tubules exhibited negative or extremely weak PAS reaction. In the undescended testes of the post-pubertal patients, the epithelial cells in the seminiferous tubules exhibited a much weaker PAS reaction than those of the normal controls (Fig. 15). In the undescended testes, the positive PAS reaction of the interstitial tissue was similar in intensity to that visualized in the tissue of the normal controls and the contralateral scrotal testes of the cryptorchids. However, the reaction of the seminiferous tubular walls appeared to be weaker in the undescended testes than in the normal controls and descended testes. Digestion with alpha-amylase abolished or considerably diminished the intensity of positive PAS reaction of the germinal and supporting cells but failed to alter, or affected only slightly, the positive PAS reaction of the tubular walls and interstitium in the testes of both normal controls and cryptorchid patients (Fig. 16, 17).

In the testes from the normal individuals, the seminiferous tubular walls, the interstitial tissues and the epithelial cells in the seminiferous tubules exhibited moderate or strong positive Con A-PO-DAB reaction (Fig. 18). In all of the histologic components of the testicular tissues, however, Con A-PO-DAB revealed no appreciable difference in intensity of the reaction among normal controls, undescended (Fig. 19) and descended scrotal testes from the cryptorchids.

In the testes of the normal fertile adults, the seminiferous tubular walls and the interstitial tissues showed a moderate or strong PO-RCA-DAB reaction (Fig. 20), and the epithelial cells in seminiferous tubules exhibited a mild or moderate

reaction (Fig. 20). In the contralateral scrotal testes from the patients, the PO-RCA-DAB reaction was similar in intensity to that in the normal controls in all the testicular tissue components. In the undescended testes, however, each component of the testicular tissue reacted to PO-RCA-DAB as follows. During the pre-pubertal and pubertal periods, the seminiferous tubular walls and the interstitial tissues exhibited moderate or strong reaction similar in intensity to that seen in the normal controls, whereas the epithelial cells in the seminiferous tubules showed a negative or only a slight reaction (Fig. 21). In the undescended testes of the post-pubertal cryptorchids, the PO-RCA-DAB reaction of the seminiferous tubular walls and the interstitial tissues were noted to be highly declined in intensity in comparison with those in normal controls, the contralateral scrotal testes from the post-pubertal patients or the undescended testes from the prepubertal patients (Fig. 22). After puberty, the reaction for PO-RCA-DAB in the epithelial cells in the seminiferous tubules appeared to be increased slightly, but was still definitely weaker than that in the normal controls or the contralateral scrotal testes (Fig. 22).

DISCUSSION

The staining specificity of the AB (pH 1.0)¹¹⁾ and AB (pH 2.5)¹⁵⁾ suggested that the seminiferous tubular walls and interstitial connective tissues from both normal and cryptorchid individuals contain acidic complex carbohydrates with sulfate esters and carboxyl groups. The substrate specificity of testicular hyaluronidase²¹⁾, and the present results of digestion with this enzyme upon the AB (pH 1.0 and 2.5) reactions of the seminiferous tubular walls and interstitial connective tissues in the normal individuals and cryptorchids indicate the presence of isometric chondroitin sulfates (A and/or C) in these histologic structures. Although elastin is known to react to AF as do acidic complex carbohydrates, elastin cannot be digested with the series of enzymes utilized in the present

study and the results with AF were almost the same as those with AB (pH 1.0). In tissues from both normal individuals and cryptorchids, the effects of digestion with chondroitinase ABC and AC upon the AB (pH 1.0 and 2.5) and AF reactions of the seminiferous tubular walls and interstitium appear to indicate the presence of various amounts of chondroitin sulfate B, in view of the substrate specificities of these enzymes^{19,20)} and the staining specificities of the reactions^{11,12)}. These findings were also the same as those reported previously for the testes of normal fertile adults⁷⁾, where normal individuals and patients with male infertility were examined by the same technique. In the undescended testes of the cryptorchid patients examined in the present study, the reaction was weak at all ages, and was especially pronounced in the seminiferous tubular walls, whereas in the contralateral scrotal testes the reactions were very similar to those of the normal controls. These findings suggest some quantitative alteration of the acidic complex carbohydrates described above in the undescended testes of the cryptorchids.

According to the present findings obtained by PAS staining employed in combination with alpha-amylase digestion, the germinal and supporting cells are thought to contain glycogen. Maseki (1980)⁷⁾ reported that the germinal and supporting cells from the patients with idiopathic male infertility contained a larger amount of glycogen than those in normal testes. Arzac (1959)⁴⁾ described that in the cytoplasm of the Sertoli cells glycogen increased in amount roughly according to the degree of hypoplasia. In the present study, however, the germinal and supporting cells in the undescended testes from cryptorchids contained only a small amount of glycogen in the pre-pubertal and pubertal periods and still a much smaller amount in the post-pubertal periods than in the testes from normal fertile adults. This difference, in the alteration of glycogen amounts contained in the intratubular epithelial cells, between undescended testes from cryptorchids and the testes from patients with idiopathic

male infertility, might reflect some difference in the pathogenesis of impaired spermatogenesis in the testes of each condition. The change in the amount of glycogen observed here in the undescended testes from pre-pubertal to post-pubertal periods suggested that the germinal and supporting cells have been continuously impaired from early childhood to adults without reaching their full maturation or attaining normal function. On the contrary, in the testes from patients with idiopathic male infertility, accumulation of excess glycogen in germinal and supporting cells might indicate that impaired function or metabolism of these cells, which have once obtained their complete maturation and normal function, would cause such excess accumulation possibly by lack of elimination and/or utilization.

In the testes from the normal controls and cryptorchids, the seminiferous tubular walls and interstitium exhibited an alpha-amylase resistant positive PAS reaction and positive Con A-PO-DAB reaction. From the staining specificities of the PAS¹²⁾ and Con A-PO-DAB^{14,22)}, these histologic structures are thought to contain complex carbohydrates with 1,2-glycol groups and alpha-mannosyl and alpha-D-glucosyl residues. However, we detected no appreciable changes in the undescended testes of the cryptorchid patients concerning these substances, as compared with the normal testes.

In normal individuals, the germinal and supporting cells, together with the tubular walls and interstitium, exhibited a strong or moderately positive PO-RCA-DAB reaction. This indicates the presence of complex carbohydrates with beta-D-galactose residues. Maseki (1980)²³⁾ reported that in the testes of patients with idiopathic male infertility this galactose residue is completely deficient in all the histologic structures. The testes of sterile mice were reported to contain relatively low levels of sulfoglycerogalactolipid than normal fertile mice²⁴⁾. Moreover, human seminoma tissues were recorded as being devoid of the seminolipid (1-0-alkyl-2-0 acyl-3 glycerol),

whereas the germinal cells of normal human testes contained this lipid²⁵). These facts strongly suggest that the galactose residues of complex carbohydrates are related to the normal process of spermatogenesis. In the undescended testes studied herein, the galactose residues were deficient at pre-pubertal and pubertal periods in the germinal and supporting cells and small in amount at post-pubertal periods, substantiating the relationship of these substances with the normal process of development and function of the tubular epithelial cells. However, deficiency of the galactose residues was not observed in the seminiferous tubular walls or interstitium of the undescended testes of cryptorchids, unlike in the testes of patients with idiopathic male infertility. These differences in PO-RCA-DAB reaction between the two disorders also imply some difference in the mechanism of testicular damage with the disease.

ACKNOWLEDGMENT

We express our gratitude to Professor Kazuyori Yamada (Department of Anatomy, Nagoya City University, School of Medicine) for his advice and comments on the preparation of this manuscript.

REFERENCES

- 1) Moormann JG: Untersuchungen bei der Lageanomalie des Hodens nach Behandlung mit humanem Chorion Gonadotrophin (hCG) im Tierversuch und am Klinischen Krankengut. *Ann Qniv Aarav* 19: 2~7, 1972
- 2) Hellinga G: Fertility after hormonal or surgical treatment from bilateral cryptorchidism. *Symposium Int Fertil Assoc* 25: 4, 1964
- 3) Gotoh M, Miyake K and Mitsuya H: A study on cryptorchidism. I; Light and electron microscopic study of Leydig cells in the testes of cryptorchid patients. *Acta Urol Jpn* 30: 327~347, 1984
- 4) Arzac JP: Glycogen in human testicular biopsy material. *J Clin Endocrinol* 10: 1465~1470, 1950
- 5) Mancini RE, Nolzco Jand de la Balze FA: Histochemical study of normal adult human testes. *Anat Res* 114: 127~147, 1952
- 6) Mancini RE, Narbaitz R and Lavieri JC: Origin and development of the germinative epithelium and Sertoli cells in the human testis. Cytological cytochemical and quantitative study. *Anat Res* 136: 477~489, 1960
- 7) Maseki Y, Miyake K and Mitsuya H: The histochemistry of the testis tissues from patients of idiopathic male infertility. Report I; Studies on complex carbohydrates (localization of acid mucopolysaccharides). *Jpn J Urol* 71: 1255~1280, 1980
- 8) Mancini RE, Roseberg E and Cullen M: Cryptorchid and scrotal human testes. I; Cytological, cytochemical and quantitative studies. *J Clin Endocrinol* 25: 927~941, 1964
- 9) Charny CW: Testicular biopsy. Its value in male sterility. *J Med Assoc* 115: 1492~1433, 1940
- 10) Charny CW and Meranze DR: Testicular biopsy. Further studies in male infertility. *Surg Gynecol Obst* 74: 836~842, 1942
- 11) Lev R and Spicer SS: Specific staining of sulphate groups with alcian blue at low pH. *J Histochem Cytochem* 12: 309, 1964
- 12) Pearse AGE: Histochemistry, theoretical and applied. Vol 1: 127~129, Churchill Livingstone, Edinburgh London and New York, 1968
- 13) McManus JFA: Histological and histochemical uses of periodic acid. *Stain Technol* 23: 99~108, 1948
- 14) Yamada K and Shimizu S: Concanavalin A-peroxidase-diaminobenzidine (Con A-PO-DAB)-alcian blue (AB). A reliable method for dual staining of complex carbohydrates. *Histochemistry* 47: 159~169, 1976
- 15) Yamada K and Shimizu S: The histochemistry of galactose residues of complex carbohydrates as studied by peroxidase-labeled *Ricinus communis* agglutinin. *Histochemistry* 53: 143~156, 1977
- 16) Spicer SS, Horn RG and Leppi TJ: Histochemistry of connective tissue mucopolysaccharides. In: *The connective tissue*, 251~303, Baltimore, Williams Wilkins, 1967
- 17) Yamada K: The effect of digestion with *Streptomyces* hyaluronidase upon certain histochemical reactions of hyaluronic acid-containing tissues. *J Histochem Cytochem* 21: 794~803, 1973
- 18) Leppi TJ and Stoward PJ: On the use of testicular hyaluronidase for identifying acid mucins in tissue sections. *J Histochem Cytochem* 13: 406~407, 1965
- 19) Yamada K: Histochemical and cytochemical methods for the study of mucopolysaccharides. *Protein Nucleic Acid Enzyme* 17: 775~790, 1972
- 20) Yamada K: The effect of digestion with

- chondroitinases upon certain histochemical reactions of mucopolysaccharide-containing tissues. *J Histochem Cytochem* 22: 266~275, 1974
- 21) Weissmann B, Hadjiioanon S and Tornheim J: Oligosaccharase activity of beta-N-acetyl-D-glucosaminidase of beef liver. *J Biol Chem* 239: 59~63, 1964
- 22) Kiernan JA: Localization of alpha-D-glucosyl and alpha-D-mannosyl groups of mucosubstances with concanavalin A and horseradish peroxidase. *Histochemistry* 44: 39~45, 1975
- 23) Maseki Y, Miyake K and Mitsuya H: The histochemistry of the testis tissues from patients of idiopathic male infertility. Report II; Studies on complex carbohydrate (localization of galactose residues). *Jpn J Urol* 71: 1271~1280, 1980
- 24) Kornblatt MJ, Knapp A, Levine M, Schachter H and Murray PK: Studies of structure and formation during spermatogenesis of the sulfoglycerogalactolipid of rat testis. *Can J Biochem* 52: 689~697, 1974
- 25) Ishizuka I and Yamakawa T: Absence of seminolipid in seminoma tissue with concomitant increase of sphingoglycolipids. *J Biochem* 76: 221~223, 1974
- (Accepted for publication, April 28, 1986)

和文抄録

停 留 精 巢 の 研 究

第3報：停留精巢患者における精巢内複合糖質の組織化学的研究

名古屋大学医学部泌尿器科学教室（主任：三矢英輔教授）

後藤 百万・三宅 弘治・三矢 英輔

停留精巢患者の停留精巢および対側陰嚢内精巢において、光顕組織化学的方法にて複合糖質の変化を観察し、さらに正常精巢組織と比較した。停留精巢精細管壁および間質では、正常精巢に比べ酸性ムコ多糖（精細管壁：コンドロイチン硫酸AおよびC，間質：コン

ドロイチン硫酸B）が減少し、特に精細管壁において顕著であった。停留精巢精細管上皮においては、思春期前から思春期以後を通じ、グリコーゲンおよびガラクトース含量の減少が認められた。