

Title	Nonsurgical management of ureteral fistulas
Author(s)	TAKEUCHI, Toshimi; OGUCHI, Kenichi; KURIYAMA, Manabu; KANEMATSU, Minoru; BAN, Yoshihito; HASEGAWA, Yoshikazu; ITO, Fumio
Citation	泌尿器科紀要 (1987), 33(4): 515-520
Issue Date	1987-04
URL	http://hdl.handle.net/2433/119108
Right	
Type	Departmental Bulletin Paper
Textversion	publisher

NONSURGICAL MANAGEMENT OF URETERAL FISTULAS

Toshimi TAKEUCHI, Kenichi OGUCHI,
Manabu KURIYAMA, MINORU KANEMATSU
and Yoshihito BAN

*From the Department of Urology, Gifu University School of Medicine
(Director: Prof. T. Nishiura)*

Yoshikazu HASEGAWA

*From the Department of Urology, Gero Prefectural Hot Spring Hospital
(Chief: Dr. Y. Hasegawa)*

Fumio ITO

*From the Department of Urology, Ibi General Hospital
(Chief: Dr. F. Ito)*

The combined procedure by antegrade introduction of the guidewire and retrograde placement of ureteral stents was successfully performed for the conservative management of postoperative ureteral fistulas in two patients. Superselector guidewire and ureteral bougie catheter are of use to facilitate difficult stent placement for severe narrowing accompanied with the dehiscence of the ureter.

Key words: Ureteral fistula, Ureter, Ureteral stent, Endourology

INTRODUCTION

The ureteral fistula is rarely encountered. Various surgical approaches may result in failure by the devitalization of the ureter attendant with prior surgery or irradiation¹⁾. Occasionally, definitive surgical procedures must be postponed until fistulas have dried up after urine flow have been rerouted by nephrostomies²⁾.

Current advances in percutaneous surgery of the upper urinary tract diseases are well documented. For the ureteral fistulas, many investigators have reported conservative management using percutaneous nephrostomies and internal stents³⁻⁵⁾. Herein, we report two cases of ureteral fistulas successfully treated by a combined antegrade and retrograde approach, with a review of the literature.

CASE REPORT

Case 1: A 34-year-old woman, with a

past history of neurosis, was hospitalized to retract left ureteral calculus, measuring 9×6 mm, transurethrally by the basket catheter. Despite successful stone removal, left ureteral injury occurred. Therefore, emergency exploration with surgical repair of the affected ureter was performed under general anesthesia. The longitudinal defect of 1 cm in length at the left middle ureter was sutured interruptedly with a 0000 cat gut, and a 6 Fr silicon double J catheter was left in place as a ureteral stent. However, because a large amount of infected urine continued to flow out through the tube, the indwelling catheter was removed 18 days after surgery. Urine leakage from the left ureter increased in volume. A DIP showed evident leak and no passage into the distal segment of left ureter (Fig. 1). A retrograde catheterization to the left ureter was not feasible, and subsequent retrograde ureterogram demonstrated complete obstruction at the

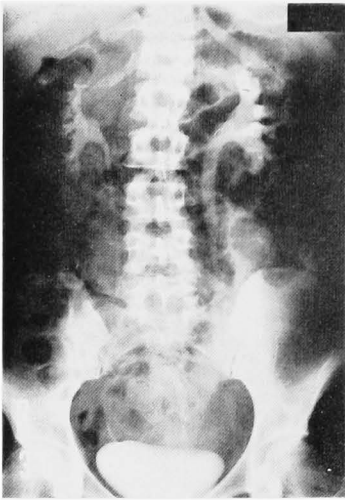


Fig. 1. A DIP shows mild hydronephrosis of the left kidney. Note evident leak and no passage into the distal segment of left ureter.

middle segment. Therefore, a left percutaneous nephrostomy was performed under local anesthesia 1 month postoperatively (Fig. 2) and followed by the combined procedures of left ureteral catheterization 5 days later. Initially, a hook angiographic catheter was placed above the narrow segment under fluoroscopic guidance. Y-K type of Superselector guidewire (Toray

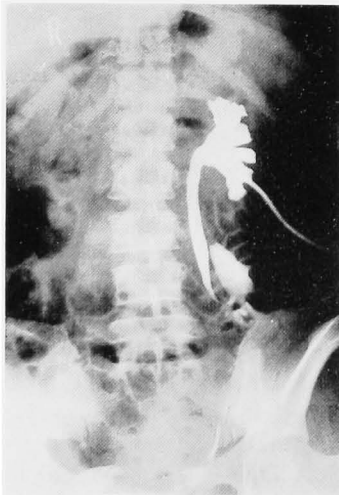


Fig. 2. Left antegrade pyeloureterogram demonstrates leak of the contrast medium to left peritoneal space. The contrast medium flows into the distal ureter, while the affected segment is long and deviated laterally.

Medical Co. Ltd., Japan) was successfully passed through to the bladder (Fig. 3), and then a 6 Fr ureteral bougie catheter (Cook Urological Co. Ltd., USA), instead of the angiographic catheter was slowly advanced over the preceding guide wire to the bladder. Finally, the bougie catheter was exchanged for a 5 Fr whistle-tipped ureteral catheter, which was introduced transurethrally and placed as an external stent. The clinical status of

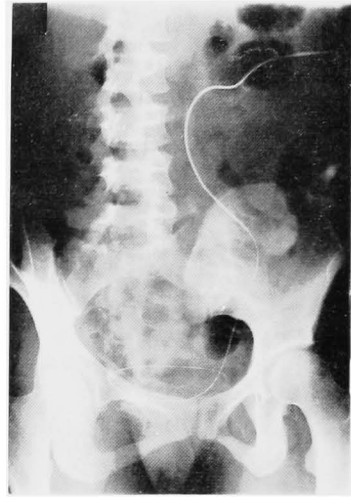


Fig. 3. Y-K type of Superselector guidewire successfully passes through dehiscent ureter to the bladder.

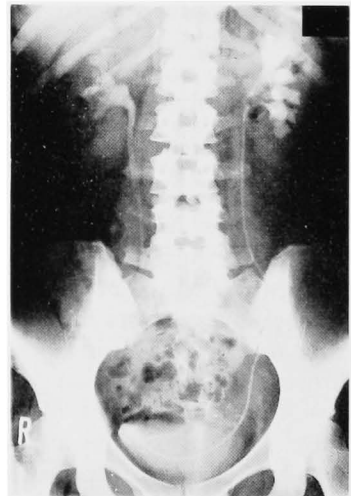


Fig. 4. An IVP one week after the combined stenting reveals disappearance of ureteral leak. 6 Fr double J catheter is left in place instead of the external stent.

the patient improved rapidly thereafter. Urine leakage ceased one week after the combined stenting, and the external stent catheter was exchanged for a 6 Fr silicon double J catheter (Fig. 4) followed by removal of the left nephrostomy catheter. The internal double J stent was left in place for one month. Eight months later, she is asymptomatic and free from catheter with the improvement of the left ureterec-

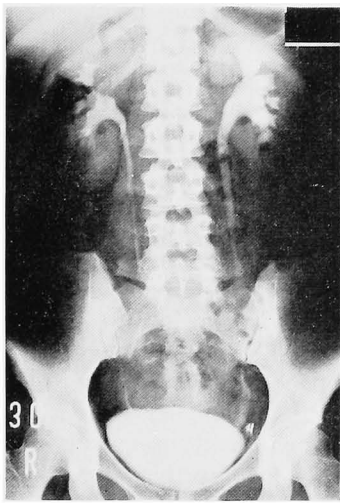


Fig. 5. A DIP 8 months later shows that ureterectasis has resolved with evident contrast opaciation of the distal ureter.

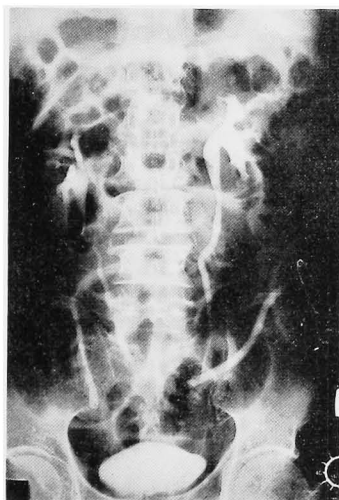


Fig. 6. A DIP shows the contrast medium from the left collecting system leaks into the drainage tube. There is no passage into the distal segment of left ureter.

tasis on DIP (Fig. 5).

Case 2: A 62-year-old man, complaining of bloody stool, received the anterior resection for rectal carcinoma. One week postoperatively, a large amount of urine-like fluid began to drain from the silicon drainage tube surgically placed at the left iliac fossa. A DIP revealed medial deviation and obstruction of the left ureter, resulting in leakage of the contrast medium to the iliac fossa (Fig. 6). The percutaneous maneuver was required since the left ureteral catheterization in a retrograde fashion failed. Subsequent antegrade advancement of a 6 Fr ureteral bougie catheter over Superselector guidewire was feasible (Fig. 7). After replacing the

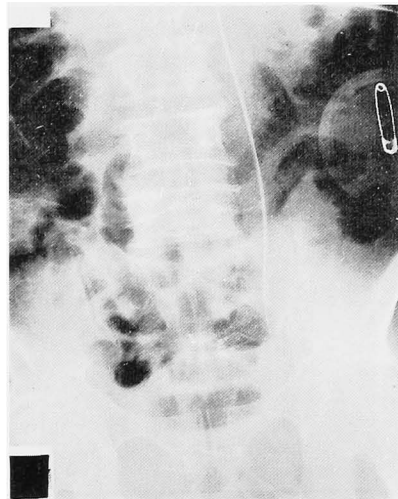


Fig. 7. 6 Fr ureteral bougie catheter over Superselector guidewire successfully advances through the left nephrostomy.

superselector guidewire with a 0.038 inch guidewire by cystoscopic control, Ducol angiographic catheter (Cordis Co. Ltd., USA), cut to the proper length before insertion, was placed in the left ureter. The fistula healed dramatically soon after those managements (Fig. 8), and the nephrostomy catheter was removed 2 weeks later. The left ureteral stent was subsequently taken away. A DIP taken 3 months later demonstrated normal passage of the contrast medium in the left ureter (Fig. 9). He has been asymptomatic for one year.

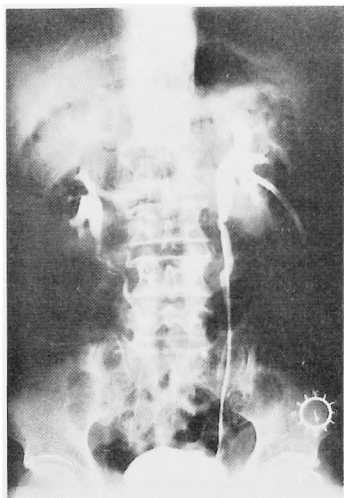


Fig. 8. A DIP 2 weeks after the combined stenting demonstrates no leak into the left iliac fossa with mild ureterectasis.

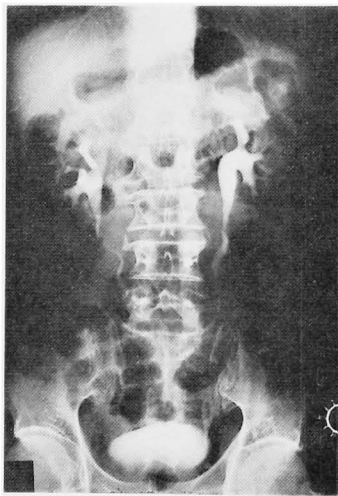


Fig. 9. A DIP 3 months after removal of the stent reveals normal passage of the contrast medium from the left collecting system.

DISCUSSION

A ureteral fistula uncommonly occurs in patients complicated with infection, inflammation and urinary leakage. Anatomically, five types of ureteral fistula can be classified²⁾: 1) ureterovaginal; 2) ureterocutaneous; 3) ureteroenteric; 4) ureteroretroperitoneal (urinoma) and 5) lymphaticoureteral fistula.

Patients with benign disease may present

the complex fistula of ureter defying surgical repair. The surgical approach for simple types of ureteral fistulas may be impossible in patients with high operative risk because of concomitant disease. Therefore, the surgical procedures tend to result in a lower salvage rate of a functional renal unit, compared to the conservative management²⁾. The propensity of uroepithelium to grow across a partial or near complete dehiscence provides the basis for conservative management⁶⁾. A small fistula with an otherwise intact ureteral wall will often close in 10 to 14 days if a ureteral catheter can be passed beyond the injury⁷⁾. Andriole and associates⁸⁾ reported that a half of ten patients with upper urinary fistulas healed with double-J ureteral stent without an operation. Internal stents allow not only smooth urine flow into the bladder, but they also provide internal supports around which the ureter can heal⁴⁾. External drainage by percutaneous nephrostomy may suffice for the management of smaller fistulas. In fact, several patients with ureterovaginal fistula who had nephrostomy alone had successful spontaneous closure of the fistula⁷⁾. The percutaneous nephrostomy may play a safe-guarding role in preventing the renal function from being damaged by subsequent obstruction to the fistula. Furthermore, the technique of percutaneous nephrostomy provides a nonsurgical approach for the placement of antegrade ureteral stents. This antegrade stenting of the ureter has been successfully applied in the treatment of ureteral leaks and fistulas^{3,4)}. The possibility of introducing guidewire and catheter will depend on the severity of tortuosity, dehiscence and narrowing of the affected ureter. In the point of passing a guidewire through such a complicated ureter, an antegrade stenting can be more accessible than a retrograde one, since the latter may occasionally make a troublesome angulation of the guidewire. Even in the case of a nearly complete dehiscence of the ureter, the guidewire can often be advanced in an antegrade fashion along remaining tissue bridges into the distal segment of the

ureter²⁾. Superselector guidewire could be used to pass through a long, tortuous and tight narrowing, and following gradual dilation with ureteral bougie catheters might be of great advantage to the placement of indwelling stents. Even though healing of any defect invokes fibroblastic activity and hence the formation of cicatricial tissues, placement of a larger stent tends to ensure maintenance of a more sufficient lumen⁹⁾. The most appropriate timing for antegrade catheterization, however could not be equivocal because of the various local conditions.

Lang²⁾ recommended the exchange of stent catheters, possibly larger caliber catheter, or repeated dilation to prevent cicatricial strictures which might develop after the removal of the stent. However, the long-term followup after removal of ureteral stents has not been documented yet. We emphasize the use of stent catheters temporary for 4~8 weeks, which could be more appropriate than long-term placement. The ureteral stent must be one of the foreign bodies despite various materials of catheter available. One case presented in this study suggested that silicon double J stent with lots of side holes is not always the most adequate catheter, because of urine leakage from its side holes.

There are some limitations in the technique to introduce the stent catheter to the affected ureter. In inoperable cases due to advanced pelvic malignancies, new applications including ureteral embolization^{8,10)} and balloon occlusion^{11,12)} may be available. Fistula arising from severely ischemic donor ureter in the patients with renal transplantation hardly heal spontaneously, so, in such cases, surgical repair using the recipient's own ureter may be the best treatment¹³⁾.

The combined procedure by antegrade introduction of the guidewire and retrograde placement of ureteral stent is of great use as shown in the present cases. This technique is valuable for the conservative management of ureteral fistula with

severe damage.

REFERENCE

- 1) Koningsberg H, Blunt KJ and Muecke EC: Use of Boari flap in lower ureteral injuries. *Urology* 5: 751~755, 1975
- 2) Lang EK: Management of ureteric fistulae and strictures by antegrade percutaneous stent catheter and percutaneous antegrade dilatation, Current concepts of uro-radiology, Lang EK, 211~223, Williams & Wilkins, Baltimore, 1984
- 3) Lang EK, Lanasa JA, Garrett J, Stripling J and Palomar J: The management of urinary fistulas and strictures with percutaneous ureteral stent catheters. *J Urol* 122: 736~740, 1979
- 4) Bettman MA, Murray PD, Perlmutter LM, Whitmore III WF and Rickie JP: Ureteroileal anastomotic leaks: Percutaneous treatment. *Radiology* 148: 95~100, 1983
- 5) Nieh PT: Ureteroileal fistulas. *J Urol* 130: 555~557, 1983
- 6) Lang EK: Antegrade ureteral stenting for dehiscence, strictures, and fistulae. *AJR* 143: 795~801, 1984
- 7) Ross M Jr: Ureterovaginal fistula, Current urologic therapy, 2, Kaufman JJ, 214~217, W.B. Saunders Company, Philadelphia, 1986
- 8) Andriole GL, Bettmann MA, Garnick MB and Richie JP: Indwelling double-J ureteral stents for temporary and permanent urinary drainage: Experience with 87 patients. *J Urol* 131: 239~241, 1984
- 9) Gunther R, Marberger M and Klose K: Transrenal ureteral embolization. *Radiology* 132: 317~319, 1979
- 10) Papanicolaou N, Pfister RC and Yoder IC: Percutaneous occlusion of ureteral leaks and fistulae using nondetachable balloons. *Urol Radiol* 7: 28~31, 1985
- 11) Gunther R, Klose K and Alken P: Transrenal ureteral occlusion with a detachable balloon. *Radiology* 142: 521~523, 1982
- 12) Kinn AC, Ohlsen H, Brehmer-Andersson E and Brundin J: Therapeutic ureteral occlusion in advanced pelvic malignant tumors. *J Urol* 135: 29~32, 1986
- 13) Schiff M Jr, McGuire EJ, Weiss RM and Lytton B: Management of urinary fistulas after renal transplantation. *J Urol* 115: 251~256, 1976

(Accepted for publication March 20, 1986)

和文抄録

尿管瘻に対する保存的治療

岐阜大学医学部泌尿器科学教室（主任：西浦常雄教授）

竹内敏視・小口健一

栗山学・兼松稔

坂義人

岐阜県立下呂温泉病院泌尿器科（医長：長谷川義和）

長谷川義和

揖斐総合病院泌尿器科（部長：伊藤文雄）

伊藤文雄

順行性にガイドワイヤー挿入ののち、逆行性に尿管ステントを留置することにより、術後尿管瘻2例を保存的に治療した。断裂尿管に伴う尿管狭窄によりステ

ント挿入が困難な症例に対し、スーパーセクターガイドワイヤーと尿管拡張カテーテルは有用である。