

Title	Masculinizing operation for a female patient with congenital adrenocortical hyperplasia due to 21-hydroxylase deficiency
Author(s)	OKUYAMA, Akihiko; TAKIUCHI, Hidekazu; KAJIKAWA, Hiroshi; TADA, Yasuharu; NAMIKI, Mikio; NAKANO, Etsuji; TAKAHA, Minato
Citation	泌尿器科紀要 (1985), 31(11): 2003-2005
Issue Date	1985-11
URL	http://hdl.handle.net/2433/118660
Right	
Type	Departmental Bulletin Paper
Textversion	publisher

MASCULINIZING OPERATION FOR A FEMALE PATIENT WITH CONGENITAL ADRENOCORTICAL HYPERPLASIA DUE TO 21-HYDROXYLASE DEFICIENCY

Akihiko OKUYAMA, Hidekazu TAKIUCHI, Hiroshi KAJIKAWA,
Yasuharu TADA, Mikio NAMIKI, Etsuji NAKANO
and Minato TAKAHA

*From the Department of Urology, Osaka University Hospital
(Director: Prof. T. Sonoda)*

A 25-year-old female with simple virilizing type of congenital adrenocortical hyperplasia due to 21-hydroxylase deficiency was treated surgically with masculinizing operations which consisted of two-stage procedures. The first procedure was chordectomy associated with excision of both gonads and female internal genitalia. Eleven months later, the second procedure consisting of urethroplasty and implantation of testicular prosthesis was performed. The postoperative course was successful in terms of urination and penile erection.

Key words: Congenital adrenocortical hyperplasia, Ambiguous genitalia, Masculinizing operation

INTRODUCTION

Congenital adrenocortical hyperplasia represents the most common cause of ambiguous genitalia in female infants. A variety of enzymatic defects exist, which result in excessive secretion of adrenal androgen. In cases of 21-hydroxylase deficiency, the treatment with glucocorticoid is started from early infancy after diagnosis is established from elevated 17-ketosteroids and pregnanetriol levels²⁾. In this paper, an unusual case of 21-hydroxylase deficiency treated in adult age with masculinizing operation is reported.

CASE REPORT

The patient weighed 2,730 g at birth after the second full term pregnancy of a 23-year-old woman. Pregnancy was uncomplicated and no medications other than vitamins were taken by the mother. In spite of ambiguous external genitalia and hyperpigmentation, abnormalities were not examined and treated by a pediatrician in the early period of life. The

patient was reared as a boy. At 25 years of age, the patient was admitted to our hospital for examination and treatment of her abnormalities, with a height of 144.7 cm and weight of 47.6 kg (Fig. 1 and 2), and was diagnosed to have congenital adrenocortical hyperplasia due to 21-hydroxylase deficiency from the elevated urine levels of both 17-ketosteroids and pregnanetriol. The karyotype was 46XX. Because of the patient's age, psychological and social sex and external physical sex in addition to personal wishes, bilateral gonadectomy, excision of female internal genitalia and chordectomy were performed in the first operation. From the findings obtained during operation, the correlation between female urethra and vaginal opening was Prader's type III or IV. Eleven months later, the second operation which consisted of urethroplasty under the Denis-Browne's method and implantations of siliconized testicular prosthesis into both scrotal pockets was performed. Postoperative course was uneventful. Urination in standing po-

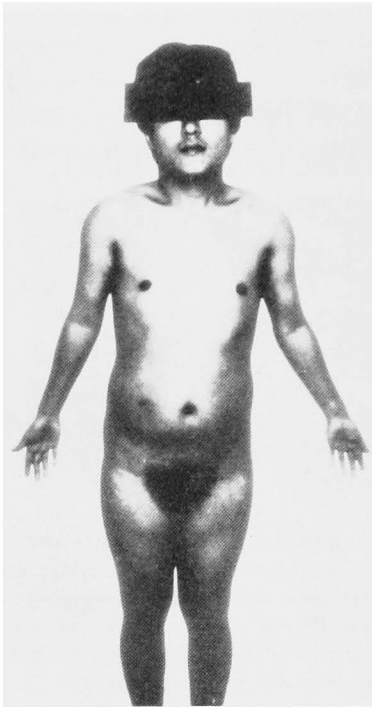


Fig. 1. Body profile showing small stature and hyperpigmentation

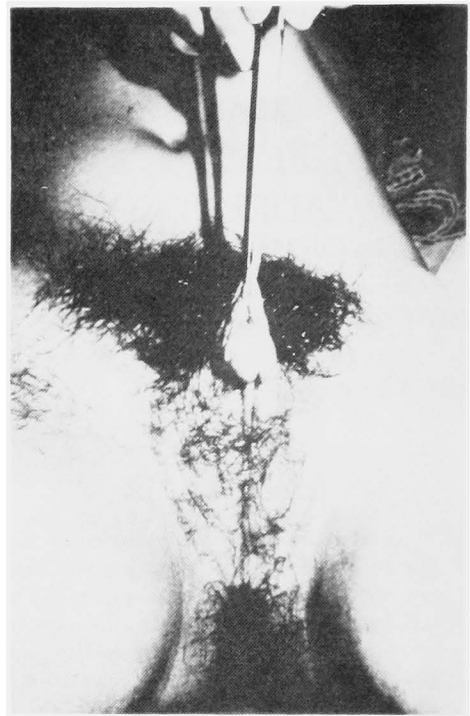


Fig. 2. External genitalia showing perineal hypospadias and bifid scrotum. Gonads could not be palpable in both scrotums and inguinal areas

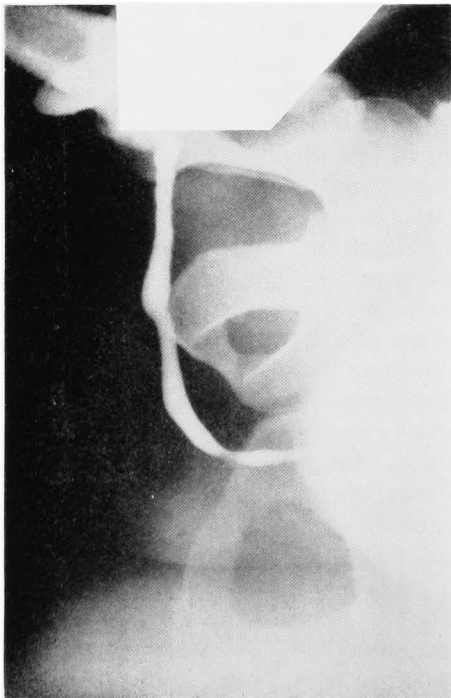

Fig. 3. Retrograde urethrocytogram showing new urethral orifice opening at the tip of the glans

sition could be done successful and penile erection was noted with no evidence of a ventral curvature (Fig. 3). Post-operative course of hormonal adjunctive therapy with testosterone enanthate was planned.

COMMENT

The variable type of masculinization in 21-hydroxylase deficiency may depend on such factors as the timing of the appearance of excessive androgen and endorgan sensitivity to androgen. The degree of masculinization varies from only hypertrophy of clitoris to urethral opening at the tip of the glans¹⁾. So selection of sex which should be accepted and indication of surgical repair depend on the age of the patient at diagnosis, psychological or social sex and severity of masculinization³⁾. Our patient, excision of the gonad and urethroplasty to male type were justified to prevent her social and

psychological trauma, although the patient would be infertile.

REFERENCES

- 1) Fay R and Brosman S : Surgical management of female congenital adrenal hyperplasia (Adrenogenital syndrome). J Urol **112**: 813~818, 1974
- 2) Lee PA, Plotnick LP, Kowarski AA and

Migeon CJ: Congenital adrenal hyperplasia. University Park Press, Baltimore, London, Tokyo, 1977

- 3) Redman JF and Gould JB : Extreme virilization in a karyotypic female subject with congenital adrenocortical hyperplasia. J Urol **108**: 500~501, 1972

(Accepted for publication March 7, 1985)

和文抄録

男性化手術を施行した女子先天性副腎皮質過形成 (21-hydroxylase 欠損) の1例

大阪大学医学部泌尿器科学教室 (主任: 園田孝夫教授)

奥山 明彦・滝内 秀和*
 梶川 博司**・多田 安温
 並木 幹夫・中野 悦次
 高 羽 津

21-hydroxylase 欠損による先天性副腎皮質過形成をもつ25歳女子 (戸籍上は男子) 症例に対して2度にわたる男性化手術をおこなった。

1度目は卵巣子宮付属器切除術と索切除術であり、

2度目は11ヵ月後の尿道形成術と両側偽辜丸挿入術である。術後の排尿機能と勃起の状態は良好であった。

*現: 大阪厚生年金病院

**現: 市立堺病院