

Title	Squamous metaplasia of the trigone in women with recurrent cystitis syndrome
Author(s)	MURAKAMI, Shino; IGARASHI, Tatsuo; TAKAHARA, Masanobu; YAMANISHI, Tomonori; SHIMAZAKI, Jun; SHIGEMATSU, Hidekazu
Citation	泌尿器科紀要 (1985), 31(2): 301-307
Issue Date	1985-02
URL	http://hdl.handle.net/2433/118404
Right	
Type	Departmental Bulletin Paper
Textversion	publisher

SQUAMOUS METAPLASIA OF THE TRIGONE IN WOMEN WITH RECURRENT CYSTITIS SYNDROME

Shino MURAKAMI

Tatsuo IGARASHI, Masanobu TAKAHARA and Tomonori YAMANISHI

From the Department of Urology, Asahi General Hospital

Jun SHIMAZAKI

From the Department of Urology, School of Medicine, Chiba University

Hidekazu SHIGEMATSU

From the Department of Pathology, School of Medicine, Shinsyu University

Urocytic mucosal biopsies of the white patch on the trigone in 44 women complaining of dysuria and frequency with or without bacteriuria showed varying degrees of squamous metaplasia as well as submucosal fibrosis. The patients with more frequent episodes of such symptoms in the past had more severe squamous metaplasia with submucosal fibrosis. Introital bacteria were found in almost all patients with mild or moderate development of squamous metaplasia, but not in those with severe lesions.

These facts suggest that introital bacteria may be one of the causative factors for the initiation and early development of these abnormal mucosal changes. However, the further progression to severe mucosal alteration seems to be independent of any bacteria and this severe mucosal alteration may result in recurrence of such symptoms.

Key words: Recurrent female cystitis, Squamous metaplasia, Introital bacteria

INTRODUCTION

Cystoscopic examination of women with the cystitis syndrome such as recurrent dysuria, frequency, urgency and suprapubic discomfort often reveals a white patch on the trigone, usually but not always well demarcated and sometimes irregular in shape (Fig. 1). Reports dealing with the relation between this pathological change and such a syndrome are very few. The purpose of this study was to analyze the relationship between the white patch and the recurrence of this syndrome, as well as its pathogenesis.

MATERIALS AND METHODS

Four hundred twelve adult women ranging from 17 to 78 years old (mean 42.3

yrs.) who had the complaint of at least frequency and dysuria (cystitis syndrome) with or without significant bacteriuria were treated in our department from April 1, 1981 to March 31, 1982. As a rule, urinalysis, urine culture, the examination of introital bacteria and cystoscopy were performed in all cases. Each culture with more than 10^5 organisms/ml of catheter-drained urine was defined as significant bacteriuria, and positive introital bacteria was diagnosed when over 100/ml of enterobacteriaceae or enterococcus was found by using the technique described by Stamey et al¹⁾. In these 412 patients, the occurrence of the white patch was analyzed in connection with past episodes and their ages. Furthermore, the tissue of white patch were taken under cystoscopy from 44 patients and fixed in formalin and pro-

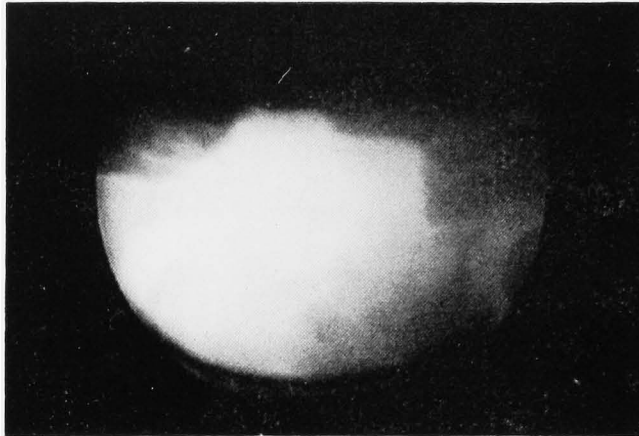

Fig. 1. Cystoscopic appearance of white patch

cessed by routine histological examination. The mean age of these 44 patients was 45.8 yrs. (range 21 to 71). Forty-one of these patients had had at least 1 prior episode. Six of these 44 patients had significant bacteriuria and 35 showed positive introital bacteria. The histological findings were compared with the previous number of this syndrome and bacteriological date.

RESULTS

(1) Frequency of white patch

The patients were divided into 2 groups:

Group 1 consisted of 213 patients without any symptoms in the preceding 12 months and group 2 consisted of the other 199 patients with at least one episode of such syndrome during the same period. The cystoscopic examination revealed significantly frequent occurrence of white patch on the trigone in group 2 (Table 1).

(2) White patch and age

The patients were further classified into three age groups: 17 to 40 years, 41 to 60 years and 61 years or older. According to this classification, there was no significant difference in the occurrence of white patch

Table 1. Frequency of white patch in 412 women

	with white patch	without white patch
Group 1*	15	198
Group 2	94	105
17-40 yrs.	49	131
41-60	42	110
61-	18	62

*Group 1: Women without any symptoms in the preceding 12 months

Group 2: Women with at least one episode

There is statistically significant difference in the frequency of white patch between Group 1 and 2 by chi square test ($p < 0.001$). However, the occurrence of white patch is not statistically significant among 3 different age groups.

Table II. Relationship between white patch and introital bacteria

	white patch (+)	white patch (-)
introital bacteria (+)	87	142
introital bacteria (-)	22	161

There is statistical significance in difference in the frequency of white patch between introital bacteria positive and negative groups by chi square test ($p < 0.0005$).

between the groups, as shown in Table I.

(3) Relationship between white patch and introital bacteria

The patients were divided into those with or without white patch and those with or without introital bacteria, and the relationship between white patch and introital bacteria was analysed by the chi square test. As shown in Table II, there was a high statistical significance ($p < 0.005$) between white patch and introital bacteria.

(4) Histology of white patch

Forty-four mucosal biopsies of white patch were examined in sections stained by hematoxylin and eosin. Histology of white patch was characterized by varying degrees of squamous metaplasia on the mucosa of transitional cells with inflammation and/or fibrosis of submucosa. Consequently, the cases were classified histologically according to the changes of mucosa and submucosa as follows: Mucosal chan-

ges- Type 1, Squamous metaplasia (SM) without keratinization (mild SM); Type 2, SM with parakeratosis (moderate SM); Type 3, SM with keratinization (severe SM); Submucosal changes Type A, Infiltration of inflammatory cells; Type B, Inflammation with focal fibrosis and sclerosis; Type C, Broad fibrosis and sclerosis (Fig. 2). As shown in Table III, considerable correlation was observed between the progression of mucosal changes and that of submucosa. In particular, the progression of SM and seemed to be influenced by submucosal fibrosis.

(5) Histological changes and past episodes

Of these 44 patients, 11 had more than 6 episodes of the syndrome in the preceding 12 months, 19 had a frequency of 3~5, and 14 had two or less. Here, a single episode was defined as that which had at least three successive days of remission during the long-term clinical course. The comparison of the frequency of the syn-

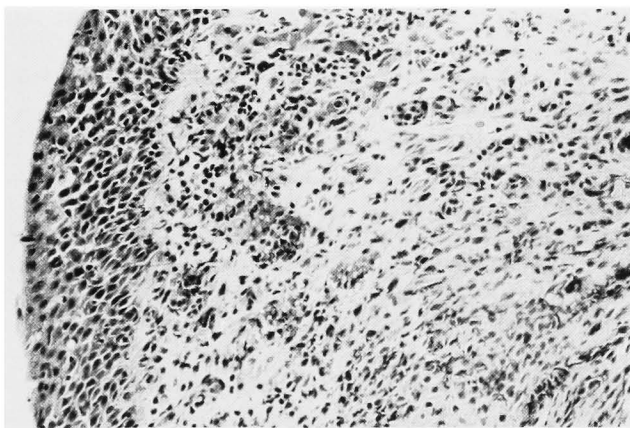


Fig. 2. a: Squamous metaplasia and florid submucosal inflammation. Type 1-A, $\times 250$

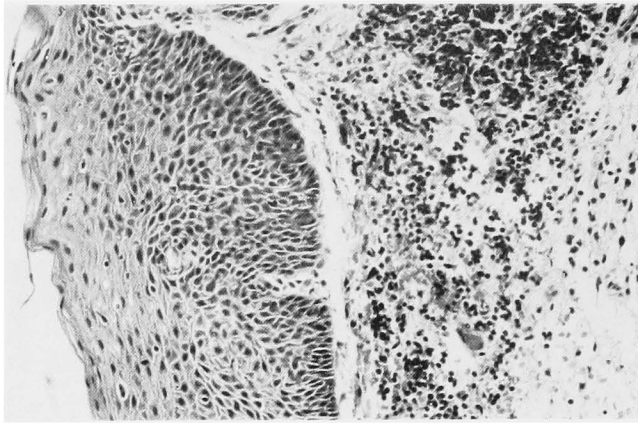


Fig. 2. b: Parakeratosis of the mucosal epithelium and submucosal infiltration with sclerosis. Type 2-B, $\times 250$

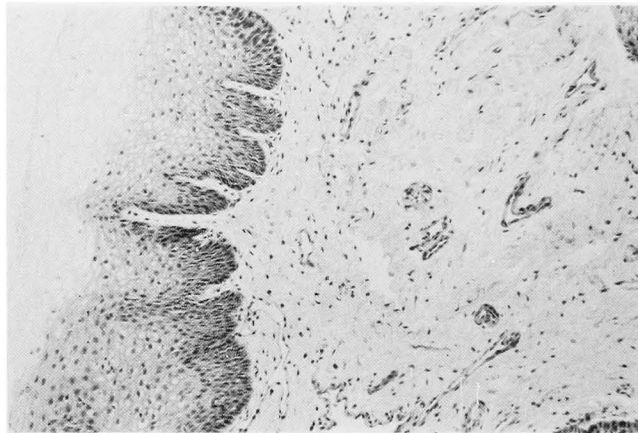


Fig. 2. c: Keratinization of mucosal epithelium with submucosal sclerosis and fibrosis. Type 3-C, $\times 250$

Table III. Relationship between pathological changes of mucosa and submucosa

	Type A	Type B	Type C	Total
Type 1*	11	2	0	13
Type 2	2	19	3	24
Type 3	0	1	6	7
Total	13	22	9	44

*Type 1~3 and Type A-C shows grade of pathological changes in mucosa and submucosa, respectively. Classification of grade: see text.

Table IV. Relationship between pathological changes and frequency of past episode

	6 times or more	3-5 times	2 times or less
Type 1	0	2	11
Type 2	5	16	3
Type 3	6	1	0
Type A	0	2	11
Type B	2	17	3
Type C	9	0	0

Table V. Relationship between pathological changes and bacterial infection

	bacteriuria (+)	introital bacteria (+)
Type 1-A	6/11	10/11
Type 2-B	0/19	19/19
Type 3-C	0/6	0/6

Grade of pathological changes: see text. Numerator and denominator show number of positive cultures and number of cases examined, respectively.

drome with the histological types was shown in Table IV. It was apparent that patients with more frequent episodes of the syndrome had more severe SM and submucosal fibrosis.

(6) Histological changes and infection

Referring to the correlation of the lesions of mucosa and submucosa as shown in Table III and IV, the type possessing histological finding of Type 1 and Type A was expressed as Type 1-A, Type 2 and Type B as Type 2-B, and Type 3 and Type C as Type 3-C. Thus, the laboratory findings for bacteriuria and introital bacteria were compared with the group of Type 1-A, Type 2-B and Type 3-C respectively. As shown in Table V, bacteriuria was found only in the group of Type 1-A, and introital bacteria was found in most of Type 1-A and Type 2-B, but not in Type 3-C.

DISCUSSION

The cystitis syndrome such as recurrent

dysuria, frequency, urgency and suprapubic discomfort is an important cause of morbidity in female patients at all ages. The etiology and treatment of this condition have been controversial. Detrusor dysfunction²⁾, increasing fibrous tissue in the urethrovaginal septum³⁾, psychogenetic emotion⁴⁾, introital bacterial¹⁾ and some other factors have been reported to be one of the causative factors of this condition by various authors.

Packham⁵⁾ found that 42 to 50 women with recurrent cystitis symptoms had squamous metaplasia on their trigone, and postulated that the symptoms were due to such abnormal mucosal changes. In contrast, Widran and others described⁶⁾ that the symptoms were not attributed to squamous metaplasia in a study of 450 patients. Our results were similar to Packham's report: the white patch on the trigone consisted of varying degrees of squamous metaplasia of mucosa, and especially pa-

tients with frequent episodes of the symptoms having the more severe changes.

A casual relationship between high serum estrogen and trigonal squamous metaplasia has been postulated by Packham. However, according to our results, postmenopausal women with a supposedly low serum estrogen level showed the tendency in the occurrence of the white patch to be quite similar to women with seemingly normal or high serum estrogen levels. Therefore, we suggest that the squamous metaplasia on the trigone is not principally influenced by serum estrogen.

It has been generally discussed that pathogenetic basis for squamous metaplasia is almost likely caused by chronic or recurrent irritation, inflammation or infection. Stamey and others stressed that introital bacteria was the cause of recurrence of lower urinary tract infection. Previously, we reported that the incidence of introital bacteria was only 5.8% in the women without any cystitis syndrome and ranging in age from 21 to 62 years old⁷⁾. In the present study, a significant correlation was found between white patch and introital bacteria, and white patch was found at a high frequency in group 2. Further, introital bacteria were found in most cases of Type 1-A and 2-B. From these results we can suppose that long-term stimulation by introital bacteria could be one of the most important factors for the initiation and early progression of white patch. In other words, recurrent cystitis syndrome with introital bacteria might be the result of not only urinary tract infection as Stamey and others stated, but also mucosal squamous metaplasia.

Further additional information about recurrent cystitis syndrome was obtained in the present study. It is noteworthy that the symptoms were observed in severe metaplastic cases without any urinary and introital bacteria in our study. In particular, type 3-C might be a highly metaplastic stage and it could cause the symptoms without any bacterial infection. The symptoms in this situation might be initiated rather by interfering with the normal contraction and dilatation of the bladder,

since these abnormal metaplastic cells do not slip by each other as easily as normal urothelium⁸⁾.

The use of some drugs which eradicate introital bacteria might be effective as prophylaxis against the initiation of squamous metaplasia. We have had good results against the recurrence of this syndrome by using trimethoprim-sulfamethoxazole at an early metaplastic period, which has been reported to be effective for introital enterobacteriaceae⁹⁾. Furthermore, from the results that the progression of squamous metaplasia had a strong correlation with that of submucosa, treatment of the progression of submucosal fibrosis may be effective in suppressing the progression of mucosal metaplasia. Trial mucosal injection of corticosteroid, which is well known to be effective against fibrosis, is currently in progress.

REFERENCES

- 1) Stamey TA, Timothy M, Millar M and Mihara G: Recurrent urinary infections in adult women. The role of introital enterobacteria. *Calif Med* 115: 1, 1971
- 2) Elder DD and Stephenson TP: An assessment of the frewen regimen in the treatment of detrusor dysfunction in females. *Br J Urol* 52: 467, 1980
- 3) Splatt AJ and Weeden D: The urethral syndrome. Morphological studies. *Br J Urol* 52: 263, 1980
- 4) Carson CC, Segura JW and Osborne DM: Evaluation and treatment of the female urethral syndrome. *J Urol* 124: 609, 1980
- 5) Packham DA: The epithelial lining of the female trigone and urethra. *Br J Urol* 43: 201, 1971
- 6) Widran J, Sanchez R and Gruhn J: Squamous metaplasia of the bladder. A study of 450 patients. *J Urol* 112: 479, 1974
- 7) Murakami S, Fujita M and Tamura K: Recurrent acute cystitis in women - The effect of topical antimicrobial ointment. *Jap J Clin Urol* 31: 413, 1977
- 8) Mostofi FK and Leestma JE: Lower urinary tract, prostate, and male genitalia. In *Pathology*. Edited by W.A.D. Anderson, St. Louis: The C.V. Mosby Co., chapt. 22, pp. 836 and 840, 1970
- 9) Stamey TA and Condy M: The effusion and concentration of trimethoprim in human vaginal fluid. *J Infect Dis* 131: 261, 1975

(Accepted for publication, July 11, 1984)

和文抄録

反復性女子膀胱炎患者に認められた膀胱三角部の扁平上皮化生について

旭中央病院泌尿器科

村 上 信 乃

五 十 嵐 辰 男

高 原 正 信

山 西 友 典

千葉大学医学部泌尿器科学教室

島 崎 淳

信州大学医学部病理学教室

重 松 秀 一

膀胱鏡にて膀胱三角部に白斑を示した44例の反復性膀胱炎の女子の同部生検をおこない、以下の結果を得た。

- 1) 組織学的に白斑部の上皮はさまざまな Grade の扁平上皮化生を示し、粘膜下は線維化傾向を示した。
- 2) 頻回な膀胱炎症状既往を有する例ほど、扁平上皮化生と線維化傾向の Grade が高かった。
- 3) 軽症から中等度の扁平上皮化生を示した群では

尿道部細菌を認めたが、重症な扁平上皮化生を示した群では尿道部細菌を認めなかった。

- 4) 以上よりみて、尿道部細菌は扁平上皮化生の発生や初期の進展のひとつの要因と見做しうるが、一層進展した重症の扁平上皮化生は、同部細菌とは無関係に、単に頻回な症状のくり返しのみで生じうるものが推測される。