

Title	Radical surgery with myocutaneous flap for advanced penile carcinoma: case report
Author(s)	IWATA, Shinji; OGAWA, Yoshihide; SAKAMOTO, Yoshiro; KAWACHI, Yoshio; TAKAHASHI, Shigeki; KITAGAWA, Ryuichi
Citation	泌尿器科紀要 (1984), 30(12): 1873-1878
Issue Date	1984-12
URL	http://hdl.handle.net/2433/118349
Right	
Type	Departmental Bulletin Paper
Textversion	publisher

RADICAL SURGERY WITH MYOCUTANEOUS FLAP FOR ADVANCED PENILE CARCINOMA: CASE REPORT

Shinji IWATA, Yoshihide OGAWA, Yoshiro SAKAMOTO,
Yoshio KAWACHI, Shigeki TAKAHASHI and Ryuichi KITAGAWA

*From the Department of Urology, School of Medicine, Juntendo University
(Director: Prof. R. Kitagawa)*

A 55-year-old male with penile epidermoid carcinoma of stage C ($T_3N_3N_0$) underwent radical surgery. Emasculation with profuse skin removal, including the bilateral groins, and inguinal and pelvic lymphadenectomy were performed. A urethrostomy was created at the perineum, and the skin defect was covered with tensor fascia lata myocutaneous skin flaps. Immediately after recovery from surgery, 3 cycles of chemotherapy with cyclophosphamide, adriamycin and CDDP and radiation (5,000 rad) of the local area were given. The patient is now free from tumor recurrence 12 months after the surgery.

Key words: Penile cancer, TFL myocutaneous flap, Multimodal therapy

INTRODUCTION

Penile carcinoma has been reported to constitute approximately 0.193% of all urinary tract diseases in males and 4.49% of all malignant urinary tract tumors in Japan¹⁾. Because of personal neglect, a sense of shame, and ignorance, it is natural that patients with penile carcinoma delay visiting a hospital and typically show up in a rather advanced stage. After the introduction of bleomycin and the recent experimental use of high-dose methotrexate^{2,3)}, palliative therapy has been the mainstay of treatment for patients with penile carcinoma and also even for more advanced cases. The *en bloc* excision of the local skin lesions, as was originally described by Young, can be done and individualized for advanced presentations. Until the advent of musculocutaneous flaps, the surgical wounds which were the result of radical surgery were impossible to close satisfactorily. Now, however, the turning of musculocutaneous flaps into the defect provides a clean, rapidly healing wound covering⁴⁻⁶⁾. It has generally been accepted that even radical surgery, with radiation and chemo-

therapy, fails to control advanced diseases. However, some of the present authors and their associates have previously reported that radical surgery using musculocutaneous skin flaps, followed by high-dose methotrexate, seemed effective in one of the four cases of penile carcinoma of stage C with the patient surviving for more than 4 years⁴⁾. Following this, Kakizoe and his associates also reported a similar experience. Until more suitable means are available, radical surgery, followed by chemotherapy and radiotherapy, as described herein, affords the best opportunity to control the tumor locally and to prevent further morbidity and wound-care problems.

Herein, we want to introduce a case of stage C penile carcinoma. This patient underwent radical surgery using musculocutaneous skin flaps and was then treated with chemotherapy and radiation therapy.

CASE REPORT

A 55-year-old man presented himself at our outpatient clinic in February, 1983, with a 7-month history of a penile skin lesion. The patient had first noticed an itchy skin eruption on the phimotic prepuce in July,

1982. He had also found a chestnut-sized mass in the left groin in October, 1982. On admission, a penile tumor was felt in the prepuce, as well as bilateral inguinal lymphnodes. Circumcision was performed, followed by a biopsy of the penile tumor and an aspiration biopsy of the inguinal lymphnode (Fig.1). Histology showed well-differentiated epidermoid carcinoma, with metastasis to the inguinal lymphnode. Lymphangiography and CT scan revealed positive lymphnode involvements up to the external iliac nodes. An IVP, a bone scan, and a liver scan were all negative. The patient underwent radical surgery to remove the lesion *en bloc*. Skin incision was made including bilateral groin masses, and dissec-

tion was carried down to the femoral vessels and to the area 15 cm below the inguinal ligamentum. The femoral vessels were free from tumor invasion. The penis was mobilized above the scrotum, and the suspensory ligamentum was divided, and the intrascrotal organs were also removed after the crura had been divided. The *en bloc* mass included the penis, the intrascrotal organs, enlarged inguinal lymphnodes, and the lower abdominal skin (Fig.2). After the inguinal canal had been opened and the rectus sheath had been divided near the pubic symphysis, the retroperitoneum cavity was entered. Pelvic lymphadenectomy was carried out in the usual manner up to the paraaortic nodes, which proved to be nega-

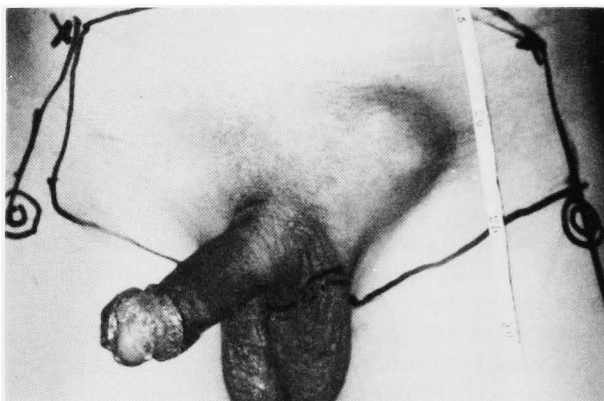


Fig. 1. Gross appearance of the external genitalia soon after circumcision and biopsy of the tumor. A penile tumor was observed on the prepuce skin, and it invaded the glans penis. A couple of chestnut-sized lymphnodes were seen in the groin.

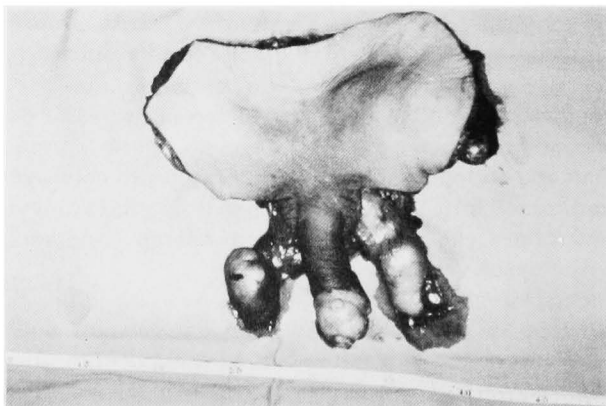


Fig. 2. Surgically removed specimen including the penis, the intrascrotal organs, enlarged lymphnodes, and the lower abdominal skin.

tive microscopically (Fig.3). Upon the completion of the lymphnode dissection, the rectus sheath was approximated to the pubic symphysis. The proximal stump of the penis was transposed to the perineum and brought out through the newly fashioned

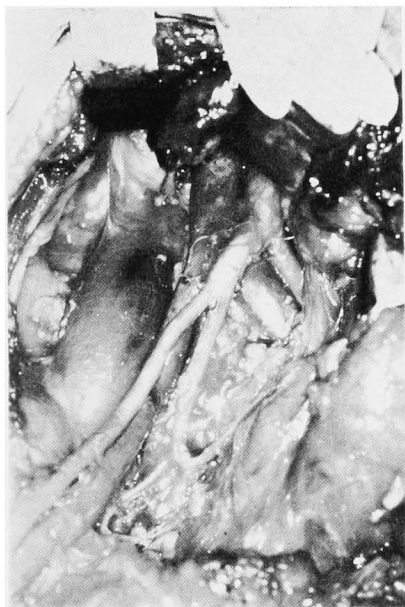

Fig. 3. Gross appearance of the pelvic cavity upon the completion of pelvic lymphadenectomy. Lymphnodes and fatty tissues along the iliac vessels were dissected above the level of aortic bifurcation.

tunnel. Perineal urethrotomy was completed, and a Foley catheter was inserted. The sartorius muscle was divided at the iliac spine, mobilized medially to lie over the femoral vessel, and then sutured to the neighboring structures (Fig.4). Bilateral tensor fascia lata myocutaneous flaps (10×25 cm) were elevated and used to cover the skin defect in a crossing fashion. The skin defect where the TFL flaps were raised was closed with a split-thickness skin graft from the anterior surface of the legs (Fig.5). Because a subcutaneous abscess and necrosis of the distal portion of the flap then developed, debridement and coverage of the area with a full-thickness skin graft were performed 3 weeks after surgery (Fig.6). Two weeks after that, chemotherapy with peplo-mycin (5 mg/day) was started; the total dose reached 100 mg. Three courses of the chemotherapy regimen by Yagoda were followed by radiation therapy, in which the total dose to the pelvic area was 5,000 rad (Fig.7). The third course of the regimen was suspended by a complication of sepsis due to an urinary-tract infection. Otherwise, the clinical course was uneventful. The patient has been followed up for 12 months, with no evidence of tumor recurrence.

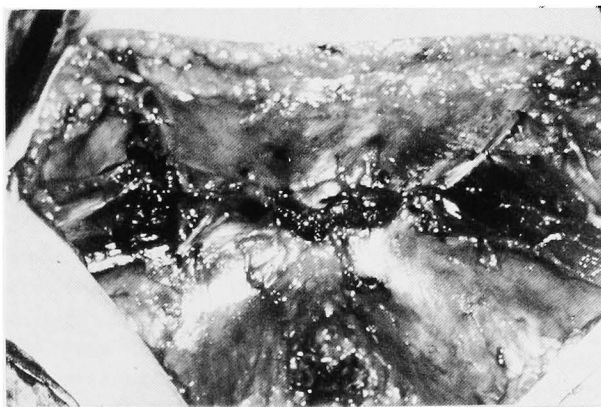


Fig. 4. Gross appearance of the *en bloc*-removed area after lymphnode dissection. The abdominal muscles were sutured to the symphysis pubis. The sartorius muscles were divided from the iliac spine and sutured to the inguinal ligament in order to cover the femoral vessels.

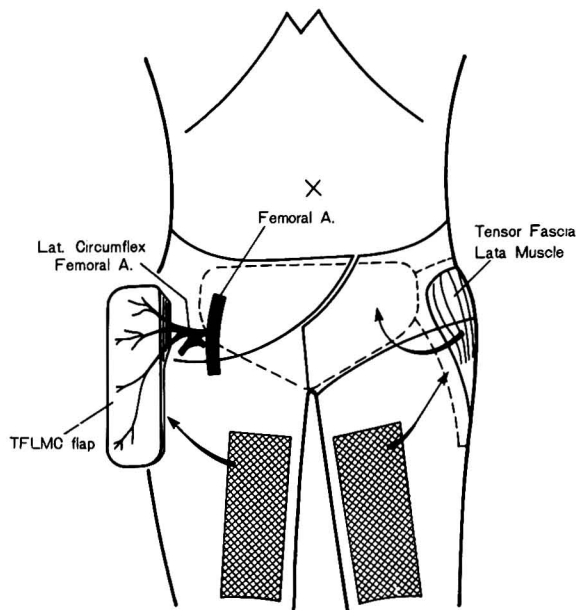


Fig. 5. Schematic representation of the mobilization of the tensor fascia lata myocutaneous skin flap (TFLMC) and the covering of the skin defect by means of thin-split skin grafts.

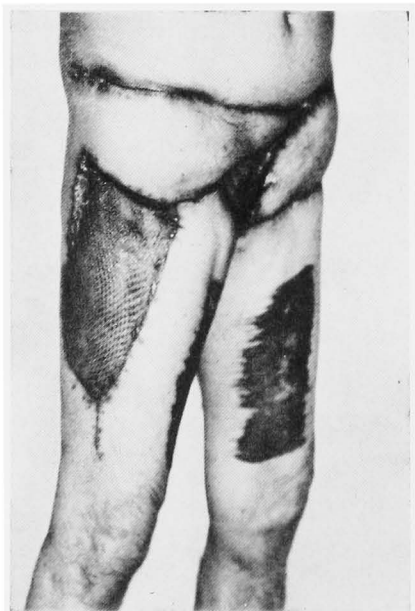

Fig. 6. Gross appearance of the surgically repaired area by means of a myocutaneous skin flap. Photograph taken at the time of discharge.

DISCUSSION

Penile carcinoma may metastasize to the regional femoral and inguinal lymph-

nodes, the area of which may sometimes become ulcerated, infected, and necrotic. Treating a patient with stage C penile carcinoma is thus a challenging problem. Staging lymphadenectomy with reduction surgery for a local tumor may be beneficial when followed by aggressive chemotherapy and radiotherapy for the purpose of eradicating any microscopic remnant tumor. It is also generally accepted that patients with paraaortic metastatic adenopathy cannot be saved and that therapeutic nodal dissection should include inguinal and pelvic nodes to the level of the aortic bifurcation. It has, however, not yet been definitely determined whether or not the lymphadenectomy is therapeutic. Extensive experience with the tensor fascia lata (TFL) musculocutaneous skin flap and gracilis muscle flap has enabled groin coverage and abdominal-wall reconstruction. According to the previous experience of some of the present authors and their associates, the complications after surgery were minimal (slight walking disturbance and leg edema); this makes possible the early intervention of chemotherapy and radiation after surgery. Methotrexate has been reported to be an active agent in the

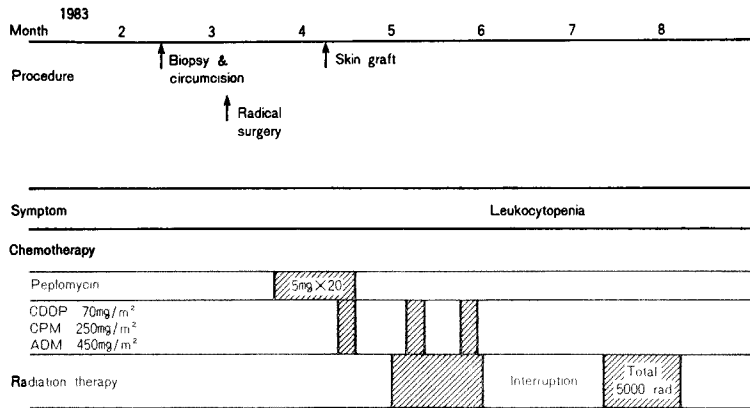


Fig. 7. Clinical course from admission to discharge. After the radical surgery, chemotherapy and radiation therapy were done.

treatment of advanced penile cancer. One of the previously reported cases is still alive more than 4 years after radical surgery with high-dose methotrexate. However, high-dose methotrexate is indicated only for bone sarcoma and choriocarcinoma in Japan. Therefore, a chemotherapeutic regimen by Yagoda was used in this particular case immediately after surgical recovery, as cis-diamminedichloride platinum (CDDP) has been reported to be an active agent for penile cancer. In conclusion, we wish to propose one example of multimodal treatment for stage C penile cancer; emusculatation with proper groin dissection as high as negative lymphnodes are identified should be performed, and appropriate chemotherapy with or without radiation should be done as soon as possible.

ACKNOWLEDGEMENTS

We wish to acknowledge the expert surgical skill in creating the myocutaneous skin flap and the invaluable advice of Drs. I. Tange, T. Ishida and Y. Bando (Department of Plastic Surgery, Juntendo University School of Medicine).

REFERENCES

- 1) Akasaka H, Imamura K, Nakanishi K, Maruyama Y, Suga T, Kondo T, Nakagawa C and Kai Y: Report of seven cases of penile cancer, with its statistical study. *Jpn J Urol* 57: 291~304, 1966
- 2) Mills EED: Intermittent intravenous methotrexate in the treatment of advanced epidermoid carcinoma. *S Afr Med J* 16: 398~404, 1972
- 3) Sklaroff RB and Yagoda A: Methotrexate in the treatment of penile carcinoma. *Cancer* 45: 214~216, 1980
- 4) Ishikawa S, Nemoto S, Umeyama T, Yazaki T, Kanoh S, Takahashi S, Ogawa Y and Kitagawa R: Tensor fascia lata myocutaneous flap for coverage of skin defect after extensive resection for penile cancer. *Jpn J Urol* 74: 1113~1121, 1983
- 5) Nakayama Y, Soeda S, Kasai Y, Kitagawa R and Ogawa Y: Reconstruction after the surgical removal of malignant lesions in the groin and perineum. *Plast Surgery (Japanese)* 24: 1075~1079, 1980
- 6) Nahai F, Hill HL and Hester T R: Experience with the tensor fascia lata flap. *Plast Rec Surg* 63: 788~799, 1979
- 7) Kakizoe T, Fujita J, Murase T and Matsumoto K: Local recurrence of penile carcinoma treated by extensive local resection and bilateral tensor fascia lata myocutaneous flap: A case report. *Jpn J Urol* 30: 1075~1079, 1980
(Accepted for publication May 10, 1984)

和文抄録

根治術施行後の組織欠損部の修復に筋肉皮弁を用いた進行性陰茎癌の1症例

順天堂大学医学部泌尿器科学教室

岩田 真二・小川 由英・坂本 善郎

川地 義雄・高橋 茂喜・北川 龍一

55歳男性に発症した陰茎扁平上皮癌 Stage C (T₃N₃M₀) に対し根治的手術を施行した。鼠径部を含めた広範な皮膚切除および全除精術を施行し、鼠径部および骨盤内リンパ節廓清もおこなった。会陰部に尿道瘻を造設し、両側大腿筋膜張筋筋肉皮弁を作製しこれを用い皮膚欠損部の再建術を施行した。術直後より

ペプロマイシン単独投与しその後サイクロフォスファミド、アドリアシン、シスプラチンを用いた多剤併用化学療法を3コース施行、同時に骨盤部に対し総線量 5,000 rad の放射線療法をおこなった。術後12か月を経過した現在、再発転移を認めず、歩行起立障害も軽度となり外来通院中である。