

Title	Inverted papilloma of the urinary bladder: report of two cases
Author(s)	GOTOH, Momokazu; TSAI, Shaomo; MURASE, Tatsuro; MITSUYA, Hideo
Citation	泌尿器科紀要 (1984), 30(11): 1645-1650
Issue Date	1984-11
URL	http://hdl.handle.net/2433/118325
Right	
Type	Departmental Bulletin Paper
Textversion	publisher

INVERTED PAPILLOMA OF THE URINARY BLADDER. REPORT OF TWO CASES

Momokazu GOTOH, Shaomo TSAI,

Tatsuro MURASE and Hideo MITSUYA

From the Department of Urology, Nagoya University School of Medicine

(Director: Prof. H. Mitsuya)

Two cases of inverted papilloma of the urinary bladder are reported. The patients were a 39-year-old male with macrohematuria and a 36-year-old female with interrupted urination. In both of the patients, tumors were resected transurethrally, and histologic examination revealed them to be typical inverted papilloma.

Key words: Inverted papilloma, Urinary bladder

INTRODUCTION

Inverted papilloma is a rare polypoid lesion which histologically shows downward proliferation of epithelial cords deep into the core. Since the first description by Potts and Hirst¹⁾ in 1963, about 130 cases have been reported; and, especially in Japan, to our knowledge, less than 20 cases have been recorded in the literature^{2,3)} Although the majority of the lesions described to date have been localized in the bladder and prostatic urethra²⁾, in few cases have they been found in the ureter and renal pelvis^{4,5)} Many investigators have underlined the benign behavior of these lesions based upon their histological appearance which lacks nuclear atypia and mitosis. Recently, however, several authors have mentioned the recurrent and malignant potential of these tumors. We report herein two cases of inverted papilloma found in the urinary bladder.

CASE REPORT

Case 1: A 39-year-old man was referred to us for macrohematuria in April, 1975. Although he had had an episode of macrohematuria and was diagnosed as having polypoid lesions in the urinary bladder in August, 1973, he did not return for treatment and follow up of the lesions for two

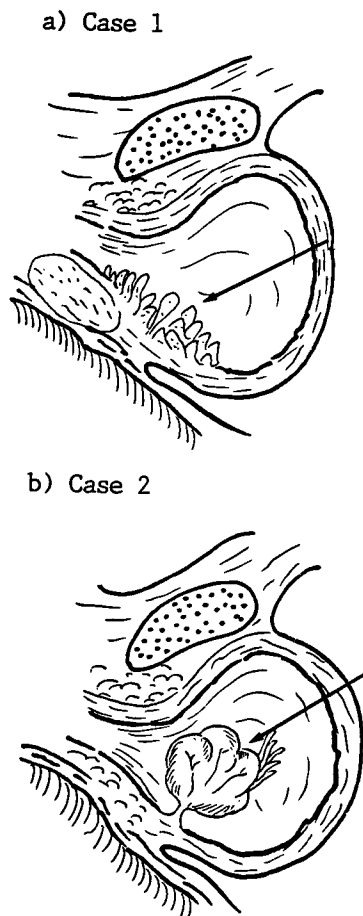


Fig. 1. The inverted papilloma occurring in the urinary bladder.

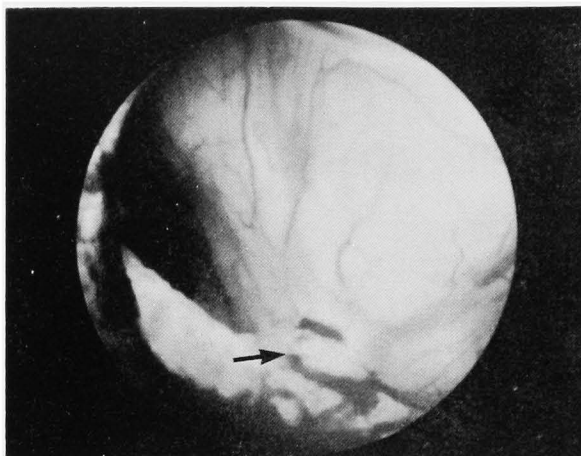


Fig. 2. Cystoscopic finding of the inverted papilloma (case 2). The tumor surface was smooth and appeared to be rich in capillaries. In the middle of the trigone, a fine peduncle was observed (arrow).

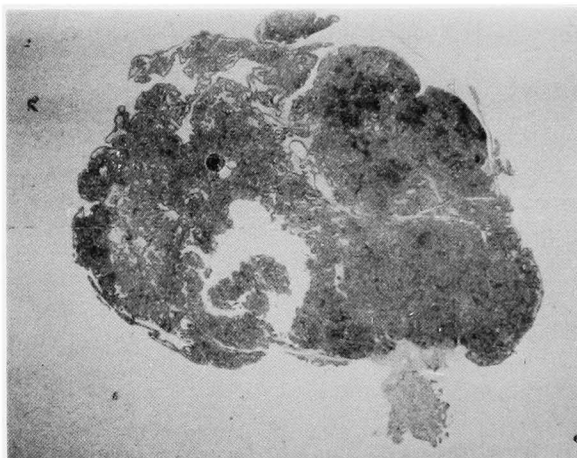


Fig. 3. Cross section of the whole tumor (case 2).

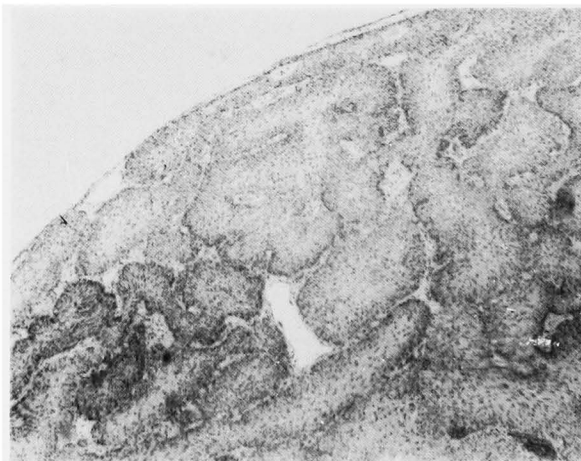

Fig. 4. Characteristic histologic pattern of inverted papilloma, consisting of ramifying and anastomosing cords of urothelial cells, the surface covered with smooth and normal transitional cell epithelium (case 2).

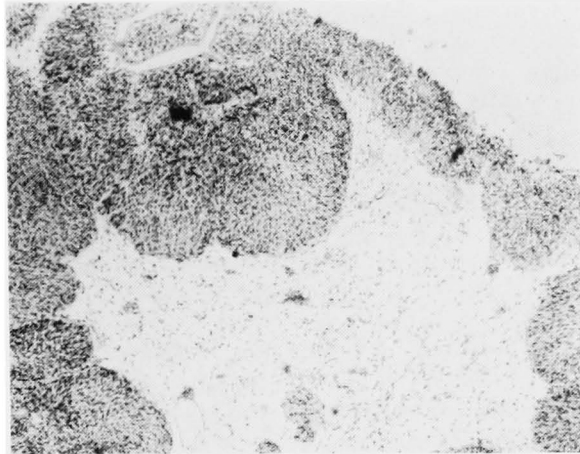


Fig. 5. Inverted papilloma exhibiting bud-like proliferations and strands of urothelial cells (case 1).

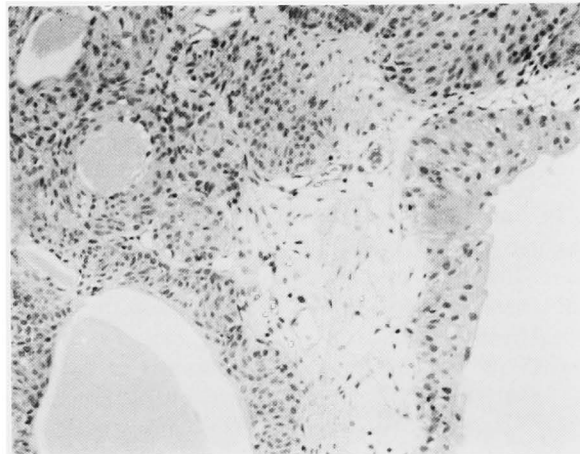


Fig. 6. Microcysts containing eosinophilic materials were often observed (case 1).

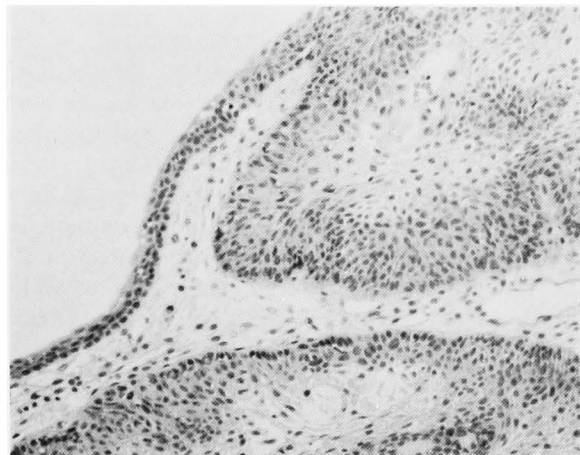


Fig. 7. The tumor surface was covered with transitional cell epithelium of normal thickness without hyperplasia or dysplasia, and the proliferated epithelial cords lacked nuclear atypia and mitosis (case 1).

years before his consultation to us. Macrohematuria was observed, but other laboratory evaluation including complete blood count, electrocardiogram, chest X-ray films and intravenous pyelogram were all within normal ranges. Cystoscopically, various sizes of multiple polypoid tumors with rather smooth surface were observed in the prostatic urethra and the trigonal area of the bladder (Fig. 1a). The tumors were completely resected transurethrally in July, 1975. After the operation, no recurrent lesion has been noted throughout his follow up.

Case 2: A 36-year-old woman was seen in November, 1982 for difficult urination, in particular for interrupted urination. She had been suffering from dysuria and occasional episodes of interrupted urination, having been treated for cystitis before she consulted our hospital. She had no episode of macrohematuria. Cystoscopic examination revealed a pedunculated tumor with smooth and lobulated surface in the middle of the trigone (Fig. 1b). The tumor appeared to be rich in small capillaries, and the peduncle was fine connecting the tumor mass with the bladder mucosa (Fig. 2). The tumor was located just covering the internal urethral orifice, and appeared to be the cause of the outflow obstructive symptoms. On admission, all clinical data including complete blood count, urinalysis, electrocardiogram, chest X-ray films, intravenous pyelogram and cystometrogram were normal. Repeated urine cytology was all negative. The tumor was resected as a solitary mass transurethrally, by cutting off the peduncle including the bladder wall around it. The resected tumor was measured to be $2 \times 2 \times 1.5$ cm in size. After the resection of the tumor, the patient has been completely free from urinary symptoms and recurrent tumors.

Histological examination revealed the tumors of both cases to be typical inverted papilloma. The tumor surface was covered with transitional cell epithelium of normal thickness without hyperplasia or dysplasia (Fig. 3~7). Under this layer, the epithelial cords were inverted and exhibited downward growth deep into the body of the lesion (Fig. 4, 5). Mature transitional

cells were arranged in papillary structures and anastomosing cords, frequently forming microcysts with eosinophilic materials (Fig. 6). In both cases, mitotic figures or infiltrating features were not seen (Fig. 7), and areas showing squamous metaplasia were not observed. The background was composed of delicate fibroconnective tissue stroma.

DISCUSSION

Inverted papilloma is a relatively rare tumor of the urinary tract, which is now recognized as an independent entity. This type of lesion was first described in detail in 1927 by Paschkis⁶⁾ as an adenoma-like polyp or adenoma of the urinary bladder, and designated in 1963 by Potts and Hirst¹⁾ as inverted papilloma. Since then, about 130 cases have been reported in the literature, and in Japan, to the best of our knowledge, less than 20 cases have been recorded^{2,3)}.

Recently, Kunze et al²⁾ (1983) summarized the clinical and histological aspects of the previously reported cases (about 110 cases) in the literature, and Nakao³⁾ (1982) discussed on the 19 cases recorded in Japan. These tumors were found predominantly in patients in their forties to sixties (8~85 years old). Occurrence predominated in males with a male-to-female ratio of 7 : 1. Although in the majority of the reported cases lesions were localized in the bladder and prostatic urethra, several lesions have been reported in the ureter and renal pelvis^{4,5)}. In the bladder, more than 90% of the lesion were found in the trigone and bladder neck, showing that the localization of the inverted papilloma was somewhat different from ordinary urothelial tumors. The most common initial symptoms were macrohematuria and urinary outflow obstruction, both of which were found in the present cases. Other symptoms included sense of residual urine and miction pain, etc. In case 2, dysuria and interrupted urination might have been caused by the freely moving large tumor mass covering and obstructing the bladder neck.

Histologically, inverted papilloma is characterized by endophytic growth of

urothelial cords deep into the core, the surface covered with smooth and normal urothelial layer. In addition, frequent occurrence of microcysts and squamous metaplasia has been noted. Kunze et al²⁾ (1983) classified inverted papilloma into two basic types based upon their histological characteristics, "trabecular type" and "glandular type" Inverted papilloma of trabecular type consisted of irregularly ramifying, intimately anastomosing cords, columns or sheets of urothelial cells which arised directly form the overlying transitional epithelium. They suggested that inverted papilloma of the trabecular type arised from proliferation of the basal cells of the urothelium. On the other hand, inverted papilloma of grandular type was characterized by multiple round to oval solid islands of proliferated urothelial cells together with pseudoglandular and true glandular structures. Interestingly enough, they speculated that inverted papilloma of glandular type would develop from von Brund's cell nest, based on the histological resemblance between them, and that this type of lesion would be a potentially preneoplastic lesion. According to this classification, the lesions presented in this study are considered to be long to the trabecular type.

Inverted papilloma has been considered to be completely benign based upon its histological features, low incidence of local recurrence and lack of invasive growth and metastasis^{1,4~7)}. The generally accepted benign behavior of these lesions indicates that transurethral resection would be an appropriate treatment. However, in spite of the vast majority of reports showing that inverted papilloma has a benign nature, a few reports have recently given doubt about this conception. Kameron and Lupton⁸⁾

(1976) described local recurrence after initial transurethral resection of these lesions, and Lazarevic and Garret⁹⁾ (1978) reported suspicious malignant papillary transformation of an inverted papilloma of the urinary bladder. Although the probability of such recurrence or malignant transformation is still believed to be considerably lower than that of exophytic papillomas, stress should be made that prolonged follow up is necessary for assessment of the biological behavior of these tumors.

REFERENCES

- 1) Potts I and Hirst E: Inverted papilloma of the urinary bladder. *J Urol* **90**: 175~179, 1963
- 2) Kunze E, Schauer A and Schmitt M: Histology and histogenesis of two different types of inverted urothelial papillomas. *Cancer* **51**: 348~358, 1983
- 3) Nakao M, Mishina T, Miyakoda K, Araki H, Fujiwara T, Kobayashi T and Maegawa M: An inverted papilloma of the urinary bladder; report of a case. *Acta Urol Jpn* **28**: 213~217 1982
- 4) Geisler C, Mori K and Leiter E: Lobulated inverted papilloma of the ureter. *J Urol* **123**: 270~271, 1980
- 5) Assor D: Inverted papilloma of the renal pelvis. *J Urol* **116**: 654, 1976
- 6) Paschkis R: Uber Adenome der Harnblase. *Z Urol Chir* **21**: 315~325, 1927
- 7) Matz LR, Wishart VA and Goodman MA: Inverted urothelial papilloma. *Pathology* **6**: 37~44, 1976
- 8) Cameron KM and Lupton CH: Inverted papilloma of the lower urinary tract. *Brit J Urol* **48**: 567~577, 1976
- 9) Lazarevic B and Garret R: Inverted papilloma and papillary transitional cell carcinoma of urinary bladder; report of few cases of inverted papilloma, one showing papillary malignant transformation and review of the literature. *Cancer* **42**: 1904~1911, 1978

(Accepted for publication April 17, 1984)

膀胱内 Inverted Papilloma の2例

名古屋大学医学部泌尿器科学教室（主任：三矢英輔教授）

後	藤	百	万
蔡		紹	謨
村	瀬	達	良
三	矢	英	輔

膀胱内に発生した Inverted Papilloma の2例を報告し、若干の文献的考察を加えた。患者はそれぞれ肉眼的血尿と尿線途絶を主訴とする39歳の男性と36歳

の女性であった。両症例とも膀胱内腫瘍は経尿道的に切除され、組織学的に典型的な Inverted Papilloma の所見を示した。