

Title	Severe hypertension and tachycardia associated with pancuronium bromide in a patient with asymptomatic pheochromocytoma
Author(s)	HIRANO, Shoji; UEKI, Osamu; MISAKI, Toshimitsu; HISAZUMI, Haruo; HAMATANI, Kazuo; MATSUBARA, Fujitsugu; MIWA, Umeo
Citation	泌尿器科紀要 (1984), 30(5): 709-713
Issue Date	1984-05
URL	http://hdl.handle.net/2433/118170
Right	
Type	Departmental Bulletin Paper
Textversion	publisher

SEVERE HYPERTENSION AND TACHYCARDIA ASSOCIATED WITH PANCURONIUM BROMIDE IN A PATIENT WITH ASYMPTOMATIC PHEOCHROMOCYTOMA

Shoji HIRANO, Osamu UEKI, Toshimitsu MISAKI and Haruo HISAZUMI

From the Department of Urology, School of Medicine, Kanazawa University

(Director: Prof. H. Hisazumi, M.D.)

KAZUO HAMATANI

From the Department of Anesthesiology, School of Medicine, Kanazawa University

Fujitsugu MATSUBARA

From the Department of Central Clinical Laboratory, Kanazawa University Hospital

Umeo MIWA

From the Department of Internal Medicine, Ishikawa Prefectural Central Hospital

We present a case of asymptomatic pheochromocytoma with severe hypertension and tachycardia evoked by the administration of pancuronium bromide, a nondepolarizing muscle relaxant which has been used commonly in the anesthetic management of patients with pheochromocytoma.

Key words: Pheochromocytoma, Pancuronium bromide, Hypertension

INTRODUCTION

Pancuronium bromide has been recommended as a safe and effective muscle relaxant for patients with pheochromocytoma. However, it has been said to release catecholamines from the adrenergic nerve endings, and to block the re-uptake of noradrenaline by the adrenergic nerve endings as well. Thus, this drug may cause striking hypertension and tachycardia during anesthesia or surgical intervention for pheochromocytoma. We describe a case of an asymptomatic pheochromocytoma associated with severe hypertension and tachycardia following pancuronium bromide administration.

CASE REPORT

A 33-year-old man had been followed for an asymptomatic and nonfunctioning adrenal tumor at a medical service of a

certain university hospital since November of 1981. However, the patient was afraid of malignancy, and the possibility of a malignant adrenal tumor could not be excluded after further examinations at the medical service of Ishikawa Prefectural Central Hospital. He was then referred to and admitted at our Urology Clinic for an operation on July 1, 1982. There was no personal history of hypertension, palpitation, headache or sweating. The patient was well-nourished, 184 cm tall, 87 kg in weight; his temperature, respiration, pulse rate (72/min.) and blood pressure (120/90 mm.Hg.) were all normal. Laboratory studies revealed a normal electrolyte value, and normal liver and renal functions. Endocrinological studies of the blood revealed slight elevation of plasma renin activity to 2.4 ng/ml/h. (normal range, NR: 0.1~2.0) and of noradrenaline to 436 pg/ml (NR: 40 to

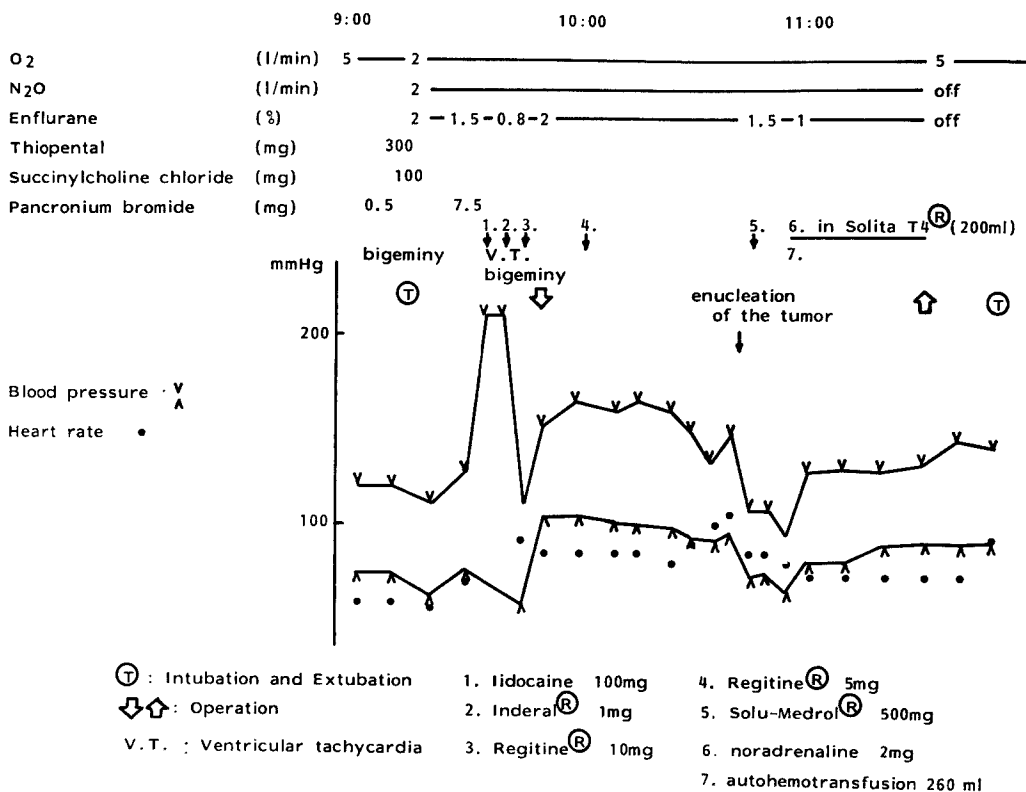


Fig. 1. Anesthesia record showing severe hypertension and tachycardia following an injection of pancuronium bromide

350). Endocrinologic studies of the urine revealed a slightly elevated level of nora-drenaline (192 mcg/day, NR: 10~90), dop-amine (730 mcg/day NR: 100~700), and vanillyl mandelic acid (15.8 mcg/day NR: 2~12). The functions of the thyroid, pancreatic islet cells, adrenal cortex and hypopituitary gland were within the normal ranges. An electrocardiogram and a chest plain film revealed no abnor-mality, and the circulating blood volume was also within normal limits. Computer-ized tomography unveiled a round mass in the left suprarenal fossa, which was depicted well after an intravenous injec-tion of contrast medium. On July 19, 1982, left adrenalectomy was performed under general anesthesia using enflurane-nitrous oxide-oxygen. *Anesthesia record* (Fig. 1). Just before anesthesia the blood pressure was 120/70 mmHg. and pulse rate was 68/min. Stable and sufficient anes-thesia was confirmed after the induction,

and thereafter 7.5 mg of pancuronium bromide was injected to obtain efficient muscle relaxation for the operation. Just after drug administration the blood pressure was markedly increased to the level of 220 mmHg. and ventricular tachycardia and bigeminal pulses ap-peared together. To treat these attacks, 100 mg lidocaine hydrochloride, 1 mg pro-pranol hydrochloride (Inderal®) and 10 mg phentolamine mesylate (Regitine®) were injected; the hypertensive attack and bigeminal pulse subsided. Blood pressure, in the operation, had been maintained between 140 and 160 mmHg without phentolamine mesylate but 0.5 mg of this drug at the start of the operation. *Surgery record.* The adrenal gland was approached through a left flank incision and dissected easily without any surrounding retroperitoneal tissue at-tached. The adrenal gland including the tumor weighed 33.6 g. *Microscopic appear-*

ance. Histological examination revealed a pheochromocytoma with no findings suggesting malignancy, that is capsular infiltration or mitosis. *Postoperative course.* Convalescence was uneventful and the noradrenaline values were normalized one month after the left adrenalectomy.

DISCUSSION

Pheochromocytoma is classified into 3 types consisting of sustained, paroxymal and asymptomatic types according to the clinical manifestations. Approximately 10 per cent of pheochromocytoma patients remain asymptomatic¹⁾, and several expressions such as "atypical", "nonfunctioning" and "masked" are used in place of "asymptomatic." Sakamoto and associates²⁾, found the same granules secreting catecholamines in an asymptomatic pheochromocytoma as those in a functioning pheochromocytoma, and confirmed Yamada's hypothesis³⁾ that a release of catecholamines into the blood circulation was not necessarily related to the amount of catecholamine production or storage. Concerning the pathophysiology, Yamada⁴⁾ found that in asymptomatic pheochromocytoma, the secreting granules were poorly launched from the tumor cells. On the other hand, Taubman and associates⁵⁾ reported a case of an asymptomatic catecholamine-secreting pheochromocytoma, and Ho and associates⁶⁾ described normotensive familial pheochromocytoma with predominant noradrenaline secretion. Satoh and associates⁷⁾ gave an account of decreased sensitivity to catecholamines for asymptomatic pheochromocytoma patients. Because no hypertensive attack occurred in our case even though the tumors had been removed without any special attention paid during the operation, it was assumed that the pheochromocytoma did not secrete catecholamines into the blood circulation, or that the patient were not so sensitive to the catecholamines even if they had been released from the tumor into the blood circulation during the operation. There is still a huge controversy over the patho-

genesis of hypertension in patients with pheochromocytoma.

Until now pancuronium bromide has not been known to cause histamine release and block the sympathetic ganglia⁸⁾. But, Jones and Hill⁹⁾ have described a case of pheochromocytoma showing severe hypertension and tachycardia associated with pancuronium bromide, and emphasized that pancuronium bromide has a catecholamine-releasing action and causes potentially life-threatening hypertension in the patient undergoing surgery for the removal of a pheochromocytoma. Pancuronium bromide has been considered to provoke short-lasting cardiovascular stimulation¹⁰⁾ and vagolytic action on the heart¹¹⁾ since both adrenaline and especially noradrenaline have been found to be augmented after pancuronium bromide administration¹²⁾. Dobkin and associates¹³⁾ also reported transient ventricular arrhythmia in 5 patients and Stoetling¹⁴⁾ reported premature ventricular contractions in 2 patients, after pancuronium bromide was administered in the anesthesia. Ivankovich and associates¹⁵⁾ and Domenech and associates¹⁶⁾ concluded that pharmacologically pancuronium bromide acts on the postganglionic nerve endings, causes release of catecholamines and inhibits the reuptake of noradrenaline by the adrenergic nerve endings. It was suspected that in our case the elevated catecholamine level in the blood circulation or at the sympathetic nerve endings, was evoked rapidly by an intravenous injection of more than a saturating dose of pancuronium bromide, which transiently was more than the amount required to cause secretion of catecholamine granules from the tumor or more than the amount causing sensitivity of the sympathetic nerve endings to catecholamines. We insist that the influence of nitrous oxide gas or enflurane was considered and we conclude that there was a causal relationship between pancuronium bromide, hypertension, tachycardia and pheochromocytoma, but we believe that pancuronium bromide administration was the most probable cause of the hyper-

tensive attack in our case. Thus sufficient attention should be paid when administering pancuronium bromide to patients with a pheochromocytoma.

REFERENCES

- 1) Ichikawa T, Nijima T, Kumamoto E, Hirose K, Kinoshita K, Isurugi K and Yokoyama M: Pheochromocytoma. Case report and review of the Japanese literature. *Clin Endocrin* **11**: 703~717, 1963
- 2) Sakamoto F, Kondo S, Takada H, Yamana M and Nakamura K: A case of atypical adrenal pheochromocytoma. *Jap J Clin Urol* **36**: 157~161, 1982
- 3) Yamada R: Pathophysiology and clinics of adrenal pheochromocytoma. *Surgery* **37**: 670~676, 1975
- 4) Yamada R: Pathogenesis of pheochromocytoma. *Blood & Vessel* **7**: 38~42, 1981
- 5) Taubman I, Peason DH and Anton AH: An asymptomatic catecholamine-secreting pheochromocytoma. *Amer J Med* **57**: 953~956, 1974
- 6) Ho AD, Feurle G, Gless KH and Brandeis WE: Normotensive familial pheochromocytoma with predominant noradrenaline secretion. *Brit Med J* **14**: 81~82, 1978
- 7) Satoh T, Ono I, Miura Y, Abe K and Yoshinaga K: Hypertension and catecholamine. Pheochromocytoma and essential hypertension. *Clinic all-around* **20**: 1233~1244, 1971
- 8) Amakata Y, Sumikawa K and Takase A: Pheochromocytoma and its anesthesia. *Jap J Anesth* **13**: 187~193, 1974
- 9) Jones RM and Hill AB: Severe hypertension associated with pancuronium in a patient with a pheochromocytoma. *Can Anesth Soc J* **28**: 394~396, 1981
- 10) Docherty JR and Mcgrath JC: Sympathomimetic effects of pancuronium bromide on the cardiovascular system of the pithed rat: a comparison with the effects of drugs blocking the neuronal uptake of noradrenaline. *Br J Pharmac* **64**: 589~599, 1978
- 11) Saxena PR and Bonta IL: Mechanism of selective cardiac vagolytic action of pancuronium bromide. Specific blockade of cardiac muscarinic receptors. *Eur J Pharmac* **11**: 332~341, 1970
- 12) Nana A, Cardar E and Margareta D: Blood catecholamine changes after pancuronium. *Acta Anaesth Scand* **17**: 83~87, 1973
- 13) Dobkin AB, Evers W, Ghanooni S, Levy AA and Thomas ET: Pancuronium Bromide (Pavulon®) evaluation of its clinical pharmacology. *Can Anesth Soc J* **18**: 512~535, 1971
- 14) Stoelting RK: The hemodynamic effects of pancuronium bromide and tubocurarine in anesthetized patients. *Anesthesiology* **36**: 612~615, 1972
- 15) Ivankovich AD, Miletich DJ, Albrecht RF and Zahed B: The effect of pancuronium on myocardial contraction and catecholamine metabolism. *J Pharm Pharmac* **27**: 837~841, 1975
- 16) Domenech JS, Garcia RC, Sasiain JMR, Loyola AQ and Oroz JS: Pancuronium bromide: An indirect sympathomimetic agent. *Brit J Anesth* **48**: 1143~1148, 1976

(Accepted for publication, December 6, 1983)

和文抄録

Pancuronium bromide にて高血圧および頻脈発作を
きたした無症候性褐色細胞腫の 1 例

金沢大学医学部泌尿器科学教室（主任：久住治男教授）

平野 章治・上木 修

三崎 俊光・久住 治男

金沢大学医学部麻酔科学教室

浜 谷 和 雄

金沢大学医学部附属病院中央検査部

松 原 藤 継

石川県立中央病院内科

三 輪 梅 夫

麻酔導入時の pancuronium bromide の投与により著明な高血圧および頻脈をきたした興味ある無症候性褐色細胞腫の 1 例を報告する。

症例は33歳男子で、主訴は左副腎腫瘍の精査、家族歴および既往歴に特記すべきことなし、右季肋下部不快感で某医で CT スキャンを受けたところ、左副腎腫瘍を指摘された。諸検査成績で尿中カテコラミンが軽度上昇する以外に異常はない。7月1日手術目的で入院し、同19日左副腎摘除術を受けた。エトレンおよび笑気で十分な全身麻酔をおこなった後、pancuronium 7.5 mg を筋弛緩を得るため投与したところ急激な血

圧上昇 (220 mmHg)、2 段脈、心室性頻脈を認めた。Lidocain[®]、Inderal[®]、Regitine[®] の投与にて症状は消失した。手術中に特記すべき血圧の変動は認められなかった。腫瘍の重さは 33.6 g で、組織所見は褐色細胞腫であった。

褐色細胞腫における高血圧の発症機序についてはいまだ不明な点が多い。交感神経刺激作用を有するとされる pancuronium bromide により高血圧症をきたしたことは本症の高血圧発症を考える上で興味深く、若干の文献的考察を加えた。