

Title	Vesicocolic fistula formed by "collision" tumor between transitional cell carcinoma of urinary bladder and adenocarcinoma of the sigmoid colon
Author(s)	Oda, Yoshinori; Hamami, Gaku; Umezu, Keiichi; Sugimoto, Masayuki; Yasumuro, Chozo; Fujii, Akio; Kamidono, Sadao; Ishigami, Joji
Citation	泌尿器科紀要 (1984), 30(1): 55-58
Issue Date	1984-01
URL	http://hdl.handle.net/2433/118093
Right	
Type	Departmental Bulletin Paper
Textversion	publisher

VESICOCOLIC FISTULA FORMED BY "COLLISION" TUMOR BETWEEN TRANSITIONAL CELL CARCINOMA OF URINARY BLADDER AND ADENOCARCINOMA OF THE SIGMOID COLON

Yoshinori ODA, Gaku HAMAMI, Keiichi UMEZU, Masayuki SUGIMOTO,
Chozo YASUMURO, Akio FUJII, Sadao KAMIDONO and Joji ISHIGAMI

*From the Department of Urology, Kobe University, School of Medicine
(Director: Prof. J. Ishigami)*

A patient with vesicosigmoid fistula due to "collision" tumor between adenocarcinoma of the sigmoid colon and transitional cell carcinoma of the urinary bladder is presented. Resection of the sigmoid colon and partial cystectomy were performed. The clinical symptoms, diagnostic procedures and treatments are discussed.

Key words: Collision tumor, Vesicocolic fistula, Bladder cancer, Sigmoid colon cancer

INTRODUCTION

Vesicocolic fistula, secondary to colic or bladder cancer is not a rare complication. But the fistula due to a "collision" tumor is extremely rare. Krausz¹⁾ reported previously on a vesicocolic fistula due to this collision tumor. To our knowledge, our case of a vesicocolic fistula due to "collision" between adenocarcinoma of the sigmoid colon and transitional cell carcinoma of the urinary bladder is the second case reported.

CASE REPORT

A 50-year-old male patient visited a clinic on April 7, 1981, with complaints of pollakisuria and macrohematuria. He was treated for cystitis. He revisited the same clinic on June 26, 1981, complaining of constipation and lower abdominal discomfort. On September 16, 1981, he was transferred to the Department of Urology Kobe University Hospital for a newly developed symptom of fecaluria. During this six-month period, he lost about 12 kg.

The physical examination was normal

except for a palpable childhead-sized, smooth and elastic hard mass in the lower abdomen. The patient's height was 158 cm and weight 58 kg.

Laboratory tests, revealed normal carcinoembryonic antigen, urinalysis showed hematuria and fecal material, and a urine culture yielded nothing.

Cystoscopy revealed a fistulous opening in the posterior wall of the bladder and fecal material was confirmed through the fistulous opening. A cystogram revealed this fistula and a contrast medium flowed into the sigmoid colon easily (Fig. 1). Barium enema showed stenosis of the sigmoid colon and the fistula, and then barium flowed into the bladder (Fig. 2). A CT scan of the lower abdomen showed deformity of the bladder and a tumor mass attached to the bladder (ca. 500 ml intralipid in the colon, ca. 100 ml olive oil in the bladder Fig. 3). Rectoscopy revealed a mass at about 35 cm from the anus, but no fistula was identified. The fistula due to sigmoid colon cancer was diagnosed preoperatively.

The operation was performed on October 15, 1981. The tumor at the sigmoid

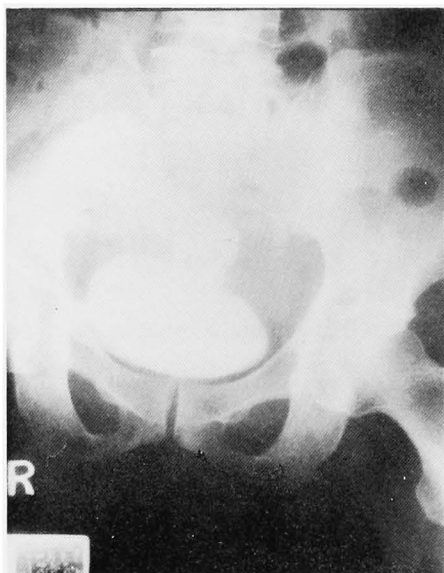


Fig. 1. Cystogram reveals the vesicocolic fistula

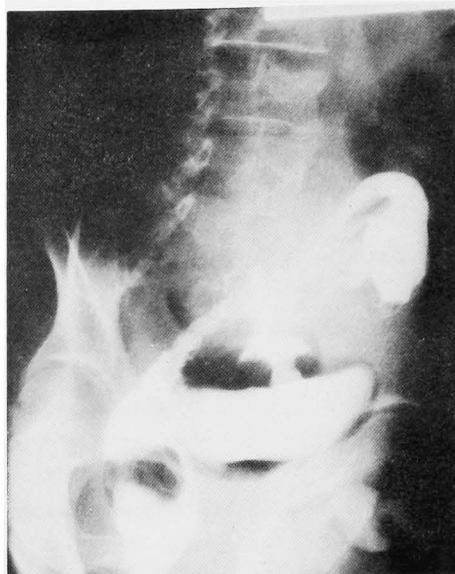


Fig. 2. Barium enema shows the stenosis of the sigmoid colon and the fistula

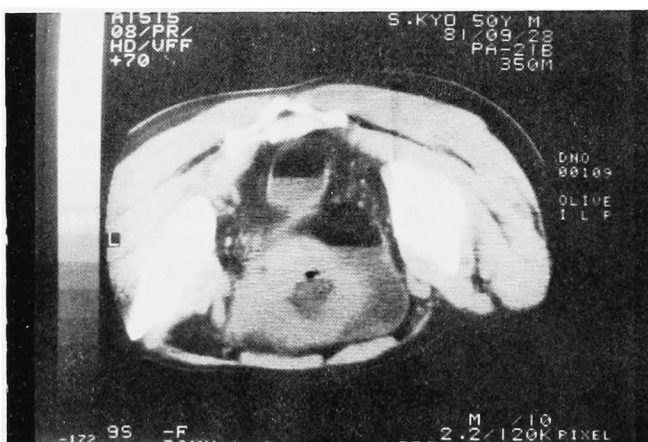


Fig. 3. CT scan shows abnormality of the bladder due to the tumor

colon and the fistula connected with the bladder were confirmed, and a frozen section revealed adenocarcinoma of the sigmoid colon and no metastasis to lymph nodes. Macroscopically, the bladder mucosa, except for the round fistulous opening, was almost normal. The tumor was resected with the sigmoid colon and partial cystectomy was performed. A microscopic examination after routine fixation and conventional staining of paraffin

sections revealed the vesicosigmoid fistula formed by "collision" between adenocarcinoma of the sigmoid colon and transitional cell carcinoma of the bladder (Fig. 4). The post-operative course was unevenful for about one year, but on October 1982, epigastralgia occurred. A CT scan revealed liver metastasis, while chest X-P lung showed metastasis. Although chemotherapy was performed, he died on May 7, 1983. A histology of the metastatic lesion

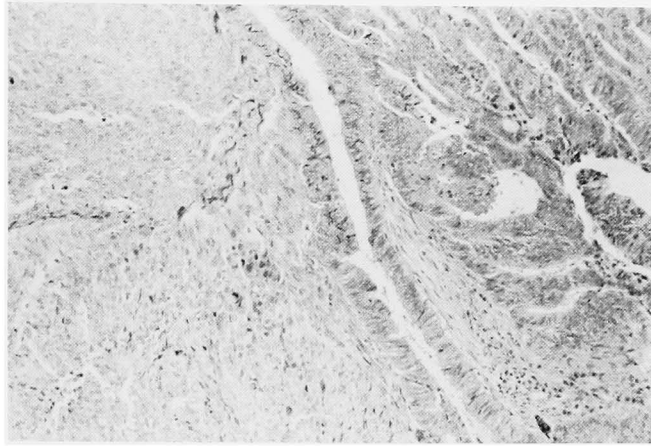


Fig. 4. Photomicrography of the fistulous tract demonstrates collision cancer. (left side: transitional cell carcinoma, right side: adenocarcinoma)

disclosed transitional cell carcinoma. Throughout the post-operative period, no recurrence of intravesical could be seen.

DISCUSSION

From the stand point of anatomical location, fistulous formation between gastrointestinal and urinary tract are mostly found between the bladder and sigmoid colon. It is less common in women probably because of the location of the uterus. Of the causes of vesicoenteric fistula, about 15% are traumatic, 35% neoplastic and 50% inflammatory in origin^{2,3}. The neoplastic invasion and added inflammatory reaction can produce ulceration and necrosis of colonic and vesical walls, resulting in a vesicocolic fistula of malignant origin^{1,4}. In Krausz's case, the vesicocolic fistulous tract was formed by inflamed granulation tissue¹, but in our case, histological examination revealed that the fistula had been formed by two colliding cancers.

The chief complaints of the fistula are pneumaturia and fecaluria. Many physicians consider these signs as pathognomonic, although pneumaturia may occur in the urinary tract by gas forming organisms or may follow bladder instrumentation. Fecaluria is of course pathognomonic. Pneumaturia was noted to occur at a relatively high rate in comparison

with fecaluria².

In this case, the fistula was observed by cystoscopy and confirmed with cystogram and barium enema. Cystoscopic examination is considered of value, but one rarely observes the actual fistulous opening because of the associated inflammatory changes and bullous opening due to inflammatory changes and bullous edema³. The diagnostic accuracy of the fistula found by cystogram and barium enema has never been high^{5,6}. The chief complaint and past history leading to pneumaturia and fecaluria are the key points for a correct diagnosis. A CT scan is useful for understanding bladder-intestinal tract location and cystoscopy; cystogram and barium enema may be of value for making a diagnosis.

However, Warren's⁷ report was based on multiple primary malignant tumors, while that of Meyer on a collision tumor. Generally, many authors agree that a "collision" tumor is contained in multiple primary malignant tumors.

In our case, the diagnosis before and during operation was a vesicocolic fistula due to colic cancer, but double cancer (adenocarcinoma of sigmoid colon, transitional cell carcinoma of urinary bladder) was found in the fistulous formation by postoperative investigation. Collision between adenocarcinoma of the sigmoid colon

and transitional cell carcinoma of the urinary bladder was confirmed in the fistulous tract. In the case of vesic sigmoid fistula due to malignant origin, the presence of a fistula indicates a progressive stage difficult to treat. When the cancer occurs in the sigmoid colon, the tumor along with sigmoid colon and regional lymph nodes should be resected. Partial or total cystectomy and urinary diversion may be necessary depending on the degree of invasion. In addition, pelvic exenteration may be necessary. In the case of cancer of bladder origin, total cystectomy, urinary diversion and regional lymph node dissection should be considered initially judging from the progression of the cancer. In our case, the pre-operative and operative diagnoses were sigmoid colon cancer. Therefore, only partial cystectomy was performed. But because transitional cell carcinomatous tissue was detected on the outside wall of the urinary bladder, such treatment might not have been entirely suitable.

A correct diagnosis using a frozen section during operation is of value in deciding the operative procedure, because of the possibility of multiple cancer.

REFERENCES

- 1) Krausz M, Manny J, Aviad I and Charuzi I: Vesicocolic fistula due to "collision" between adenocarcinoma of the colon and transitional cell carcinoma of the urinary bladder. *Cancer* **38**: 335~340, 1976
- 2) Couris GD and Block MA: Intestinovesical fistula. *Surgery* **54**: 736~742, 1963
- 3) Abeshouse BS, Robbins MA, Gann M and Salik JO: Intestinovesical fistulas. Report of seven cases and review of the literature. *JAMA* **164**: 251~257, 1957
- 4) Hughes ESR: Vesicocolic fistula. *Dis Colon Rectum* **3**: 103~112, 1960
- 5) Morse FP and Dretler SP: Diagnosis and treatment of colovesical fistula. *J Urol* **111**: 22~24, 1974
- 6) Shatila AH and Ackerman NB: Diagnosis and management of colovesical fistulas. *Surg Gynecol Obstet* **143**: 71~74, 1976
- 7) Warren S and Gates O: Multiple primary malignant tumors. A survey of the literature and a statistical study. *Am J Cancer* **16**: 1358~1414, 1932
- 8) Meyer R: Beitrag zur Verständigung über die Namengebung in der Geschwulstlehre. *Centrale f allg Path u path Anat* **30**: 291~296, 1919
- 9) Aldrete JS and Remine WH: Vesicocolic fistula. A complication of colonic cancer. *Arch Surg* **94**: 627~637, 1967

(Accepted for publication, July 5, 1983)

和文抄録

衝突型を呈した重複癌（膀胱腫瘍・S状結腸癌）により 形成された膀胱結腸瘻の1例

神戸大学医学部泌尿器科学教室（主任：石神襄次教授）

小田 芳 経・浜 見 学・梅 津 敬 一
杉 本 正 行・安 室 朝 三・藤 井 昭 男
守 殿 貞 夫・石 神 襄 次

膀胱腫瘍とS状結腸癌の衝突によって形成された膀胱結腸瘻を経験したので報告する。

患者は50歳男性、糞尿を主訴として1981年9月当科初診し、悪性腫瘍による膀胱S状結腸瘻の診断にて、同年10月膀胱部分切除、S状結腸切除術を施行した。術後の病理組織学的検索にて膀胱腫瘍とS状結腸癌の

衝突が認められた。術後約1年は著変なく経過したが、1982年10月肝転移が認められ、化学療法を施行するも効果なく1983年5月癌性悪液質にて死亡した。

膀胱腫瘍とS状結腸癌の衝突による膀胱結腸瘻はきわめてまれであり、われわれの調査したかぎりでは本邦第1例目と考えられる。