

Title	Lectin immunohistochemical evaluation of human bladder carcinomas. A comparison of Carnoy's and formalin fixation
Author(s)	Okamura, Takehiko; Ueda, Kousuke; Ohtaguro, Kazuo; Inoue, Kazuhiko; Washida, Hiroto; Mori, Masahiko; Tatemoto, Yukihiro; Fukushima, Shoji
Citation	泌尿器科紀要 (1993), 39(10): 899-905
Issue Date	1993-10
URL	http://hdl.handle.net/2433/117959
Right	
Type	Departmental Bulletin Paper
Textversion	publisher

LECTIN IMMUNOHISTOCHEMICAL EVALUATION OF HUMAN BLADDER CARCINOMAS A COMPARISON OF CARNOY'S AND FORMALIN FIXATION

Takehiko Okamura, Kousuke Ueda and Kazuo Ohtaguro
From the Department of Urology, Nagoya City University Medical School

Kazuhiko Inoue
From the Department of Urology, Toyokawa City Hospital

Hiroto Washida
From the Department of Urology, Anjo Kosei Hospital

Masahiko Mori
From the Department of Oral Surgery, Asahi University

Yukihiro Tatemoto
From the Department of Oral Surgery, Kochi Medical School

Shoji Fukushima
From the First Department of Pathology, Osaka City University Medical School

A lectin immunohistochemical analysis of 51 human bladder carcinomas, including 44 cases of transitional cell carcinoma (TCC) (G1, 15 cases; G2, 17 cases; G3, 12 cases) and 7 cases of squamous cell carcinoma (SCC), was performed. Tissues were obtained by cold punch biopsies, fixed in Carnoy's or 10% formalin solution, stained for binding of 10 different lectins, and evaluated under the light microscope. The lectins used were concanavalin agglutinin (Con A), soybean agglutinin (SBA), Lotus tetragonolobus agglutinin (LTA), Dolichos biflorus agglutinin (DBA), peanut agglutinin (PNA), Ricinus communis agglutinin I (RCA₁), Ulex europaeus agglutinin I, II (UEA-I, II), wheat germ agglutinin (WGA), and Pisum sativum agglutinin (PEA).

TCC prepared with Carnoy's fixation tended to show moderately positive Con A, UEA-I, and WGA reactions for G1, and strongly positive reactions for G2 and G3 lesions. UEA-II was mainly negative in G1, but tended to increase to become moderate in G3. DBA tended to show a moderately positive reaction in G1 and G2, but was mainly negative in G3. With formalin fixation, only RCA₁ demonstrated grade specific variation, tendency to react moderately in the G1 and G2 cases, and strongly in G3. There were no further differences among the histopathological grades of TCC for other lectins. Thus, Carnoy's fixation appears superior for distinguishing between grades of lesions. SCC tended to react more strongly than TCC with all the various lectins except PEA, independent of fixation.

(Acta Urol. Jpn. 39: 899-905, 1993)

Key words: Bladder cancers, Lectin immunohistochemistry, Carnoy's fixation

INTRODUCTION

Lectins, glycoproteins, found primarily in plants and in vertebrates, can recognize specific carbohydrates on cell surfaces¹⁾. Because of this feature, they have been widely used in investigations of changes in carbohydrate moieties between normal and

malignant states, and for grading various tissues, such as those of the alimentary tract²⁾, bronchial mucosa³⁾, uterus or ovary⁴⁾, thyroid gland⁵⁾, prostate^{6,7)}, and others^{8,9)}. Most previous studies were performed using formalin fixation, although a few investigators such as Walker¹⁰⁾ have pointed out the importance of the fixation

method. Several papers have in fact described different staining patterns obtained with the same lectins using different fixation methods^{3,6,11}.

Human bladder carcinomas have been investigated intensively using lectin immunohistochemistry because of difficulties in grading solely on the basis of histopathological findings. This is particularly important given the possibility of recurrence¹¹⁻¹⁴ and the associated high risk of invasion^{15,16}.

In the present study, we compared lectin binding patterns in carcinomas of the human bladder using two different methods of fixation, using Carnoy's and formalin solutions, to assess their relative merits.

MATERIALS AND METHODS

Materials

A total of 51 specimens of urinary bladder carcinoma, from 42 men and 9 women, age 30 to 87 years, were examined. All specimens were obtained by cold punch biopsies and fixed in either Carnoy's solution (100% ethanol: chloroform: glacial acetic acid=6:3:1) for 2 hours (31 specimens) or 10% formalin solution for 12 hours (20 specimens), then routinely embedded in paraffin. Serial paraffin sections measuring 4 μ m thick were cut and one stained with H&E for histopathological evaluation. The tumors consisted of 44 transitional cell carcinomas (G1, 15 cases; G2, 17 cases; and G3, 12 cases) and 7 squamous cell

Table 1. Histology and fixation of 51 bladder cancers

Fixation	TCC			SCC
	G1	G2	G3	
Formalin	6	5	3	6
Carnoy	9	12	9	1
Total	15	17	12	7

carcinomas as summarized in Table 1.

Histopathological classification of the bladder tumors was made according to the "General Rules for Clinical and Pathological Studies on Bladder Cancer".

Immunohistochemical methods

The lectins studied were ConA, SBA, LTA, DBA, PNA, RCA₁, UEA-I, UEA-II, WGA, and PEA. A key to these abbreviations is given in Table 2, where their origins and specificities are also specified. Deparaffinized sections were treated as follows (using the horseradish peroxidase conjugated lectin staining method^{17,18}):

- 1) Rinsed in phosphate buffered saline (PBS) for 10 min;
- 2) Immersed in 0.3% H₂O₂/methanol solution for 30 min;
- 3) Rinsed in PBS for 15 min;
- 4) Allowed to react with horseradish peroxidase-conjugated lectins for 30 min;
- 5) Rinsed in PBS for 5 min;
- 6) Immersed in 0.03% 3,3'-diaminobenzidine tetrahydrochloride/H₂O₂ solution for 10 min; and

Table 2. Lectins used in this study and their sugar specificities

Lectin	Abbreviation	Origin	Sugar specificity
Concanavalin A	Con A	Jack bean	α -D-Man, α -D-Glc
Glycine maximum	SBA	Soybean	D-GalNAc, D-Gal
Lotus tetragonolobus A	LTA	Asparagus pea	α -L-Fuc
Dolichos biflorus	DBA	Horse gram	α -D-GalNAc
Arachis hypogaea	PNA	Peanut	β -D-Gal (1-3)-D-GalNAc β -D-Gal
Ricinus communis	RCA ₁	Castor bean	β -D-Gal
Ulex europaeus agglutinin I	UEA-I	Gorse	L-Fuc
Ulex europaeus agglutinin II	UEA-II	Gorse	(D-GlcNAc) ₂
Triticum vulgare	WGA	Wheat germ	(D-GlcNAc) ₂ Sialic acid
Pisum sativum	PEA	Pea	D-Man, D-Glc

Table 3. Results for immunohistochemical staining of various lectins in human bladder cancers: Carnoy's fixation

Lectin	TCC																				SCC				
	G1					G2					G3														
	-*)	±	+	2+	Average	-	±	+	2+	Average	-	±	+	2+	Average	-	±	+	2+	Average					
Con A	0	2	5	2	+	0	0	5	7	2+	1	0	3	5	2+	0	0	0	1	2+					
UEA-I	0	3	4	2	+	0	3	2	7	2+	2	1	1	5	2+	0	0	0	1	2+					
WGA	0	4	5	0	+	0	0	5	7	2+	0	1	3	5	2+	0	0	0	1	2+					
UEA-II	6	2	1	0	-	0	7	5	0	±	0	3	5	1	+	0	0	0	1	2+					
PEA	1	2	5	1	+	0	4	5	3	+	0	5	3	1	±	1	0	0	0	-					
DBA	1	1	5	2	+	1	5	6	0	+	6	2	0	1	-	0	0	0	1	2+					
SBA	2	5	2	0	±	1	3	6	2	+	3	4	1	1	±	0	0	0	1	2+					
RCA ₁	1	4	3	1	±	0	2	6	4	+	1	5	2	1	±	0	0	0	1	2+					
LTA	8	1	0	0	-	11	1	0	0	-	7	2	0	0	-	0	0	1	0	+					
PNA	7	1	0	1	-	11	0	1	0	-	8	0	0	1	-	0	0	1	0	+					

*) -, negative; ±, weakly positive; +, moderately positive; 2+, strongly positive.

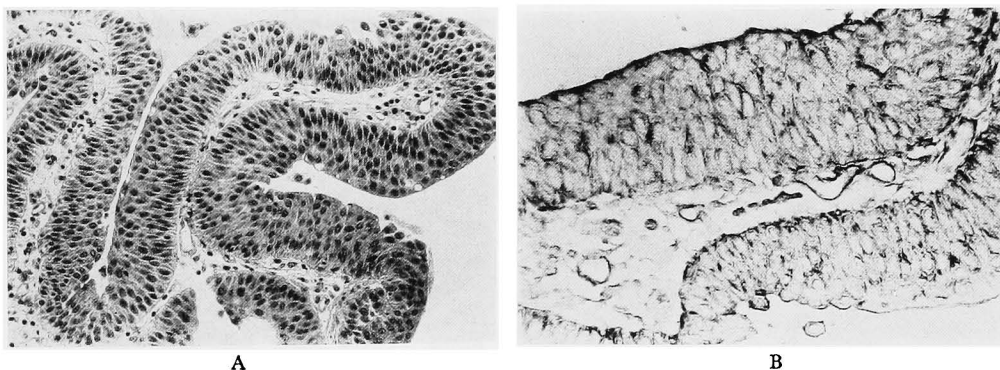


Fig. 1. Grade 1 transitional cell carcinoma of a human bladder (Carnoy's fixation). A: H.E. $\times 100$. B: Immunohistochemical staining with *Ulex europaeus* agglutinin I demonstrating a moderately positive reaction ($\times 200$)

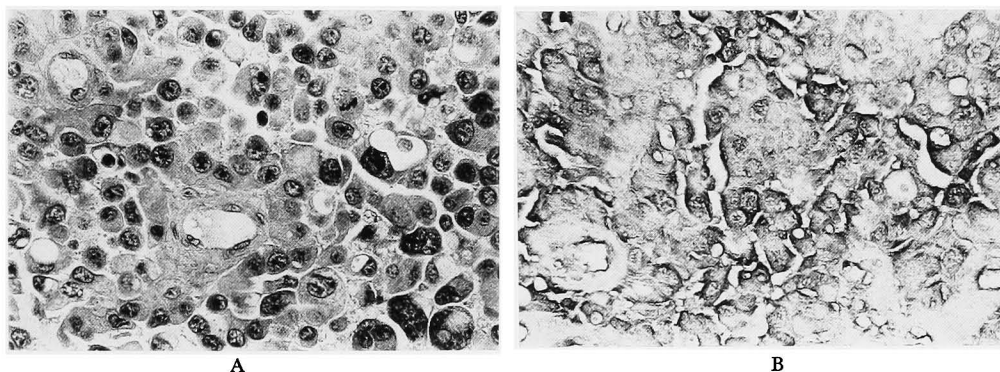


Fig. 2. Grade 3 transitional cell carcinoma of a human bladder (Carnoy's fixation). A: H.E. $\times 200$. B: Immunohistochemical staining with *Ulex europaeus* agglutinin I demonstrating a strongly positive reaction ($\times 200$)

7) Rinsed in PBS for 15 min.

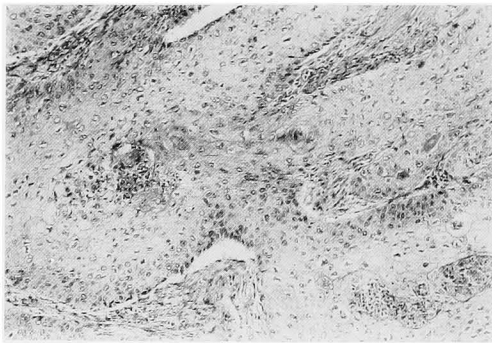
Tumor reactions were classified into four different categories; (-): negative, (±):

weakly positive, (+): moderately positive, (2+): strongly positive, and averaged over each grade. These grades were

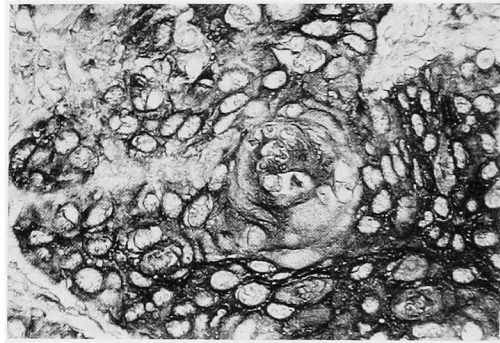
Table 4. Results for immunohistochemical staining of various lectins in human bladder cancers: formalin fixation

Lectin	TCC															SCC				
	G1					G2					G3					-	±	+	2+	Average
	-*)	±	+	2+	Average	-	±	+	2+	Average	-	±	+	2+	Average					
Con A	0	0	2	4	2+	0	0	2	3	2+	0	0	0	3	2+	0	0	2	4	2+
UEA-I	0	0	4	2	+	0	1	2	2	+	0	0	2	1	+	0	0	0	6	2+
WGA	0	6	0	0	±	0	5	0	0	±	0	2	1	0	±	0	0	2	4	2+
UEA-II	0	0	2	4	2+	0	1	1	3	2+	0	1	0	2	2+	0	0	3	3	2+
PEA	0	0	2	4	2+	0	0	2	3	2+	0	0	0	3	2+	5	0	1	0	-
DBA	0	4	2	0	±	0	4	1	0	±	0	3	0	0	±	0	0	3	3	2+
SBA	0	0	4	2	+	0	2	4	0	+	0	1	1	1	+	0	0	0	6	2+
RCA ₁	0	2	3	1	+	0	0	4	1	+	0	0	0	3	2+	0	0	4	2	+
LTA	1	4	1	0	±	0	5	0	0	±	0	2	1	0	±	4	1	1	0	-
PNA	0	1	3	2	+	0	1	4	1	+	1	0	2	0	+	0	0	3	3	2+

*) -, negative; ±, weakly positive; +, moderately positive; 2+, strongly positive.



A



B

Fig. 3. Squamous cell carcinoma of a human bladder (formalin fixation). A: H.E. $\times 40$. B: Immunohistochemical staining with *Ulex europaeus* agglutinin I demonstrating a strongly positive reaction ($\times 200$)

decided by staining intensity, not by the numbers of positive cells. For this purpose, cytoplasmic staining intensity, generally diffuse and uniform, was used, and nuclear or stromal reactions were ignored. To avoid the differences in the staining condition, all the materials were stained simultaneously for all lectins.

RESULTS

1. Carnoy's fixation (Table 3)

Transitional cell carcinoma (TCC): Both LTA and PNA gave average negative values in all grades of TCC. The other lectins demonstrated the tendency of differences in intensity between grades, with ConA, UEA-I, and WGA giving moderately positive reactions in G1 (Fig. 1), and

strongly positive reactions in G2 and G3 (Fig. 2). UEA-II was mainly negative in G1, but tended to increase the reactivity to moderate in G3. PEA and DBA tended to give a moderately positive reaction in G1 and G2, but mainly a weak or negative reaction in G3. SBA and RCA₁ tended to react either weakly or moderately in TCC.

Squamous cell carcinoma (SCC): PEA was negative in SCC, while LTA and PNA reacted moderately. All other lectins gave strongly positive reactions.

2. Formalin fixation (Table 4)

TCC: Almost all TCC gave positive reactions for TCC. WGA, DBA, and LTA had the tendency of weak reaction in all grades. UEA-I, SBA, PNA had the

tendency to react moderately, and ConA, UEA-II, and PEA tended to react strongly with all TCC. RCA₁ tended to show a moderately positive reaction in G1 and G2, and a strongly positive reaction in G3. Compared with Carnoy's fixation, lectin staining intensities did not vary between grades.

SCC: PEA and LTA were mainly negative for SCC, and RCA₁ tended to show a moderately positive reaction. All other lectins tended to react strongly (Fig. 3).

DISCUSSION

The present findings suggest that the degree of staining of ConA, UEA-I, and WGA tended to differ between G1, G2, and G3 in TCC, at least when fixed in Carnoy's, with more advanced lesions demonstrating a more intense reaction. With formalin fixation, however, there were no differences between the three different grades for these lectins. ConA tended to be stained strongly, UEA-I moderately, and WGA weakly in all the TCC. Similarly, in the UEA-II case, the degree of staining tended to increase gradually from negative to moderate according to the grade of TCC in Carnoy fixed tissues, whereas all TCC tended to react strongly after formalin fixation. DBA tended to react moderately with TCC G1 and G2, but was mainly negative for G3 in the case of Carnoy's fixation. But mainly demonstrated a homogenous weak binding to all TCC fixed in formalin. Thus, the tumor staining patterns between Carnoy's and formalin fixation differed considerably.

In their formalin fixation studies of human bladder carcinomas, Lehman et al. found that PNA binding was decreased in TCC G3¹². The discrepancy with the present results again suggests the importance of fixation. Similar to our cases, Sumiya et al. reported that low grade tumors were DBA-positive and high grade tumors were ConA-positive¹³. By contrast, Langkile et al. mentioned that a gradual loss of PNA and WGA binding correlated with higher grades of atypia. They also described the loss of WGA binding to correlate significantly with both tumor aneuploidy and

invasive characters¹⁴. In another study they demonstrated a marked decrease of binding of DBA, WGA, PNA, and UEA-I in invasive carcinomas¹⁵. However, Yagi reported PNA a high binding rate in high grade tumors, while the DBA binding rate was low¹⁶. An explanation for the variation in findings is awaited.

ConA agglutinability has been shown in animal experiments to characterize rat bladder cells following exposure to carcinogens¹⁹⁻²³. Fukushima et al. reported that PNA, SBA, and WGA bound strongly to rat TCC induced by N-butyl-N-(4-hydroxybutyl) nitrosamine (BBN), while PNA and SBA stained even SCC or preneoplastic lesions²⁴. Using a model of rat bladder cancer development induced by intravesical instillation of N-nitroso-N-methyl-urea, Langkilde et al. reported that PNA and WGA staining patterns changed from the cytoplasm to the cell membrane during progression to carcinoma²⁵. On the other hand, Takai et al. reported that the location of ConA, WGA, RCA, and PNA binding changed from the cell membrane to the cytoplasm during the development of rat bladder carcinomas induced by BBN²³. Thus the two reports gave opposing results.

Nevertheless, both clinical and animal studies have demonstrated many differences in lectin binding patterns. Of major interest, is the correspondence to our findings: the positive ConA in bladder carcinomas, and the decrease of reactivity of DBA in high grade carcinomas. Using this specificity of ConA, Akaza et al. made a bleomycin/concanavalin-A conjugate, and found it promising as an intravesical chemotherapeutic agent against an experimental bladder tumor²⁶.

Neal et al. demonstrated differences in lectin binding patterns between cryostat sections and formalin-fixed tissues of human bladder carcinomas¹¹, with a significant diminution of staining being apparent after formalin fixation. Abel et al. also mentioned a reduction of lectin staining after formalin fixation in cases of benign prostatic hypertrophy⁶. Using human bronchial mucosa, Mazzuca et al. compared three different fixations; 4% parafor-

maldehyde in 0.1M cacodylate buffer, Bouin's solution, and Carnoy's solution³⁾, and found Carnoy's solution to give the most reliable results.

In conclusion, the present study suggests that, from the view point of correlation to grading, ConA, UEA-I, WGA, UEA-II, and DBA staining might be usefully applied to Carnoy's fixed tissue. However, since we did not examine the same tissues by both fixation methods, further investigations to allow direct comparisons, as with the method of Neal et al.¹¹⁾ are planned to confirm our findings. Optimization of the method used for fixation would have tangible benefits.

REFERENECS

- 1) Goldstein IJ and Hayes CE: Lectins: carbohydrate-binding proteins of plants and animals. *Adv Carbohydr Chem Biochem* **35**: 127-340, 1978
- 2) Hohenberger P, Liewald F, Schlag P, et al.: Lectins and immunohistochemistry of colorectal cancer, its recurrences and metastases. *Eur J Surg Oncol* **16**: 289-297, 1990
- 3) Mazzuca M, Lhermitte M, Lafitte J-J, et al.: Use of lectins for detection of glycoconjugates in the glandular cells of the human bronchial mucosa. *J Histochem Cytochem* **30**: 956-966, 1982
- 4) Aoki D, Nozawa S, Iizuka R, et al.: Differences in lectin binding patterns of normal endometrium and endometrial adenocarcinoma, with special reference to staining with *Ulex europaeus* agglutinin I and peanut agglutinin. *Gynecol Oncol* **37**: 338-345, 1990
- 5) Imamura Y, Sugihara H, Miyake T, et al.: Lectin histochemistry in rat thyroid tumors. *Basic Appl Histochem* **33**: 185-196, 1989
- 6) Abel PD, Keane P, Leatham A, et al.: Change in glycoconjugate for the binding site of the lectin *Ulex europaeus* I following malignant transformation of prostatic epithelium. *Br J Urol* **63**: 183-185, 1989
- 7) Loy TS, Kyle J and Bickel JT: Binding of soybean agglutinin lectin to prostatic hyperplasia and adenocarcinoma. *Cancer* **63**: 1583-1586, 1989
- 8) Wang X-C, Kochi N, Tani E, et al.: Lectin histochemistry of human gliomas. *Acta Neuropathol* **79**: 176-182, 1989
- 9) Kosmehl H, Langbein L and Katenkamp D: Lectin histochemistry of human testicular germ cell tumors. *Neoplasma* **36**: 29-39, 1989
- 10) Walker RA: The use of lectins in histopathology. *Pathol Res Pract* **185**: 826-835, 1989
- 11) Neal DE, Charlton RG and Bennett MK: Histochemical study of lectin binding in neoplastic and non-neoplastic urothelium. *Br J Urol* **60**: 399-404, 1987
- 12) Lehman TP, Cooper HS and Mulholland SG: Peanut lectin binding sites in transitional cell carcinoma of the urinary bladder. *Cancer* **53**: 272-277, 1984
- 13) Sumiya H, Sato N, Isaka S, et al.: Lectin-binding sugar chain of bladder tumor. *Acta Urol Jpn* **34**: 86-89, 1988 (in Japanese)
- 14) Langkilde NC, Wolf H and Orntoft TF: Binding of wheat and peanut lectins to human transitional cell carcinomas: Correlation with histopathologic grade, invasion, and DNA ploidy. *Cancer* **64**: 849-853, 1989
- 15) Langkilde NC, Wolf H and Orntoft TF: Lectin histochemistry of human bladder cancer: loss of lectin binding structures in invasive carcinomas. *APMIS* **97**: 367-373, 1989
- 16) Yagi S: Blood group isoantigen and lectin binding studies in the human bladder cancer. *Jpn J Urol* **80**: 682-690, 1989 (in Japanese)
- 17) Hyun K-H, Nakai M, Kawamura K, et al.: Histochemical studies of lectin binding patterns in keratinized lesions, including malignancy. *Virchows Arch A* **402**: 337-351, 1984
- 18) Kumasa S, Mori H, Tsujimura T, et al.: Calcifying epithelioma of Malherbe with ossification. Special reference to lectin binding and immunohistochemistry of ossified sites. *J Cutan Pathol* **14**: 181-187, 1987
- 19) Kakizoe T, Kawachi T and Sugimura T: Agglutination of bladder cells by concanavalin A during the early phase of treatment of rats with N-butyl N-(4-hydroxybutyl) nitrosamine. *Cancer Res* **39**: 3353-3356, 1979
- 20) Kakizoe T, Komatsu H, Niijima T, et al.: Increased agglutinability of bladder cells by concanavalin A after administration of carcinogens. *Cancer Res* **40**: 2006-2009, 1980
- 21) Kakizoe T, Komatsu H, Niijima T, et al.: Maintenance by saccharin of membrane alterations of rat bladder cells induced by subcarcinogenic treatment with bladder carcinogens. *Cancer Res* **41**: 4702-4705, 1981
- 22) Kakizoe T, Nishino Y, Ohtani M, et al.: Correlation of results of agglutination assays with concanavalin A and carcinogenesis experiments on promoters of bladder cancer. *Jpn J Cancer Res* **76**: 930-936, 1985

- 23) Takai K, Kakizoe T, Sekine T, et al.: Analysis of avidin-biotin complexes with lectins of membrane glycoproteins in the urinary bladder of rats treated with N-butyl N-(4-hydroxybutyl) nitrosamine. *J Urol* **137**: 136-139, 1987
- 24) Fukushima S, Sakata T, Ito N, et al.: Lectin histochemistry of bladder cancers induced by N-butyl-N-(4-hydroxybutyl) nitrosamine in rats. *Proc Jpn Cancer Assoc 42nd Ann Meet 1983 (in Japanese)*
- 25) Langkilde NC, Hastrup J, Olsen S, et al.: Immunohistochemistry and cytochemistry of experimental rat bladder cancer: binding of the lectins PNA and WGA and of a Le mouse monoclonal antibody. *J Urol* **141**: 981-986, 1989
- 26) Akaza H, Koseki K, Kobayashi K, et al.: Experimental intravesical treatment of bladder tumor with concanavalin-A conjugated bleomycin. *Jpn J Urol* **75**: 211-214, 1984
(Received on November 30, 1992)
(Accepted on June 4, 1993)

和文抄録

種々のレクチン染色によるヒト膀胱癌の免疫組織化学的解析

名古屋市立大学医学部泌尿器科学教室 (主任: 大田黒和生教授)

岡村 武彦, 上田 公介, 大田黒和生

豊川市民病院泌尿器科 (部長: 井上和彦)

井 上 和 彦

安城厚生病院泌尿器科 (部長: 和志田裕人)

和 志 田 裕 人

朝日大学医学部口腔外科学教室 (主任: 森 昌彦教授)

森 昌 彦

高知医科大学歯科口腔外科学教室 (主任: 尾崎登喜雄教授)

立 本 行 宏

大阪市立大学医学部第一病理学教室 (主任: 福島昭治教授)

福 島 昭 治

われわれは、51例の膀胱癌症例に対してレクチン免疫組織化学解析を施行した。組織型の内訳は、移行上皮癌 (TCC) 44例 (G1, 15例; G2, 17例; G3, 12例)、扁平上皮癌 (SCC) 7例であり、ホルマリンないしカルノア液にて固定後に以下の10種類のレクチン染色を行い、顕微鏡的に観察した。concanavalin agglutinin (Con A), soybean agglutinin (SBA), Lotus tetragonolobus agglutinin (LTA), Dolichos biflorus agglutinin (DBA), peanut agglutinin (PNA), Ricinus communis agglutinin I (RCA₁), Ulex europaeus agglutinin I, II (UEA-I, II), wheat germ agglutinin (WGA), Pisum sativum

agglutinin (PEA)。

その結果、カルノア固定において、TCCでCon A, UEA-I, WGA, UEA-IIでは正の相関傾向が、DBAでは負の相関傾向が見られた。ホルマリン固定では、RCA₁にのみある程度の正の相関傾向を認めたのみであった。SCCは各種レクチンに対していずれの固定法においてもTCCより強い結合性を示す傾向が見られた。以上われわれの結果からは、TCCにおける組織学的異型度と各種レクチンの反応は、カルノア固定の方が優れている事が示唆された。

(泌尿紀要 39: 899-905, 1993)