

Title	Adenocarcinoma arising in the ileal segment of a defunctionalized ileocystoplasty
Author(s)	Takahashi, Atsushi; Tsukamoto, Taiji; Kumamoto, Yoshiaki; Sato, Yoshikazu; Shibuya, Akihiko; Sato, Masaaki
Citation	泌尿器科紀要 (1993), 39(8): 753-755
Issue Date	1993-08
URL	http://hdl.handle.net/2433/117902
Right	
Type	Departmental Bulletin Paper
Textversion	publisher

ADENOCARCINOMA ARISING IN THE ILEAL SEGMENT OF A DEFUNCTIONALIZED ILEOCYSTOPLASTY

Atsushi Takahashi, Taiji Tsukamoto, Yoshiaki Kumamoto,
Yoshikazu Sato and Akihiko Shibuya

From the Department of Urology, School of Medicine, Sapporo Medical University

Masaaki Sato

From the Division of Clinical Pathology, School of Medicine, Sapporo Medical University

We report a case of adenocarcinoma arising in the ileal segment of an ileocystoplasty which had remained defunctionalized for 22 years, after conversion to the ileal conduit. In our case, inflammation or previous radiation as well as urine exposure are suggested to have participated in the development of the carcinoma in the augmented bladder.

(Acta Urol. Jpn. 39: 753-755, 1993)

Key words: Adenocarcinoma, Ileocystoplasty

INTRODUCTION

An isolated or non-isolated bowel segment has been often used to reconstruct the urinary tract. Since adenocarcinoma of the colon in ureterosigmoidostomy was reported¹⁾, there have been sporadic case-reports of a malignancy developing in the reconstructed urinary tract²⁾. We present a case of adenocarcinoma arising in the ileal segment of an ileocystoplasty which had remained defunctionalized for 22 years, after a conversion to the ileal conduit.

CASE REPORT

A 45-year-old woman was found to have a vesicovaginal fistula in 1967, following radical hysterectomy and external radiotherapy for squamous cell carcinoma of cervix. Both transvaginal and transvesical closure had failed. Because of the persistent vesicovaginal fistula and small capacity bladder, she simultaneously received resection of the fistula and bladder augmentation with ileocystoplasty in 1969. However, the surgical procedures failed to bring about a closure of the fistula. Three months later, ileal conduit was finally constructed with the ileocystoplasty remnant

being left in situ.

In 1991, 22 years later, the patient experienced urethral bleeding. A cystoscopic examination revealed multiple non-papillary tumors located in the dome that had been previously reconstructed by the ileum, of the contracted bladder. Well differentiated adenocarcinoma was histopathologically found in the biopsy specimens. All evaluations for metastasis were negative. In April, 1991, the bladder with the previously reconstructed ileal segment was

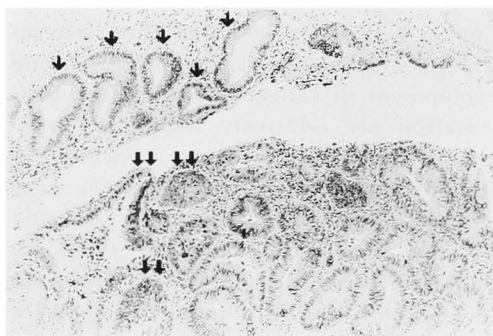


Fig. 1. Well differentiated adenocarcinoma (lower left of the figure) was observed, accompanying a normal ileal epithelia (upper left of the figure) (H & E, $\times 118$).

↓↓ : adenocarcinoma
↓ : normal epithelia

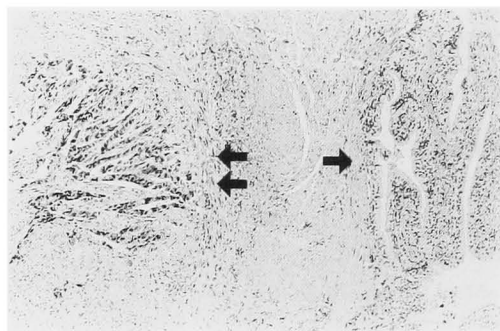


Fig. 2. Transitional cell epithelia (right half of the figure) without neoplastic changes were observed. They did not show a transition to adenocarcinoma area (left half of the figure) (H & E, $\times 118$).

→: transitional cell epithelia

← adenocarcinoma

surgically removed. The tumor infiltrated into the surrounding tissue. Histopathological examination revealed a well differentiated adenocarcinoma that accompanied the normal ileal epithelia including paneth cells and adenomatous hyperplasia, indicating that the carcinoma arose in the ileum (Fig. 1). No neoplastic changes were observed in the transitional cell epithelia that were clearly separated from the adenocarcinoma area (Fig. 2).

DISCUSSION

A growing number of patients with a malignancy arising in the colon after ureterosigmoidostomy have been reported¹⁾, while development of cancers after bladder augmentation are relatively rare²⁾. Filmer and Spence have recently reviewed 14 cases of a malignancy arising in the augmented cystoplasty. The cases consisted of 7 of adenocarcinoma, 5 of transitional cell carcinoma and one of sarcoma or small cell carcinoma, which were found in the bowel segment, the bladder or in both. Despite a low incidence of malignancies in bladder augmentation, there are several similarities between malignancies arising in the colon after ureterosigmoidostomy and those in bladder augmentation., namely, latency period, tu-

mor biology, and location. Therefore, similar carcinogenic environments may have a role in these two entities^{2,3)}. The mechanisms of ureterosigmoidostomy carcinogenesis have been studied since the development of a rat model by Griessey and associates⁴⁾. Based on these studies, Gittes⁵⁾ postulates that the carcinogenesis of ureterosigmoidostomy clearly depends on the initial presence of urine, feces, uroepithelium, and colon epithelium in the close apposition at a healing anastomotic suture line. However, Filmer and Spence²⁾ also indicate that inflammatory responses, reactive oxygen species by inflammatory cells as well as urine would be responsible for neoplastic formation in bladder augmentation. Indeed, the majority of the reports have revealed that the patients with a malignancy of bladder augmentation currently have or had a history of chronic specific or non-specific infection in the augmented bladder. Two recent publications^{6,7)} suggest that a neoplasm can develop in the colon after conversion of ureterosigmoidostomy to an ileal conduit even in the short period of urine exposure, as was seen in our case with the exposure being only for 3 months. Inflammation or radiation may participate in development of a carcinoma in the bladder augmentation, in particular, when the intestine is exposed to urine for a short period.

REFERENCES

- 1) Husman DA and Spence HM: Current status of tumor of the bowel following ureterosigmoidostomy: A review. *J Urol* **144**: 607-610, 1990
- 2) Filmer RB and Spencer JR: Malignancies in bladder augmentations intestinal conduit. *J Urol* **143**: 671-678, 1990
- 3) Golomb J, Klutke CG, Lewin KJ, et al.: Bladder neoplasms associated with augmentation cystoplasty: report of 2 cases and literature review. *J Urol* **142**: 377-380, 1989
- 4) Griessey HM, Steele GD and Gittes RF: Rat model for carcinogenesis in ureterosigmoidostomy. *Science* **207**: 1079-1080, 1980
- 5) Gittes RF: Carcinogenesis in ureterosigmoidostomy. *Urol Clin North Am* **13**: 201-205, 1986
- 6) Sohn M, Fuzeki L, Deutz F, et al.: Signet

ring cell carcinoma in adenomatous polyp at site of ureterosigmoidostomy 16 years after conversion to ileal conduit. J Urol **143**: 805-807, 1990

- 7) Schipper H and Decter A: Carcinoma of the colon arising at ureteral implant sites despite

early external diversion: pathogenic and clinical implications. Cancer **47**: 2062-2065, 1981

(Received on March 10, 1993)
(Accepted on April 26, 1993)

和文抄録

回腸を利用した膀胱形成術後に回腸部分より発生した腺癌の1例

札幌医科大学泌尿器科学教室 (主任: 熊本悦明教授)

高橋 敦, 塚本 泰司, 熊本 悦明
佐藤嘉一, 渋谷明彦

札幌医科大学中央検査部病理部門 (主任: 森 道夫教授)

佐 藤 昌 明

22年間尿路として機能していなかった回腸膀胱の回腸部分より発生した腺癌の1例を報告した。この例では、回腸を用いた膀胱形成術の3カ月後に回腸導管が

行われたことから、尿の暴露に加え膀胱の炎症あるいは以前の放射線照射が癌発生に関係しているのではないかと推測された。

(泌尿紀要**39**: 753-755, 1993)