

Title	The prognostic value of the HNK-1 (Leu-7) antigen in prostatic cancer--an immunohistochemical study
Author(s)	Liu, Xiu-heng; Yoshiki, Tatsuhiro; Kokuho, Masanori; Okada, Yusaku; Tomoyoshi, Tadao; Higuchi, Kayoko
Citation	泌尿器科紀要 (1993), 39(5): 439-444
Issue Date	1993-05
URL	http://hdl.handle.net/2433/117845
Right	
Type	Departmental Bulletin Paper
Textversion	publisher

THE PROGNOSTIC VALUE OF THE HNK-1 (Leu-7) ANTIGEN IN PROSTATIC CANCER

—AN IMMUNOHISTOCHEMICAL STUDY—

Xiu-heng Liu, Tatsuhiro Yoshiki, Masanori Kokuho,
Yusaku Okada and Tadao Tomoyoshi

From the Department of Urology, Shiga University of Medical Science

Kayoko Higuchi

From the Department of Surgical Pathology, Kyoto National Hospital

The anti-HNK-1 (Leu-7) monoclonal antibody (MAB) was revealed to be reactive with non-cancerous and cancerous prostatic epithelial cells, although this antibody was originally found to be reactive against natural killer cells. However, the prognostic significance of HNK-1 antigen in prostatic cancer patients remains unknown. The expression of HNK-1 antigen on prostatic cancer was investigated immunohistochemically using the avidin-biotin-peroxidase complex (ABC) method with the anti-HNK-1 monoclonal antibody. Of the 52 patients with prostatic cancer, 49 patients (94%) showed reactivity to anti-HNK-1 MAB and the immunoreaction was associated with the histological differentiation of prostatic cancer. Well differentiated cancer showed the highest percentage of positively stained cancer cells and poorly differentiated cancer showed the lowest percentage. No statistically significant differences existed between groups classified by stage, although the more advanced cancers tended to have weaker reactions. The five-year survival rate and interval free of progression were then studied using the Kaplan-Meier method on 33 patients with stage D₂ disease who had received endocrine therapy. The findings indicated that a high survival rate and a longer interval free of progression were associated with a higher fraction of positively stained cancer cells. In conclusion, the expression of HNK-1 antigen on prostatic cancer may be a useful prognostic factor in patients with prostatic cancer.

(Acta Urol. Jpn. 39: 439-444, 1993)

Key words: HNK-1, Prostatic cancer, Immunohistochemistry, Prognostic factor

INTRODUCTION

HNK-1 (Leu-7) antigen was initially found to be expressed on natural killer (NK) cells¹⁾. Subsequent studies have shown that anti-HNK-1 monoclonal antibody (MAB) was also reactive with myelinated nerves, pancreatic islet cells, chief cells of the stomach, adrenal medullary cells and other normal tissues and tumors derived from the neuroectoderm and the amine precursor uptake and decarboxylation systems^{2,3)}. In 1985, anti-HNK-1 was first reported to detect an antigen on normal, benign and malignant prostatic tissues^{3,4)}. However, to date, no reports have assessed the relationship between the anti-HNK-1 immunohistochemical reactivity and the biological behavior of prostatic cancer. In this report, we investigated the extent

(fraction of positively stained cancer cells) of immunostaining in 52 cases of prostatic adenocarcinoma using the avidin-biotin-peroxidase complex (ABC) method and attempt to reveal the relationships between anti-HNK-1 MAB reactivity and histological differentiation, survival rate and the interval free of progression.

MATERIALS AND METHODS

Fifty-two patients with prostatic cancer were diagnosed at the Department of Urology, Shiga University of Medical Science, from June 1982 to September 1991. Their average age at diagnosis was 70.3 years (from 53 to 87 years). Three patients were in stage A, 2 in stage B, 14 in stage C and 33 in stage D. The average follow-up period was 39.4 months (from 2 to 118 months).

Immunohistochemical staining of tissues was performed according to the procedure described by Hsu et al.⁵⁾ Briefly, tissue sections were deparaffinized and rehydrated through a xylene and graded alcohol series. Endogenous peroxidase activity was blocked by immersion for 30 minutes in 0.1% hydrogen peroxide (H_2O_2) and non-specific binding of antibodies was blocked by incubation for 30 minutes with Block Ace solution (Dainippon Pharmaceutical Co., Ltd., Osaka, Japan). The tissue sections were then incubated overnight with anti-HNK-1 MAb (Becton Dickinson Immunocytometry System, CA, U.S.A.) at a dilution of 1:100 and subsequently incubated with biotinylated anti-mouse IgM (Vector Laboratories, Inc., CA, U.S.A.) at a dilution of 1:200 for 60 minutes. Subsequently the sections were incubated with ABC complex at a dilution of 1:200 for 60 minutes and then immersed in the diaminobenzidine substrate.

The extent of staining was classified into four groups, according to the fraction of positively stained cancer cells: “-” denoting that no positive cells were present; “+” denoting that the number of positively stained cancer cells was less than one third of the number of total cancer cells; “++” denoting that between one-third and two-thirds of the cancer cells were stained positively and “+++” denoting that more than two-thirds of the cancer cells were positively stained.

Consecutive sections which were not incubated with anti-HNK-1 MAb were used as negative controls and BPH sections were used as positive controls. Sections stained with hematoxylin and eosine were reviewed to judge the histological grade of the prostatic cancer according to the grading system of the Japanese Urological Association⁶⁾.

All survival curves were estimated according to the Kaplan-Meier method. Non-progression was defined as complete or partial remission or no change following treatment according to the criteria described by Schmidt et al.⁷⁾ The correlation between the reactivity of anti-HNK-1 MAb and the histological grade or clinical

stage was evaluated by the Chi-square test.

RESULTS

Forty-nine of 52 cases (94%) of prostatic cancer and all BPH specimens were posi-

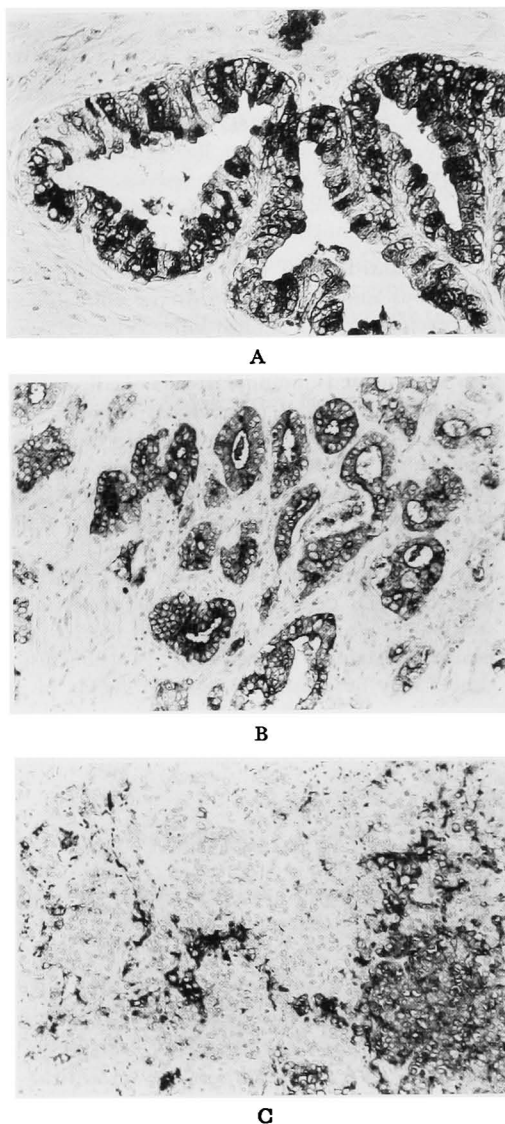


Fig. 1. The tissue sections were stained with anti-HNK-1 antibody using ABC Method A: Section of BPH tissue. Heterogeneity was obvious in the glands. The fibromuscular stroma was not stained. $\times 200$ B: Section of well differentiated prostatic cancer. More than two-thirds of the cancer cells were stained positively. $\times 100$ C: Section of poorly differentiated prostatic cancer. Less than one-third of the cancer cells were stained positively. $\times 100$

tively stained. Positive staining was localized in the cytoplasm of epithelial cells of benign or malignant prostatic tissue. The fibromuscular stroma was not stained. Heterogeneity was observed in BPH tissues, as well as in the nests of the cancer cells (Fig. 1).

The extent of staining was correlated with the histological grade ($p < 0.05$, Table 1). Well differentiated cancers had the highest percentage of positively stained cells and poorly differentiated cancers had the lowest percentage.

Prostatic cancers in early stages (stages A and B) showed higher percentages of positively stained cancer cells; more advanced cancers tended to have lower fractions of positively stained cancer cells, although no statistically significant difference existed (Table 2).

The relationship between the five-year survival rate and the probability of a progression-free course was studied in 33 patients with stage D₂ cancer who had received endocrine therapy. During the follow-up period, 17 died of prostatic cancer, and 4 died of cardiovascular diseases or other

Table 1. Relationship between the extent of immunostaining and grade

Grade	Extent				Total
	-	+	#	##	
Wel	0	0	0	7	7
Mod	2	8	8	7	25
Por	1	9	5	5	20
Total	3	17	13	19	52 ($p < 0.05$)

- : no positive cells were present, + : the number of positively stained cancer cells were less than one-third of the number of total cancer cells, # : between one-third and two-thirds of the cancer cells were stained positively, ## : more than two-thirds of the cancer cells were positively stained. "Wel", "Mod" and "Por" denote well, moderately and poorly differentiated adenocarcinoma of the prostate, respectively.

Table 2. Relationship between the extent of immunostaining and stage

Stage	Extent				Total
	-	+	#	##	
A	0	0	1	2	3
B	0	1	0	1	2
C	1	5	5	3	14
D	2	11	7	13	33
Total	3	17	13	19	52 ($p : NS$)

*NS : Not significant

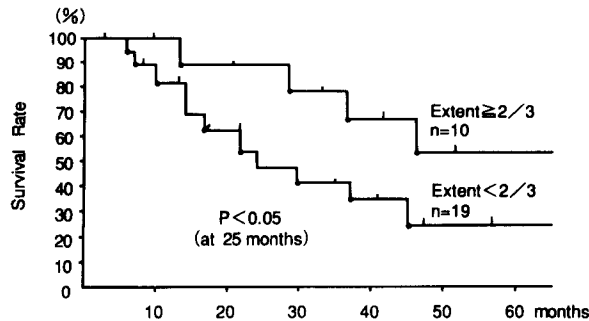


Fig. 2. Survival curves of cases in stage D₂ according to extent of immunostaining.

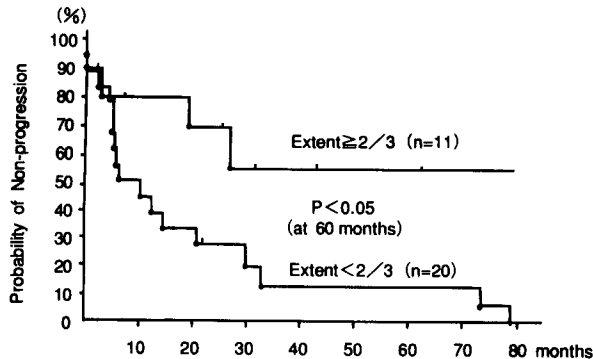


Fig. 3. Probability of non-progression of patients in stage D₂ according to extent of immunostaining.

diseases. Fig. 2 shows the cancer-specific survival rates, according to the extent of staining. The group with more than two-thirds of their cancer cells positively stained showed a higher survival rate than the group with less than two-thirds of their cancer cells positively stained ($p < 0.05$, at 25 months). As shown in Fig. 3, a longer interval without progression was observed in the cases with more than two-thirds of their cancer cells stained positively, compared to the cases with less than two-thirds of their cells stained positively ($p < 0.05$, at 60 months).

DISCUSSION

In general, tumor markers may aid in diagnosis, detection of metastases, staging, prediction of therapeutic response and prognosis of cancers. Of the tumor markers for prostatic cancer, prostate-specific acid phosphatase (PAP) and prostate-specific antigen (PSA) have been widely studied and clinically accepted. Determinations of serum PAP and PSA were reported to be useful in predicting endocrine treatment response, lymph node involvement and progression of prostatic carcinoma⁸⁻¹². However, immunohistochemical studies on formalin-fixed sections stained for PAP have yielded conflicting results concerning the correlation between the immunoreaction and tumor differentiation or progression of the disease¹²⁻¹⁵. Immunoperoxidase studies with PSA have indicated that PSA is more sensitive than PAP and that PSA staining is related to the histological differentiation of the tumor^{3,15}. Nevertheless, only about 76~81% of all patients with prostatic cancer showed elevated serum PSA levels^{8,9}. The sensitivity of PSA is still insufficient in detecting prostatic cancer. It is necessary to discover new markers that are more sensitive.

The HNK-1 antigen seems promising as a tumor marker since it is expressed strongly by prostatic cancer, as well as by normal and benign prostate^{3,4}. In this study on formalin-fixed, paraffin-embedded sections stained using the ABC method, all

BPH cases and 49 of 52 (94%) patients with prostatic cancer showed anti-HNK-1 MAb reactivity and the immunoreaction was correlated with the histological differentiation of the cancer. Well differentiated cancers showed the highest percentage of positively stained cancer cells and the more poorly differentiated cancers showed the lowest percentage. Wahab and Wright reported that HNK-1 was more sensitive than PAP and PSA in identifying prostatic cancer³. In a recent study which compared anti-HNK-1 MAb with anti-PAP MAb and anti-PSA MAb which were produced in our laboratory¹⁶, we obtained similar results (data not shown).

At present, it is unclear whether HNK-1 can function as a parameter for predicting the prognosis of prostatic cancer. It is widely accepted that the prognosis of prostatic cancer depends on the histological grade and clinical stage. In an effort to exclude the influence of stage on survival, we analyzed 33 patients with stage D₂ cancer who had received similar anti-androgen treatments. The fraction of positively stained cancer cells significantly correlated with the survival rate and interval free of progression. Longer survival times and intervals free of progression were observed in patients showing higher HNK-1 expression; patients showing decreased HNK-1 expression had a less favorable outcome.

We also observed that more advanced prostatic cancer tended to show weaker anti-HNK-1-MAb reactions. Further study is needed to determine if the HNK-1 antigen is useful in the staging of prostatic cancer.

Although the number of patients in this study was small, the results indicate that the percentage of cancer cells stained positively with anti-HNK-1 may be useful in predicting the survival rate and interval free of progression of patients with prostatic cancer.

Further investigation will be required to determine whether the HNK-1 antigen is released into the blood in sufficient amounts to be clinically useful.

REFERENCES

- 1) Abo T and Balch CM: A differentiation antigen of human NK and K cells identified by a monoclonal antibody (NHK-1). *J Immunol* **127**: 1024-1029, 1981
- 2) Cailaud J-M, Benjelloun S, Bosq J, et al.: HNK-1 defined antigen detected in paraffin-embedded neuroectoderm tumors and those derived from cells of the amine precursor uptake and decarboxylation system. *Cancer Res* **44**: 4432-4439, 1984
- 3) Wahab ZA and Wright GL, Jr: Monoclonal antibody (anti-Leu7) directed against natural killer cells reacts with normal benign and malignant prostatic tissues. *Int J Cancer* **36**: 677-683, 1985
- 4) Rusthoven JJ, Robinson JB, Kolin A, et al.: The natural-killer-cell-association HNK-1 (Leu-7) antibody reacts with hypertrophic and malignant prostatic epithelium. *Cancer* **56**: 289-293, 1985
- 5) Hsu SM, Raine L and Fanger H: Use of avidin-biotin-peroxidase complex (ABC) in immunoperoxidase techniques. A comparison between ABC and unlabeled antibody (PAP) procedures. *J Histochem Cytochem* **29**: 577-580, 1981
- 6) Japanese Urological Association, Japanese Pathological Society: General rule for clinical and pathological studies on prostatic cancer. Tokyo: Kanehara & Co., Ltd. The 1st edition p. 66, 1985
- 7) Schmidt JD, Johnson DE, Scott WW, et al.: Chemotherapy of advanced prostatic cancer. Evaluation of response parameters. *Urology* **7**: 602-610, 1976
- 8) Yoshiki T, Okada K, Oishi K, et al.: Clinical significance of tumor markers in prostatic carcinoma -Comparative study of prostatic acid phosphatase, prostate specific antigen and γ -seminoprotein- *Acta Urol Jpn* **33**: 2044-2049, 1987
- 9) Arai Y, Yoshiki T, Oishi K, et al.: The role of prostate specific antigen in monitoring prostatic cancer and its prognostic importance. *Urol Res* **18**: 331-366, 1990
- 10) Arai Y, Yoshiki T and Yoshida O: Prognostic significance of prostate specific antigen in endocrine treatment for prostatic cancer. *J Urol* **144**: 1415-1419, 1990
- 11) Arai Y, Yoshiki T, Yamabe H, et al.: Value of prostate-specific antigen measurements in predicting lymph node involvement in prostatic cancer. *Urol Int* **45**: 356-360, 1990
- 12) Sakai H, Shiraishi K, Minami Y, et al.: Immunohistochemical prostatic acid phosphatase level as a prognostic factor of prostatic carcinoma. *Prostate* **19**: 265-272, 1991
- 13) Epstein JI and Eggleston JC: Immunohistochemical localization of prostate-specific acid phosphatase and prostate-specific antigen in stage A adenocarcinoma of prostate: prognostic implication. *Hum Pathol* **15**: 853-859, 1984
- 14) Ito H, Yamaguchi K, Sumiya H, et al.: Histochemical study of R1881-binding protein, prostatic acid phosphatase, prostate-specific antigen, and γ -seminoprotein in prostatic cancer. *Eur Urol* **12**: 49-53, 1986
- 15) Brandes D: Biological characteristics of prostatic carcinoma. In: *Uro-pathology*. Edited by Gray S. Hill. The 1st edition p. 1259-1290, Churchill Livingstone Inc., New York, 1989
- 16) Yoshiki T, Okada Y, Tomoyoshi T, et al.: Human prostatic tissue specific antigens: A model for the research of monoclonal antibodies against unknown antigens. *Acta Urol Jpn* **39**: 213-129, 1993

(Received on October 22, 1992)
 (Accepted on January 19, 1993)

和文抄録

前立腺癌における HNK-1 (Leu-7) 抗原の予後因子としての検討
—免疫組織化学的検討—

滋賀医科大学泌尿器科学教室 (主任: 友吉唯夫)

劉 修恒, 吉貴 達寛, 國保 昌紀

岡田 裕作, 友吉 唯夫

国立京都病院検査部

樋 口 佳代子

当初, NK 細胞に反応するとされていた抗 HNK-1 モノクローナル抗体は, 腫瘍性および非腫瘍性の前立腺組織にも反応することが判明した。しかし, 前立腺癌における HNK-1 抗原の予後因子としての意義はまだ明らかではない。今回われわれは, 前立腺癌組織における HNK-1 抗原の発現を抗 HNK-1 抗体を用いて ABC 法での免疫組織化学的に検討した。その結果, HNK-1 抗原は 52 例中 49 例 (94%) に陽性で, しかもその反応性は癌の組織分化度と相関した。高分化癌で陽性癌細胞の比率が最も高く, 低分化癌で

もっとも低かった。進行癌での反応性は弱くなる傾向があったが, 各臨床病期間に統計学的に有意な反応性の違いはなかった。内分泌療法を受けた 33 例の stage D2 症例について, 5 年生存率と非進展率を Kaplan-Meier 法で検討すると, HNK-1 抗原が 3 分の 2 以上陽性のグループが, 3 分の 2 未満のグループに比べて有意に良好な生存率と非進展率を示した。以上より HNK-1 抗原は, 前立腺癌の有用な予後因子になりえると考えられる。

(泌尿紀要 39: 439-444, 1993)

Editorial comment

著者は ABC 法により, HNK-1 (Leu-7) 抗体が前立腺の良性腺上皮や高分化癌で染色性が高く, 低分化・未分化になるほど薄れること, また染色性と無再燃期間・予後とに有意の相関があることを明らかにした。知るかぎりでは, 前立腺癌について検討した最初の論文であると思う。

HNK-1 は, はじめ NK specific な表面マーカーとされていたが, その後の研究で, 他の T 細胞とも交叉反応¹⁾, 神経細胞にもこれと反応する抗原 (CD 57) のあることが明らかにされている²⁾。すでに神経細胞の接着や分化との関連, 下垂体における正常組織と腺腫での発現の相違などが検討されている。また悪性腫瘍では, 甲状腺腫, 皮膚の基底細胞癌, メラノーマ, 種々の軟部組織肉腫などで, 組織型による陽性細胞の多寡, 腫瘍細胞での発現の相違, 他病変との鑑別などさまざまな検討がなされてきた。しかし, CD57 の性状や機能はまだ不明な点が多く, 著者のえた前立腺癌における臨床経過や予後との相関をどのように理解すればよいか。上述のように神経系にも広く存在することから, 局所免疫能だけでなく, 精神・神経系・肉体を含めた全身の免疫機能調節に関与していることも想像されるのである。

前立腺癌予後判定因子としては, 臨床的インパクトはさほど評価しがたいと思う。組織化学の上でも, clear cut なデータは多くないが, すでにわれわれは PAP や PSA を持っているからである。われわれが真実必要とするのは, 一夢物語ではあろうが一正常細胞ではみられず癌化によって出現する, あるいは組織の malignant potential を予知できる「物質」である (一時注目された ras 腫瘍遺伝子産物, P21 蛋白も結局夢に終わったようである)。

とはいえ前立腺癌, ことに stage D 癌の予後規制因子として, HNK-1 がどのような価値を持つか, 現在臨床的に最良とされる Gleason スコアを越えられるかどうか, さらに追試の上別の機会にまた教示していただきたい。

文 献

- 1) 内田温士, 杉江勝治: CD56 と CD57. *Medical Immunol* 24: 491-495, 1992
- 2) Markey AC: HNK-1 antigen is not specific for natural killer cells. *Invest Dermatol* 92: 774-775, 1989

福井医科大学泌尿器科学教室

岡田 謙一郎