

Title	Bilateral primary non-Hodgkin's lymphoma of the adrenal glands with adrenal insufficiency: a case report
Author(s)	Utsunomiya, Masato; Takatera, Hiroshi; Itoh, Hiroshi; Itatani, Hiroaki; Tsujimura, Takahiro
Citation	泌尿器科紀要 (1992), 38(3): 311-314
Issue Date	1992-03
URL	<a href="http://hdl.handle.net/2433/117503">http://hdl.handle.net/2433/117503</a>
Right	
Type	Departmental Bulletin Paper
Textversion	publisher

## BILATERAL PRIMARY NON-HODGKIN'S LYMPHOMA OF THE ADRENAL GLANDS WITH ADRENAL INSUFFICIENCY: A CASE REPORT

Masato Utsunomiya, Hiroshi Takatera, Hiroshi Itoh,  
Takahiro Tsujimura\* and Hiroaki Itatani

*From the Departments of Urology and Pathology\*, Sumitomo Hospital*

A 72-year-old woman with bilateral non-Hodgkin's lymphoma of the adrenal glands causing adrenal insufficiency is reported. The left-side lymphoma (diffuse large B-cell lymphoma) was removed surgically but the right-side lymphoma could not be removed. Complete response was obtained with subsequent combined chemotherapy and was maintained for 6 months with repeated chemotherapies. However, the patient died of liver recurrence 1 year after admission. In cases of malignant lymphoma forming a bulky mass, surgery with subsequent chemotherapy appears to reduce the cancer volume and improve the therapeutic outcome.

(Acta Urol. Jpn. 38: 311-314, 1992)

**Key words:** Primary non-Hodgkin's lymphoma, Bilateral adrenal glands, Chemotherapy, Operation

### INTRODUCTION

The primary lesions of malignant lymphoma in the urologic field are found in the kidneys, testes, bladder and related areas<sup>1)</sup>. Although lymphoma involving the adrenal glands is sometimes encountered in cases of widespread lymphoma<sup>2)</sup>, malignant lymphoma arising from the adrenal gland is extremely rare<sup>5-8)</sup>. We describe such a rare case of bilateral malignant lymphoma (diffuse large B-cell lymphoma) of the adrenal glands causing adrenal insufficiency and discuss the role of surgical procedure for this order.

### CASE REPORT

A 72-year-old female was admitted to our hospital for diminished consciousness and for general fatigue on May 26, 1987. She had been febrile and confused during the week before admission. The serum sodium level was 129.0 mEq/l and the serum LDH elevated to 1,783 U. CT-scan showed bilateral, huge, homogeneous adrenal tumor but no other retroperitoneal adenopathies (Fig. 1). Although the serum

cortisol level was at the lower limit of the normal range (11.7 mg/dl), the ACTH was elevated (170 pg/ml). We suspected that this condition was caused by adrenal insufficiency secondary to large adrenal masses. Therefore an adrenal steroid hormone with antibiotics was administered immediately. After two days of treatment, the patient had fully regained consciousness while her fever had subsided. Angiographic findings revealed bilateral tumors originating from the adrenal glands. Additional radiographic studies, including gastrointestinal series and chest film, revealed no other abnormal findings. Results of other hormonal studies of the serum and the urine were also normal. On June 2, 1987, we performed adrenalectomy based on the diagnosis of bilateral nonfunctioning adrenal tumors. The tumor on the left side could be resected, but that on the right side could not because of direct invasion to the liver, kidney and inferior vena cava. Histological examination showed the tumor to be a non-Hodgkin's lymphoma, diffuse large cell type (by Working Formulation<sup>3)</sup>) (Fig. 2), while immunohisto-

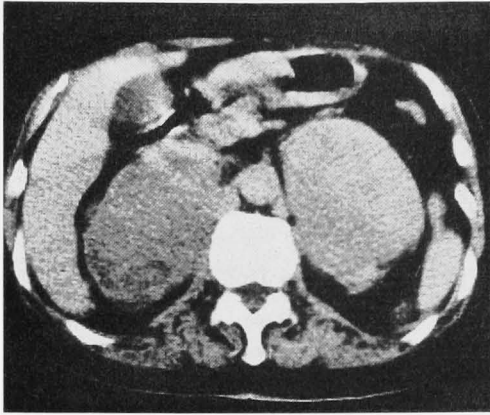


Fig. 1. CT-scan shows symmetrical enlarged adrenal masses. The right mass measures  $9.3 \times 5.7$  cm and the left mass  $8.9 \times 6.0$  cm. Additional caudal scans showed no retroperitoneal adenopathies.

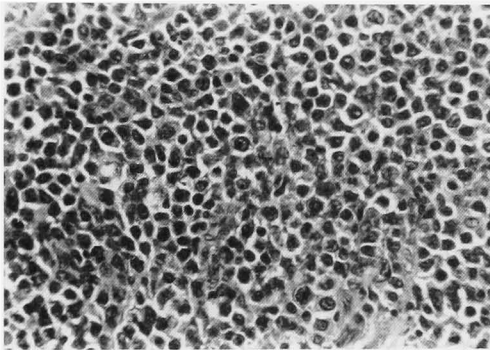


Fig. 2. Histologic feature of the tumor shows non-Hodgkin's lymphoma, diffuse large cell type. (H&E,  $\times 200$ )



Fig. 3. Immunostaining of the tumor cells using the ABC method with methyl green nuclear counterstaining. Many lymphoma cells are positive for L-26, B cell marker (DAKO, Ccurate Chemical, Westbury, NY). ( $\times 200$ )

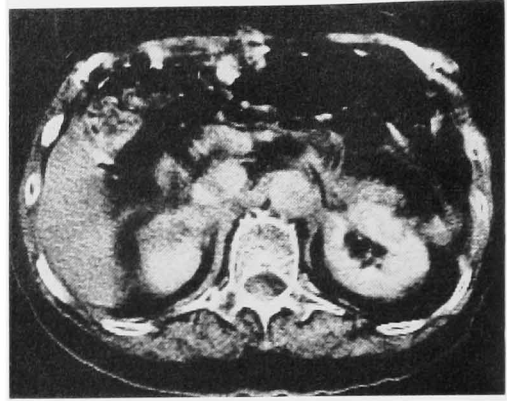


Fig. 4. The unresectable right adrenal tumor had been completely eliminated after the second chemotherapy.

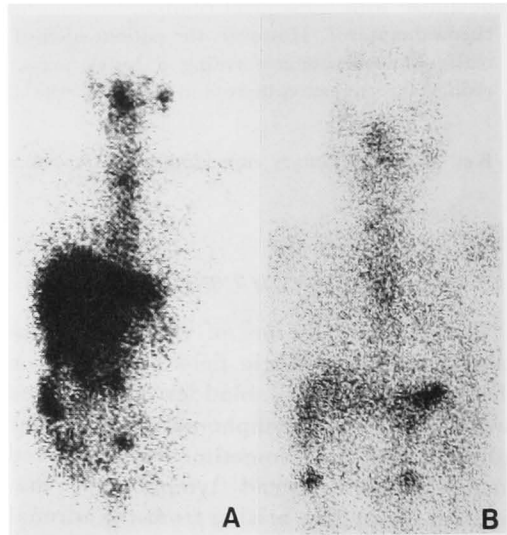


Fig. 5.  $^{67}\text{Ga}$  scintigram also shows complete disappearance of the right adrenal tumor. (A: Before B: After the chemotherapy)

chemical staining with the avidin-biotin-peroxidase complex (ABC) method of Hsu et al.<sup>4)</sup> proved that the tumor cells were of B cell origin (Fig. 3). After surgery, the patient was given 1 mg of vincristine, 750 mg of cyclophosphamide, 20 mg of doxorubicin and 50 mg of prednisone daily for 5 days. This regimen was repeated 3 times in 2 months. Serum LDH decreased rapidly to normal and the right adrenal tumor had completely vanished from the CT-scan and  $^{67}\text{Ga}$  scintigram after the second treatment (Fig. 4, 5). Complete response

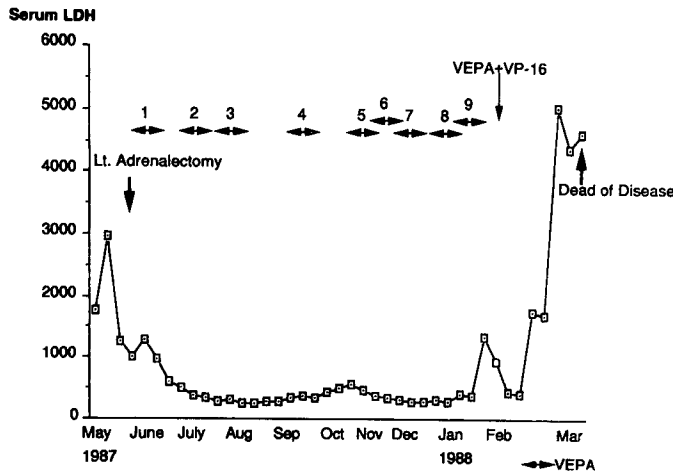


Fig. 6. Change of serum LDH during clinical course. (VEPA: multidrug chemotherapy consisted of vincristine, cyclophosphamide, doxorubicin and predonisone)

was maintained for 6 months, but adrenal hormone replacement (hydrocortisone 20 mg/day) could not be ceased. Six additional chemotherapy courses were given (Fig. 6), but multiple recurrence in the liver as well as rapid elevation of serum LDH was noted on the  $^{67}\text{Ga}$  scintigram taken in January, 1988. Further chemotherapy modified with VP-16 and others was ineffective, and the patient died on May 8, 1988. Postmortem examination was not done.

#### DISCUSSION

Malignant lymphoma originating from the adrenal gland is rare, and only 4 cases of bilateral lymphoma originating in the adrenal glands have been reported in the literature<sup>5-8</sup>). Cases of bilateral malignancies in the adrenal gland are rarely accompanied by adrenal insufficiency<sup>9</sup>). However, 4 of the 5 cases including our case (80%) presented with adrenal insufficiency. Therefore, in patients with bilateral adrenal masses with adrenal insufficiency, the differential diagnosis should include malignant lymphoma. It is of interest that a case reported by Carey et al.<sup>8</sup>) was represented as an instance of reversal of Addison's disease after antineoplastic therapy. Schnitzer et al.<sup>7</sup>) reported the first case of T-cell lymphoma of the adrenal

glands based on careful immunochemical examination. Our case is the first case to show immunohistological evidence of B-cell origin lymphoma.

Considering the high mortality rate of non-complete responders with malignant lymphoma, it is undoubtedly important to obtain a complete response in the initial stage. In spite of better CR rates obtained with current chemotherapy, full dose chemotherapy is not often completed because of the patients' high age and poor condition. Also this fact means limiting CR rate of this order. Therefore, before the intensive chemotherapy, it is of value to reduce the cancer volume when it presents with a large mass. Although surgery is generally not considered curative for malignant lymphoma because of its systemic nature, surgical procedure is effective for reducing cancer volume as well as establishing the correct diagnosis. In our case, we could reduce the tumor volume by half and could gain complete response for 6 months with subsequent combined chemotherapy, offering palliation with minimum morbidity. In conclusion, we recommend surgical procedure with subsequent chemotherapy as an effective method for selected cases of malignant lymphoma, especially those with large masses.

## REFERENCES

- 1) Whitmore WF, Skarin AT and Rosenthal DS: Urological presentations of non-Hodgkin's lymphoma. *J Urol* **128**: 953-956, 1982
- 2) Miyake O, Namiki M, Sonoda T, et al.: Secondary involvement of genitourinary organs in malignant lymphoma. *Urol Int* **42**: 360-362, 1987
- 3) The non-Hodgkin's lymphoma pathologic classification project. National Cancer Institute sponsored study of classifications of non-Hodgkin's lymphomas. Summary and description of a working formulation for clinical usage. *Cancer* **49**: 2112-2135, 1982
- 4) Hsu SM, Raine L and Frang H: Use of avidin-biotin-peroxidase complex (ABC) in immunoperoxidase techniques. A comparison between ABC and unlabeled antibody (PAP) procedures. *J Histochem Cytochem* **29**: 577-580, 1981
- 5) Shea TC, Spark R, Kane B, et al.: Non-Hodgkin's lymphoma limited to the adrenal gland with adrenal insufficiency. *Am J Med* **78**: 711-714, 1985
- 6) Feldberg MAM, Hendriks MJ and Klinkhamer AC: Massive bilateral non-Hodgkin's lymphoma of the adrenals. *Urol Radiol* **8**: 85-88, 1986
- 7) Schnitzer B, Smid D and Lloyd RV: Primary T-cell lymphoma of the adrenal glands with adrenal insufficiency. *Hum Pathol* **17**: 634-636, 1986
- 8) Carey RW, Harris N and Kliman B: Addison's disease secondary to lymphomatous infiltration of the adrenal glands. *Cancer* **59**: 1087-1090, 1987
- 9) Mersey JH, Bowers B, Jezic DV, et al.: Adrenal insufficiency due to invasion by lymphoma: Documentation by CT scan. *South Med J* **79**: 71-73, 1986

(Received on April 15, 1991)  
(Accepted on June 19, 1991)

## 和文抄録

## 副腎不全を伴った両側副腎原発非ホジキンリンパ腫の1例

住友病院泌尿器科 (部長: 板谷宏彬)

宇都宮正登, 高寺 博史, 伊藤 博, 板谷 宏彬

住友病院病理部 (部長: 辻村崇浩)

辻 村 崇 浩

腎不全を伴った両側副腎原発非ホジキンリンパ腫を経験した。手術により左側腫瘍を摘出し、病理診断にて非ホジキンリンパ腫 (diffuse large B-cell lymphoma) をえたため、術後 vincristine, cyclophosphamide, doxorubicin を用い、化学療法を行い、2クール終了時に完全寛解をみた。CR は6カ月持続したが、肝および全身に再発し、約1年にて死亡

した。文献上両側副腎原発非ホジキンリンパ腫は本症例を含め、5例であり、きわめて稀な疾患であり、巨大腫瘍を形成する症例において、手術的に腫瘍細胞を減少させることは、その後の化学療法を施行するうえで、有効であると考えられた。

(泌尿紀要 **38**: 311-314, 1992)