

Title	Emphysematous cystitis: report of a case
Author(s)	Kim, Chol Jang; Pak, Kyun; Kounami, Teruo; Tomoyoshi, Tadao
Citation	泌尿器科紀要 (1991), 37(12): 1711-1713
Issue Date	1991-12
URL	http://hdl.handle.net/2433/117410
Right	
Type	Departmental Bulletin Paper
Textversion	publisher

EMPHYSEMATOUS CYSTITIS: REPORT OF A CASE

Chol Jang Kim, Kyun Pak, Teruo Kounami and Tadao Tomoyoshi

From the Department of Urology, Shiga University of Medical Science

Emphysematous cystitis is characterized by gas collection within the bladder wall and lumen. A case of emphysematous cystitis in a 74-year-old diabetic male is reported. Radiogram demonstrated an enlarged bladder with intraluminal gas.

(Acta Urol. Jpn. 37: 1711-1713, 1991)

Key word: Emphysematous cystitis, CT scan Diabetes mellitus

INTRODUCTION

Emphysematous cystitis is a rare condition characterized by gas in the bladder wall. However, gas may be found occasionally in the bladder lumen. We describe a case of a large gas-filled bladder.

CASE REPORT

The patient was a 74-year-old male who was pointed out as having diabetes mellitus 7 years earlier, but had not been treated. He had been complaining of constipation for a few months. Therefore, he underwent barium enema in August, 1987. At that time, the markedly distended bladder with gas was demonstrated, but no abnormality was found in the large bowel. He was referred to our department in September, 1987. He never noted troubles on urination. The patient had never received transurethral catheterization. Physical examination was unremarkable except for distended lower abdomen, tympanic on percussion. Digital examination of the prostate revealed no enlargement. Urinalysis showed a negative test for protein and sugar. Many white blood cells per high-power field were identified in the sediment and urine culture yielded *Pseudomonas aeruginosa* and γ -Streptococcus. Fasting blood sugar value was 126 mg/dl. An abdominal plain x-ray film in supine position showed a large gas shadow in the lower abdomen (Fig. 1). On an upright plain film, the air-fluid level was identified (Fig. 2). Excretory urograms showed a large bladder and left contracted kidney.

Voiding cystograms demonstrated no vesicoureteral reflux. CT scan revealed gas

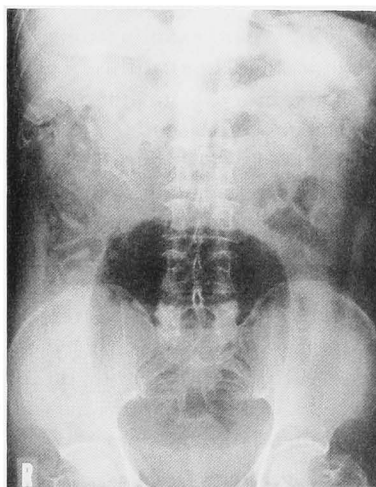


Fig. 1. KUB showing the distended gas-filled bladder.

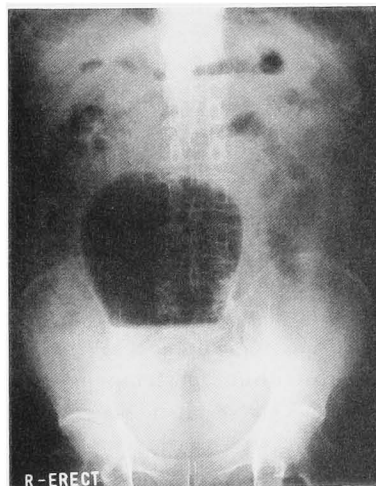


Fig. 2. Plain upright film showing the characteristic air-fluid level.

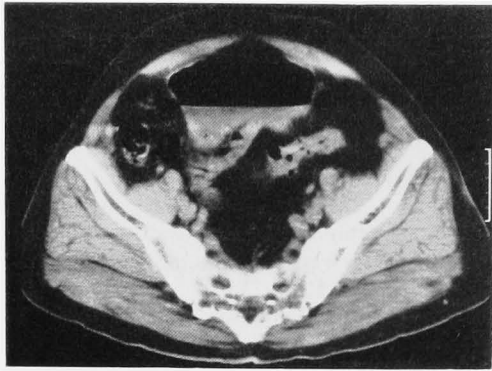


Fig. 3. CT scan reveals gas in the lumen of bladder.

with an air-fluid level in the bladder (Fig. 3). There was no detectable intramural gas on radiographic examinations. Cystoscopy demonstrated a diffuse hyperemic change of the mucosa and the intraluminal gas, but no gas-filled vesicles in the mucosa were detected. Cystometrogram demonstrated a hypotonic bladder probably due to diabetic neuropathy, and vesical capacity was 1,040 ml. Residual urine volume was 860 ml. Therefore, clean intermittent self-catheterization was instructed.

Appropriate chemotherapy led to negative urine cultures and gas in the bladder disappeared. The diabetes was well controlled by dietary management.

DISCUSSION

Emphysematous cystitis was first reported by Eisenlohr¹⁾ in 1888. It is a rare condition most commonly seen in patients with diabetes mellitus. Holesh found that, out of the 118 cases of emphysematous cystitis in the literature, 58 patients were diabetic²⁾. Intramural and intraluminal gas in emphysematous cystitis is believed to be the end product of glucose fermentation by infecting microorganisms³⁾. The most frequent pathogen is *E. coli*, but *Klebsiella pneumoniae*, *Proteus mirabilis*, *Staphylococcus aureus*, *Streptococcal* species, *Neisseria*, *Clostridium perfringens* and *Candida albicans* have also been reported⁴⁾. The symptoms are similar to cystitis, and pneumaturia seems to be occasionally characteristic.

In our case, gas was present in the blad-

der, but not in the bladder wall. Bailey reported that, out of the 19 cases of emphysematous cystitis, 11 cases had both intramural and intraluminal gas, 6 cases had only intraluminal gas, and 2 cases had only intramural gas⁵⁾. It seems that intramural and intraluminal gases are different and occasionally derived from concomitant stages of emphysematous cystitis. Etiologic factors of these conditions seem to be the same, and they are transient⁵⁾.

The radiographic appearances of emphysematous cystitis are as follows: (a) localized cluster of gas-filled vesicles within the bladder wall early in the process, (b) a ring of gas partially or completely surrounding the bladder, (c) thickened irregular or nodular appearance of the bladder wall, (d) intraluminal gas, and (e) perivesical gas extension⁶⁾. Thus the radiographic diagnosis of emphysematous cystitis is based mainly on the detection of the gas. Although CT scan is a very useful mean of demonstrating the location of the gas, the location of the gas associated with emphysematous cystitis can be easily diagnosed by lateral and oblique projections on abdominal plain x-ray film with excretory urograms.

REFERENCES

- 1) Eisenlohr W: Das interstitielle Vagina-Darm und Harnblasenemphysem zurückgeführt auf gasentwickelnde Bakterien. *Beitr Anat Path* 3: 101-156, 1888
- 2) Holesh S: Gas in the bladder cystitis emphysematosa. *Clin Radiol* 20: 234-236, 1969
- 3) Singh CR and Lytle WF Jr: Cystitis emphysematosa caused by *Candida albicans*. *J Urol* 130: 1171-1173, 1983
- 4) West TE, Holley HP Jr and Lauer AD: Emphysematous cystitis due to *Clostridium perfringens*. *JAMA* 241: 363-364, 1981
- 5) Bailey H: Cystitis emphysematosa. 19 cases with intraluminal and interstitial collections of gas. *Am J Roentgenol* 86: 850-862, 1961
- 6) Clayman RV, Weyman PJ and Bahnson RR: Inflammation of the bladder. In: *Clinical Urography*. Edited by Pollack HM. 1st ed., Vol. 1, pp. 902-924, W.B. Saunders, Philadelphia, 1990

(Received on January 18, 1991)
(Accepted on March 4, 1991)

和文抄録

気腫性膀胱炎の1例

滋賀医科大学医学部泌尿器科学講座（主任：友吉唯夫教授）

金 哲將，朴 勺，神波 照夫，友吉 唯夫

気腫性膀胱炎は，膀胱壁内と腔内にガスが存在することにより特徴づけられる疾患である．74歳の糖尿病を伴った男性にみられた，気腫性膀胱炎の1例を報告

する．レントゲン検査で，腔内にガスを伴った拡張した膀胱が確認された．

（泌尿紀要 37：1711-1713, 1991）