

Title	Subcostal transabdominal incision with midline extension for tumors of the kidney, adrenal gland or retroperitoneal cavity
Author(s)	Kano, Ken-ichi; Saito, Kazuhide; Go, Hideto; Katayama, Yasushi; Tanikawa, Toshiki; Sato, Shotaro; Uehara, Tohru; Morishita, Hideo
Citation	泌尿器科紀要 (1991), 37(11): 1471-1474
Issue Date	1991-11
URL	<a href="http://hdl.handle.net/2433/117370">http://hdl.handle.net/2433/117370</a>
Right	
Type	Departmental Bulletin Paper
Textversion	publisher

## SUBCOSTAL TRANSABDOMINAL INCISION WITH MIDLINE EXTENSION FOR TUMORS OF THE KIDNEY, ADRENAL GLAND OR RETROPERITONEAL CAVITY

Ken-ichi Kano, Kazuhide Saito, Hideto Go,  
Yasushi Katayama Toshiki Tanikawa and Shotaro Sato  
*From the Department of Urology, Niigata University School of Medicine*

Tohru Uehara  
*From the Department of Urology, Tachikawa General Hospital*

Hideo Morishita  
*From the Department of Urology, Nagaoka Red Cross Hospital*

Subcostal transabdominal incision with midline extension is excellent for removal of large renal or adrenal tumors, or bilateral or retroperitoneal tumors. This incision is simple and gives a wide surgical field without involving the pleural cavity. No troublesome complications resulting from this approach have occurred.

(Acta Urol. Jpn. 37: 1471-1474, 1991)

**Key words:** Renal tumor, Adrenal tumor, Retroperitoneal tumor, Subcostal transabdominal approach with midline extension

### INTRODUCTION

Surgical approaches for tumors of the kidney, adrenal gland or retroperitoneal cavity do not always follow a common pattern. Up to now, three approaches for renal tumor and four adrenal or retroperitoneal tumors have generally been employed. All of these approaches have their merits and demerits. Although skilled surgeons can freely use these approaches, others generally practice their own favorite method. We report herein a method for subcostal transabdominal incision with midline extension for tumors of the kidney, adrenal gland or retroperitoneal cavity.

### PATIENTS AND METHODS

Between January, 1980 and December, 1989, 27 patients, 16 males and 11 females, ranging in age from 14 to 79 years, with renal cancer, adrenal or retroperitoneal tumors were operated on using a subcostal transabdominal incision with midline ex-

ension.

Each patient was placed on the operating table in a supine position. The table was flexed slightly, or a thin cushion was inserted under the lumbar region to elevate the waist. An incision was made from the middle axillary line to the lateral margin of the opposite rectus muscle through the median line between the navel and the xiphoid process. In the case of bilateral adrenal tumors, a transverse incision was made from the tip of the eleventh rib to that of the opposite one. After dividing the skin, the peritoneal cavity was opened and the ligamentum teres was divided, followed by a midline extension to the xiphoid process (Fig. 1). The process was resected if the surgical field was insufficient, and a hook was placed at the margin of the subcostal arch. Thus a wide surgical field was provided.

### RESULTS

The operation proceeded after completion of the incision, and the overall results

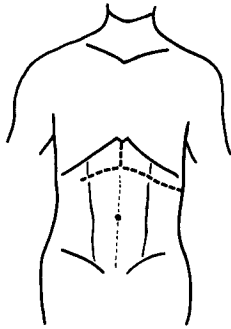


Fig. 1. Subcostal transabdominal approach with midline extension, in the case of a tumor located on the left side.

obtained were as follows. The operation time and intraoperative blood loss varied because of differences in the sites, sizes, stages and vascularity of the tumors, being 2 h 25 min~16 h 36 min (average 6 h 10 min) and 105~3,300 ml (average 832 ml), respectively. Three operations lasted over 12 h. Of these three, case 14 was bilateral adrenal pheochromocytoma and a pancreatic head tumor, for which a histological diagnosis of islet cell cancer was made. The patient was the father of the patient in case 20, who also had bilateral pheochromocytoma and a pancreatic tail tumor. The maximum blood loss during surgery was 3,300 ml in case 8, which was a recurrence of left adrenal pheochromocytoma. Paralytic ileus occurred in two cases, but this was alleviated within a few days. Wound healing was satisfactory. Resuture was not needed, although the wound partly gaped in two cases. Hypoalbuminemia due to lymphorrhea occurred in two cases.

With regard to diet, it took 3 to 20 days (average 6.4 days) until resumption of food intake after the operation. In case 14, 20 days passed until administration of food. Patients were bedridden from 4 to 40 days (average 9.9 days).

#### DISCUSSION

Existing approaches for renal or adrenal tumors are as follows;

1. Flank approach
2. Transabdominal approach (including

several variations)

3. Thoracoabdominal approach
4. Posterior approach

Of these approaches, the flank, transabdominal and thoracoabdominal ones are common, but the posterior approach is used exclusively for adrenal tumor.

The choice of incision for renal and adrenal tumors is determined by the patient's body habitus and by the position, mobility and number of kidney or adrenal glands involved. As the transabdominal approach has become commonly used, a subcostal transabdominal incision has been preferred over the last ten years at our clinic for renal, adrenal<sup>1)</sup> or retroperitoneal tumors. In the case of large renal or adrenal tumors, and bilateral adrenal or retroperitoneal tumors, the incision is followed by a midline extension to the xiphoid process. Isaka et al. recommended this approach for upper pole tumor of the right kidney, right adrenal tumor or inferior vena cava thrombus from renal cancer<sup>2)</sup>. The advantage of this incision is that a wide surgical field is provided without involving the pleural cavity. On the other hand, a midline incision was employed in only two cases because it was more difficult to perform on the lateral side of the tumor compared with the subcostal transabdominal incision. In the case of tumor thrombus beyond the level of the hepatic vein, the midline extension can easily be lengthened by median sternotomy in order to approach the supradiaphragmatic vena cava. In our patients, vena cavectomy and patch grafting of the vena cava were performed in case 3 and 4, respectively. The average number of days the patient was bedridden after treatment using a subcostal transabdominal incision with midline extension was 9.9 days, and that after a flank oblique incision was 5.8. The difference however, is not significant because the former was generally employed on large, bilateral or double tumors and others while the latter was used for small ones.

The patient data are briefly shown in Table 1, since they do not concern the

Table 1. Patients operated on using a subcostal transabdominal approach with midline extension

Case No.	Patient		Diagnosis	Operation time (h.m)	Blood loss (ml)	Weight of tumor (g)	Remarks
	Age	Sex					
1	42	M	rt. renal cancer	6.15	855	220	
2	26	M	bilat. adrenal pheochromocytoma	6.07	1,000	L. 9 R. 22	Lung edema
3	24	M	retroperitoneal ganglioneurinoma	10.25	846	140	Vena cavectomy for the thrombus.
4	48	M	lt. renal cancer rt. adrenal pheochromocytoma	12.09	2,665	340 1,180	Intracaval thrombus originated from the rt. adrenal vein. Patch grafting of the vena cava.
5	52	M	rt. renal cancer	5.25	240	232	
6	65	M	retroperitoneal neurinoma	4.22	550	11.5	
7	52	F	rt. renal cancer	6.00	800	2,125	
8	58	F	recurrence of pheochromocytoma (para-aorta)	12.08	3,300	45	Hypoalbuminemia after the operation. Lt. adrenalectomy in 1977.
9	15	M	rt. benign cystic multilocular nephroblastoma	5.14	300	1,150	
10	39	F	rt. adrenal pheochromocytoma	2.25	400	160	
11	55	F	lt. adrenal pheochromocytoma	4.45	615	1,100 (with kidney)	
12	71	F	lt. adrenal pheochromocytoma	4.25	817	35	
13	79	F	rt. renal cancer	3.36	910	200	Paralytic ileus
14	43	M	bilat. adrenal pheochromocytoma a pancreatic head tumor	16.36	1,600	L. 38	No operation for the rt. adrenal tumor. Pancreaticoduodenectomy
15	48	M	lt. adrenal pheochromocytoma	4.27	150	4	Thyroidectomy on March, 1988
16	74	F	rt. adrenal pheochromocytoma	5.16	601	19	
17	53	M	rt. adrenal pheochromocytoma	4.30	357	28	Paralytic ileus
18	56	M	rt. adrenal cortical cancer	3.38	750	140	Died on March 1989.
19	51	F	lt. renal cancer	3.51	836	620	
20	14	M	bilat. adrenal pheochromocytoma a pancreatic tail tumor	7.45	223	L. 2.5 R. 19	Removal of a pancreatic tumor. Son of pt. No. 14.
21	27	F	bilat. adrenal pheochromocytoma	6.58	955	L. 81 R. 40	Associated with thyroid tumor.
22	58	M	lt. renal cancer	5.24	500	1,250	Hypoalbuminemia after the operation.
23	65	F	rt. renal cancer	5.35	642	1,300	
24	60	M	lt. renal cancer	4.44	732	620	
25	68	F	lt. renal cancer	4.41	908	800	
26	78	M	rt. adrenal cortical cancer (non-functioning)	2.54	105	---	Probe lapalotomy Died on February 1990.
27	77	M	rt. renal cancer	6.54	800	380	Cholecystectomy

incision but rather the subsequent operations. Cases 14 and 20 were father and son. Although the incidence of familial pheochromocytoma with carcinoma arising from the pancreas islet is very low<sup>3,4)</sup>, the existence of pancreatic tumor should be taken into consideration at the time of surgery. With regard to this approach, ileus usually becomes an issue. In this study, mild paralytic ileus occurred in two cases, and thus the incidence was lower than expected. Hypoalbuminemia occurred in case 8, and was not alleviated before the patient's discharge.

#### REFERENCES

1) Kano K, Takeda M, Yoshimizu A, et al. :

Thirty-two cases of pheochromocytoma and their surgical management. *Endocr Surg* 7: 253-258, 1990

- 2) Isaka S, Okano T, Miyauchi T, et al. : A new operative approach for right renal cancer or right adrenal tumor; Liver mobilization method. *Jpn J Clin Urol* 40: 999-1002, 1986
- 3) Hull MT, Warfel KA, Muller J, et al. : Familial islet cell tumors in von Hippel-Lindau's disease. *Cancer* 44: 1523-1526, 1979
- 4) Carney JA, Go VLW, Gordon H, et al. : Familial pheochromocytoma and islet cell tumor of the pancreas. *Amer J Med* 66: 515-521, 1980

(Received on December 12, 1990)  
(Accepted on March 4, 1991)

#### 和文抄録

### 腎、副腎および後腹膜腫瘍に対する垂直切開を加えた上腹部横切開法

新潟大学医学部泌尿器科学教室 (主任: 佐藤昭太郎教授)

狩野 健一, 斉藤 和英, 郷 秀人

片山 靖士, 谷川 俊貴, 佐藤昭太郎

立川総合病院泌尿器科 (医長: 上原 徹)

上 原 徹

長岡赤十字病院泌尿器科 (部長: 森下英夫)

森 下 英 夫

上腹部横切開に垂直切開を加えた切開法は腎腫瘍、副腎腫瘍あるいは後腹膜腫瘍の手術の際に用いる胸膜を開くことなく広い術野が得られるという利点があった。新大泌尿器科では1980～1989年の10年間に27例に対してこの切開法を用いた。この方法は腹腔を経由す

るので、後腹膜腔から入る方法に比し合併症が多いように思われたが、2例に軽い麻痺性イレウスが発生したのみであった。また、再手術を要するような重篤な合併症は生じなかった。

(泌尿紀要 37: 1471-1474, 1991)