

Title	A case large protruding cystitis glandularis: clinical, histological and mucin-histochemical study
Author(s)	Kushima, Mayumi; Konishi, Taira; Konami, Teruo; Okada, Yusaku; Tomoyoshi, Tadao; Kushima, Ryoji P.; Hattori, Takanori
Citation	泌尿器科紀要 (1991), 37(10): 1313-1317
Issue Date	1991-10
URL	http://hdl.handle.net/2433/117306
Right	
Type	Departmental Bulletin Paper
Textversion	publisher

A CASE LARGE PROTRUDING CYSTITIS GLANDULARIS: CLINICAL, HISTOLOGICAL AND MUCIN-HISTOCHEMICAL STUDY

Mayumi Kushima, Taira Konishi, Teruo Konami,
Yusaku Okada and Tadao Tomoyoshi

From the Department of Urology, Shiga University of Medical Science

Ryoji P. Kushima and Takanori Hattori

From the Department of Pathology, Shiga University of Medical Science

A case of large protruding cystitis glandularis is reported. A 36-year-old man was admitted to our hospital due to acute cholecystitis, and large protruding masses were incidentally found in the urinary bladder by abdominal ultrasonography. The histological study revealed that they consisted of a large number of Brunn's nests with or without cysts which were often accompanied with columnar epithelial metaplasia, and of glandular structures closely resembling the colonic crypts. The mucin histochemical study demonstrated glandular lesions in the bladder secreted colonic type mucin, and endocrine cells positive with Grimelius' staining. A review of literature disclosed 19 clinical cases of cystitis glandularis, since 1970, in Japan, but such a large protruding lesion as this case is rare. We first performed detailed histological and mucin-histochemical studies for this clinical case.

(Acta Urol. Jpn. 37: 1313-1317, 1991)

Key words: Cystitis glandularis, Protruding lesion, Mucin-histochemistry

INTRODUCTION

Cystitis glandularis is one of the proliferative lesions which are commonly found in the urinary bladder¹⁾, but it does not usually show a large protruding lesion in the urinary bladder. Presence of mucin-secreting glandular structures, closely resembling colonic crypts, is well recognized as a metaplastic change.

We experienced a case of large protruding cystitis glandularis, and performed detailed histological and mucin-histochemical studies.

CASE REPORT

A 36-year-old man was admitted to the Department of Internal Medicine of our hospital in October 1988 due to acute cholecystitis. By abdominal ultrasonography, large protruding masses were incidentally found in the urinary bladder. After recovery from acute cholecystitis, he was transferred to the Department of Urology for the purpose of detailed examinations and

treatment for the vesical lesion on November 4, 1988. He had no urinary symptoms such as burning and difficulty on urination or hematuria.

Physical, hematological, and blood chemical examinations were within the normal limit. Urinalysis was normal and urinary cytology was negative. He had no difficulty in urination and no vesicoureteral reflux (VUR).

Excretory urography showed no hydronephrosis, but slight dilatation was seen in the lower portion of both ureters. On the urethrocytogram several filling defects of the urinary bladder were noted. CT scan demonstrated sessile protruding masses from the base of the bladder, but did not show any finding suggesting extravascular invasion. Enhanced CT scan in the prone position revealed the tip of the protruded mass enhanced strongly (Fig. 1).

Cystoscopy revealed several finger-sized nodular and sessile masses at the bladder neck and trigone, part of which showed a tower or a beak-like appearance (Fig. 2).

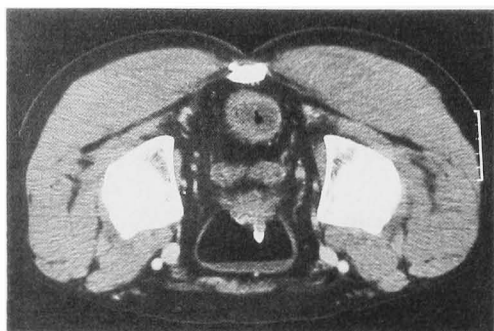


Fig. 1. Enhanced CT scan demonstrates a sessile protruding mass from the base of the urinary bladder and its tip is enhanced.

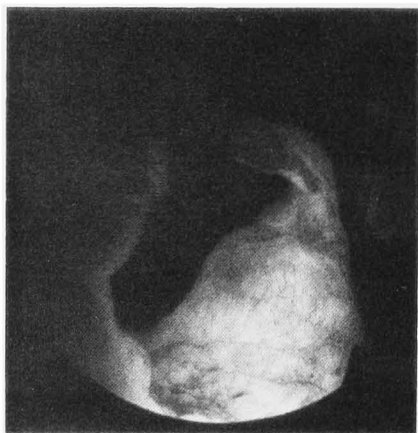

Fig. 2. Cystoscopy reveals some finger-sized sessile masses with a tower or beak-like appearance at the neck and trigone of urinary bladder.

The left ureteral orifice was not recognized due to the tumorous lesion. Biopsy of this lesion disclosed a cystitis glandularis with colonic-type gland formations. Transurethral resection of this benign lesion was performed on November 16, 1988. The border of the lesion was not so clearly identified.

Eight months after the first operation cystoscopy disclosed recurrence of similar masses at the trigone, and transurethral resection was performed again. Histopathological diagnosis was the same as the previous one without any malignant change. Six months after the second operation, cystoscopy disclosed recurrence at the trigone. Transurethral resection was performed for the third time.

PATHOLOGY

The tissue specimens were fixed in 10% formalin for 24 hours and embedded in paraffin. In addition to a routine hematoxylin and eosin staining, to clarify the exact character of the mucin secreted, we applied several specific mucin stainings as follows: (1) periodic acid-Schiff staining (PAS), (2) high iron diamine and alcian blue (pH 2.5) stainings (HID-AB)²⁾, (3) periodic acid-borohydride, potassium hydroxide and PAS stainings (PB-KOH-PAS)³⁾, (4) paradoxical concanavalin A for stable class III stainings (con A (III))⁴⁾. PAS stains non-specifically various kinds of mucin. By HID-AB, the mucin blue in color is sialomucin, and that black in color is sulphomucin. The mucin of the small intestine and colon is positive with HID-AB²⁾. PB-KOH-PAS indicated the presence of O-acetylated sialomucin, specific to the goblet cells of the colon³⁾. Con A (III) is specific to the gastric type mucin⁴⁾. We also applied Grimelius' staining to find endocrine cells⁵⁾.

Histologically, in the lamina propria of the urinary bladder, there were many Brunn's nests (Fig. 3a) with or without cysts, which were often accompanied with columnar epithelial metaplasia (Fig. 3b). Glandular structures, composed of goblet cells, were also seen to be scattered. They closely resembled colonic crypts (Fig. 3c). Neither adenomatous nor carcinomatous

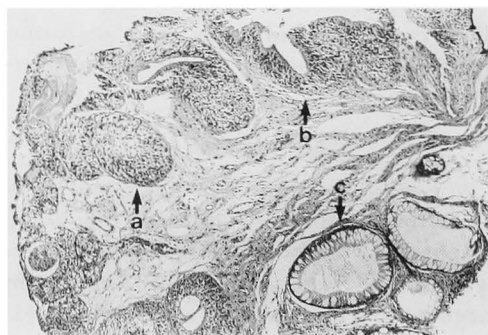


Fig. 3. a. Brunn's nests, b. Brunn's nests with cyst lined by columnar epithelial cells, c. Glands resembling colonic glands (H.E. stain)

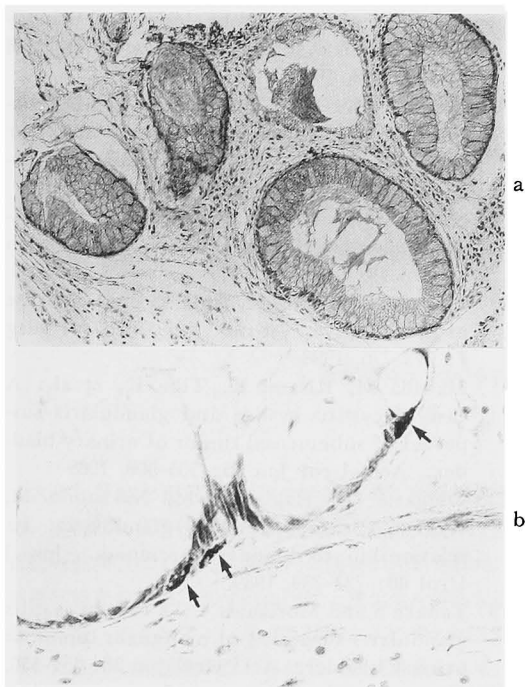


Fig. 4. a. Goblet cells positive with PB-KOH-PAS, b. Cells positive with Grimelius' staining

findings were seen in these cells. These goblet cells were positive with PAS, HID-AB, and PB-KOH-PAS (Fig. 4a). In HID-AB cells with sialomucin were nearly equal to those with sulphomucin. However, they were negative with con A (III). Brun's nests were negative with PAS, HID-AB, PB-KOH-PAS and con A (III). Columnar epithelial metaplasia in Brun's nests was slightly positive with PAS and HID-AB, but it was negative with PB-KOH-PAS and con A (III). Cells positive with Grimelius' staining were seen to be scattered in the glands (Fig. 4b) and in the Brun's nests.

DISCUSSION

Cystitis glandularis is one of the proliferative lesions commonly found in the urinary bladder. Ito et al. described that cystitis glandularis was found in 71% of the 125 autopsy cases of macroscopically normal-appearing urinary bladders of both sexes and all ages¹². On the other hand, including the present case, only 20 cases of cystitis glandularis with clinical symp-

toms or findings have been reported since 1970 in Japan⁶⁻¹⁴. Age distribution is from 6 to 80 years old with the average of 46 years, and it is more frequently seen in males than in females. Irritative symptoms of the bladder are most frequent and some have gross hematuria or difficulty in urination. The incidence of these symptoms is high in the bladder neck and trigone.

In Japan, detailed histological studies have not been reported for the clinical cases. Koss described that cystitis glandularis cannot be clearly differentiated from cystitis cystica. However, in cystitis glandularis, cells lining the glands may be cuboidal and resemble colonic epithelium with goblet cells¹⁵. According to WHO, this lesion is classified as glandular metaplasia (glandular "cystitis"), which is characterized by mucus containing columnar epithelial cells either on the surface or forming glands in the lamina propria¹⁶. Many authors have reported that these mucus containing cells are positive with PAS. However, PAS non-specifically stains various kinds of mucin. Therefore, we applied detailed mucin-staining as described above, to clarify the property of the mucin in the present case.

In this study, O-acetylated sialomucin was demonstrated in the goblet cells. Therefore, mucin of the goblet cells in cystitis glandularis was the same as that of the colon. Recently, Hamid et al. also demonstrated endocrine differentiation in inflamed urinary bladder epithelium with a metaplastic change⁵. By Grimelius' staining, we also found endocrine cells both in the colonic-type glands and Brun's nests. Therefore, this case also demonstrated that the bladder mucosa has a potential to change toward a more differentiated glandular structure of colonic type, via Brun's nests, as a mataplastic change.

Hasegawa et al. reported using the same method as ours that the colonic type mucin was demonstrated not only in cystitis glandularis in autopsy cases but also in half of the cases of mucin-producing adenocarcinomas of the bladder¹⁷. Wells et al. reported that adenocarcinoma of the

bladder associated with cystitis glandularis produced O-acetylated sialomucin, whereas a primary adenocarcinoma of urachal origin did not. Thus, they showed that PB-KOH-PAS may be used to differentiate primary adenocarcinomas from primary urachal carcinomas of the urinary bladder¹⁸⁾

These findings are not only very interesting to explain the histogenesis of the urinary bladder, but also suggest that cystitis glandularis is related to the development of adenocarcinoma in the urinary bladder. There are several reports on cystitis glandularis which underwent a malignant change during follow-up period of 5~15 years¹⁹⁻²¹⁾. On the other hand, it is evident, as systematically demonstrated by Ito et al.¹⁾ that cystitis glandularis is a very common autopsy finding. Clinically, Ohigashi et al. reported a case of cystitis glandularis followed for over 10 years without malignant changes¹²⁾.

As a clinical practice, the patient with cystitis glandularis must be placed on the risk chart, and prolonged close follow up is obligatory.

REFERENCES

- 1) Ito N, Hirose M, Shirai T, et al.: Lesions of the urinary bladder epithelium in 125 autopsy cases. *Acta Pathol Jpn* 31: 545-557, 1981
- 2) Spicer SS: Diamine methods for differentiating mucosubstances histochemically. *J Histochem Cytochem* 13: 211-234, 1965
- 3) Culling CFA and Reid PE: The histochemistry of colonic mucins. *J Histochem Cytochem* 27: 1177-1179, 1979
- 4) Katsuyama T and Spicer SS: Histochemical differentiation of complex carbohydrates with variants of the concanavalin A-horseradish peroxidase method. *J Histochem Cytochem* 26: 233-250, 1978
- 5) Hamid QA, Rode J, Flanagan AM, et al.: Endocrine differentiation in inflamed urinary bladder epithelium with metaplastic changes. *Virchows Archiv A Pathol Anat Histopathol* 412: 267-272, 1988
- 6) Moriyama N, Ito K, Mabuchi M, et al.: Two cases of cystitis glandularis. *Clin Urol* 33: 1013-1016, 1979
- 7) Iwasaki A, Hirokawa M, Iwamoto T, et al.: A report of an unusual case: An inflammatory and granulomatous lesion of urinary bladder with cystitis glandularis. *Clin Urol* 37: 935-938, 1983
- 8) Okamura K, Ito K, Suzuki Y, et al.: Histological study of cases of bladder cancer or chronic cystitis difficult to diagnose cystoscopically. *Acta Urol Jpn* 30: 459-465, 1984
- 9) Nishimoto K, Ono H and Hirayama M: Cystitis glandularis: A case report. *Nishinohon J Urol* 48: 907-910, 1986
- 10) Tajima M, Kuroda K, Kase T, et al.: A case of proliferative cystitis. *Jpn J of Urol Surg* 1: 773-776, 1988
- 11) Masuda M, Kitami K, Tiba K, et al.: A case of cystitis cystica and glandularis suspected of submucosal tumor of urinary bladder. *Acta Urol Jpn* 35: 505-508, 1989
- 12) Ohigashi T, Hagiwara M, Nakazono M, et al.: A case of cystitis glandularis. Its relationship to bladder carcinoma. *Jpn J Urol* 80: 737-739, 1989.
- 13) Tanaka S and Morikawa Y: A case of cystitis glandularis suspected of malignant tumor of urinary bladder. *Acta Urol Jpn* 36: 351-353, 1990
- 14) Tada M, Takemura S, Asai R, et al.: A case of cystitis glandularis in childhood. *Clin Urol* 44: 243-245, 1990
- 15) Koss LG: Tumors of the urinary bladder. *Atlas of Tumor Pathology. Armed Forces Institute of Pathology*, pp.6, Washington, 1975
- 16) Mostofi FK: Histological typing of urinary bladder tumors. *International Histological Classification of Tumors*, No. 10, pp.33, World Health Organization, Geneva, 1973
- 17) Hasegawa R, Fukuchima S, Hirose M, et al.: Histochemical demonstration of colonic type mucin in glandular metaplasia and adenocarcinoma of the human urinary bladder. *Acta Pathol Jpn* 37: 1097-1103, 1987
- 18) Wells M and Anderson K: Mucin histochemistry of cystitis glandularis and primary adenocarcinoma of the urinary bladder. *Arch Pathol Lab Med* 109: 59-61, 1985
- 19) Shaw JL, Gislason GJ and Imbriglia JE: Transition of cystitis glandularis to primary adenocarcinoma of the bladder. *J Urol* 79: 815-822, 1958
- 20) Susmano D, Rubenstein AB, Dakin AR, et al.: Cystitis glandularis and adenocarcinoma of the bladder. *J Urol* 105: 671-674, 1971
- 21) Edwards PD, Hurm RA and Jaeschke WH: Conversion of cystitis glandularis to adenocarcinoma. *J Urol* 108: 568-570, 1972

(Received on October 23, 1990)
(Accepted on December 27, 1990)

大きな腫瘍を形成した腺性膀胱炎の1例：臨床
的・組織学的・粘液組織化学的検討

滋賀医科大学泌尿器科学教室（主任：友吉唯夫教授）

九嶋麻優美，小西 平，神波 照夫

岡田 裕作，友吉 唯夫

滋賀医科大学病理学教室（主任：服部隆則教授）

九嶋 亮治，服部 隆則

大きな腫瘍を形成した腺性膀胱炎の1例を報告する。症例は36歳男性で急性胆嚢炎にて当院入院中，腹部超音波検査にて偶然に膀胱内に腫瘍が発見された。組織学検査の結果，部分的に円柱上皮化生を伴った嚢胞をもつ，多くのブルン巢と，結腸上皮にきわめて類似した多くの腺構造が認められた。粘液組織化学染色の結果，これらの腺は結腸型の粘液を分泌しており，

またグリメリウス染色陽性の内分泌細胞も認められた。本邦では1970年より今日までに19例の腺性膀胱炎の臨床例が報告されているが，本例のように大きな腫瘍を形成する例は少ない。また，臨床例に対して組織学的・粘液組織化学的に詳しい検討を加えたのは本例が初めてである。

（泌尿紀要 37：1313-1317，1991）