

Title	Non-specific granulomatous prostatitis treated with steroids
Author(s)	Saha, Pabitra Kumar; Hyakutake, Hiroyuki; Nomata, Koichiro; Yushita, Yoshiaki; Kanetake, Hiroshi; Saito, Yutaka
Citation	泌尿器科紀要 (1991), 37(8): 927-930
Issue Date	1991-08
URL	http://hdl.handle.net/2433/117242
Right	
Type	Departmental Bulletin Paper
Textversion	publisher

NON-SPECIFIC GRANULOMATOUS PROSTATITIS TREATED WITH STEROIDS

Pabitra Kumar Saha, Hiroyuki Hyakutake, Koichiro Nomata,
Yoshiaki Yushita, Hiroshi Kanetake and Yutaka Saito

From the Department of Urology, Nagasaki University School of Medicine

A case of non-specific granulomatous prostatitis is reported. The patient, who had a history of sudden onset of high fever and acute urinary retention, had a hard prostate on digital rectal examination that gave us an impression of prostatic cancer. Since repeated biopsy specimens from the prostate showed granuloma formation with fibrinoid necrosis, the case was diagnosed as non-specific granulomatous prostatitis. Steroid therapy promptly resolved clinical symptoms along with marked histopathologic improvement.

(Acta Urol. Jpn, 37: 927-930, 1991)

Key words: Granulomatous prostatitis, Prostatic carcinoma, Steroid therapy

INTRODUCTION

Granulomatous prostatitis is not so common as other inflammatory diseases of the prostate¹⁾, but this condition has clinical significance because of its frequent confusion with carcinoma of the prostate. The term granulomatous prostatitis was first used by Tanner and McDonald in 1943²⁾. This self limiting, chronic inflammatory lesion can be divided into two groups, specific and non-specific. Etiologic agents which produce specific granuloma include, *Mycobacterium tuberculosis*³⁾, *Coccidioidomycosis* and other fungi⁴⁾ and *Treponema pallidum*⁵⁾. The non-specific variety includes those without a demonstrable etiologic agent and that may be again divided into two types, allergic and non-allergic according to the abundance of eosinophils in the histopathologic study. The initial diagnosis of this case was prostatic cancer, but the histopathology of the prostate gland biopsy revealed granuloma formation with fibrinoid necrosis and no eosinophilic infiltration was observed. Our final diagnosis was non-specific granulomatous prostatitis of non-allergic type. The patient was treated with oral prednisolone therapy that showed dramatic improvement of symptoms. Repeat prostate biopsy was done three weeks after the steroid therapy which

showed marked regression of granuloma.

CASE REPORT

A 66-year-old man was referred to our department by his local physician because of a large, stony hard prostate and suspected malignancy. Two weeks earlier he had experienced high fever and acute urinary retention which had responded to chemotherapy. The patient also had a history of mild dysuria and decreased urinary stream of two years duration. The patient was well-nourished and well-developed. Digital rectal examination revealed asymmetrical prostate, the right lobe was enlarged and stony hard in consistency, thus resembling prostatic cancer. However, the left lobe was normal in size and consistency. The other results of the physical examination were within normal limit. In his past medical records, no history or evidence of allergic manifestation or tuberculosis could be elicited.

Significant laboratory investigations included: urinalysis, one to two white blood cells and two to three red blood cells per high powered field; urine culture was negative; the hemoglobin concentration; erythrocytes sedimentation rate; leukocytes count; blood urea; VDRL reaction for syphilis all were within normal limits. The differential leukocytes count were 62%

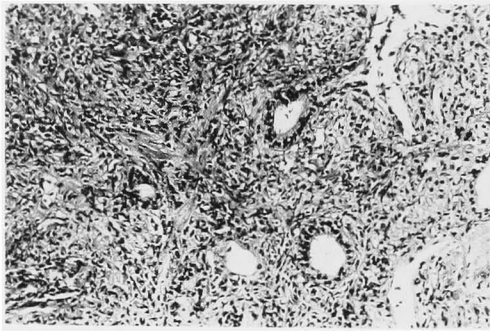


Fig. 1. Non-caseating granuloma with predominantly lymphocytic and plasma cell infiltration and giant cell component. H&E, reduced from $\times 100$

neutrophils, 25% lymphocytes, 11% monocytes, 1% eosinophils and 1% basophils. PPD testing for tuberculosis was negative and the chest appeared normal roentgenographically. The clinical diagnosis at the time of admission was prostatic cancer. Excretory urography revealed normal urinary tracts. The bladder showed minimal trabeculation with slight elevation of the bladder base urethrocytographically. Ultrasonography revealed slightly enlarged prostate, homogenous and intact capsule. Tumor markers for prostatic cancer were within the normal limit. Aspiration biopsy of the prostate was done several times but no evidence of malignancy was noted. Punch perineal biopsy of the prostate demonstrated a granulomatous lesion (Fig. 1). The final diagnosis was non-specific granulomatous prostatitis and oral prednisolone therapy was instituted with the following dose schedule: 30 mg in 3 divided doses for 4 days, 20 mg in 3 divided doses for 4 days, 15 mg in 3 divided doses for 4 days, 10 mg in 2 divided doses for 4 days and then 5 mg daily for two months. All the clinical symptoms disappeared within one week but the consistency of the prostate remained unaltered. Low dose steroid therapy was continued until digital rectal examination revealed complete normal prostate. After stopping steroid administration, we have followed the patient for four months. There has been no recurrence and the patient remains symptom free.

DISCUSSION

In our daily clinical practice, we rarely encounter granulomatous prostatitis. It is easy to confuse granulomatous prostatitis with carcinoma of the prostate especially during digital rectal examination of the prostate gland. Although tumor markers, like prostatic acid phosphatase (PAP), γ -seminoprotein (γ -SM) and additional investigations like urethrocytography⁵⁾, prostatic ultrasonography can help to solve confusion with prostatic cancer, aspiration biopsy and core biopsy of the prostate are invariably necessary to make final diagnosis of granulomatous prostatitis. In this case, histopathology of the biopsy specimen showed granuloma formation and presence of abundant neutrophils and lymphocytes but there was no remarkable eosinophilic infiltration. According to the etiology of granulomatous prostatitis various types of classification has been suggested by different authors¹⁻⁷⁾. Stillwell et al.⁷⁾ showed that 75% cases of granulomatous prostatitis had no notable etiology and classified them into non-specific granulomatous prostatitis. In the case of non-specific granulomatous prostatitis it is thought that blockage of prostatic duct by infection may cause extravasation of prostatic secretion or urine that incites foreign body type reaction and ultimately granuloma formation. Post TUR-P (transurethral resection of prostate) granulomatous prostatitis has been reported by several authors. In that case diathermy coagulation is thought to be initiated granulomatous prostatitis.

In this case, the initial clinical diagnosis was prostatic cancer. The tumor markers for prostatic cancer showed no abnormalities, but transrectal core biopsy of the prostate showed granuloma formation without any eosinophilic infiltration (Fig. 1). Our patient did not have any family history and we could not find out any evidence of tuberculosis or other infectious or allergic diseases. So, our final diagnosis was non-specific granulomatous prostatitis of non-allergic type.

The treatment of granulomatous prosta-



Fig. 2. Histology of the biopsy material taken after 3 weeks of steroid therapy, showing marked reduction of granuloma. H&E, reduced from $\times 40$

titis has been widely discussed. Most of the previous cases were treated by TUR-P. Successful treatment of granulomatous prostatitis with steroid was first described by Bush et al.⁸⁾ Although some reports have been made on the treatment of granulomatous prostatitis with steroids, little is mentioned about the dose schedule and time limit of steroid therapy. In this case, we started with steroid (prednisolone) therapy of 30 mg/day and tapered to 5 mg/day after about two weeks. The symptoms were improved within a few days but treatment with a low dose of steroids had to be continued for about two months for the complete improvement of clinical signs (digital rectal palpation of the prostate). Check prostate biopsy done after three weeks of steroid therapy showed regression of

granuloma (Fig. 2). We recommend steroid therapy for this self limiting, slowly progressive disease before attempting any aggressive treatment and the time limit of the steroid therapy should be decided by regular digital rectal examination of the prostate. It is better to continue low dose steroids as long as digital rectal examination reveals a normal prostate.

REFERENCES

- 1) Tuero JG, de la Campa JA, Lacort LP, et al. : Granulomatous prostatitis. *Urol Int* **43**: 97-101, 1988
 - 2) Tanner FH and McDonald TR. Granulomatous prostatitis. *Arch Pathol* **36**: 358-370, 1943
 - 3) Moore RA : Tuberculosis of the prostate gland. *J Urol* **37**: 372-384, 1937
 - 4) Gritti EJ, Cook FE and Spencer HB : Coccidioidomycosis granuloma of the prostate. A rare manifestation of the disseminated disease. *J Urol* **89**: 249-252, 1963
 - 5) Thompson L : Syphilis of the prostate. *Am J Syph* **4**: 323-331, 1920
 - 6) Ney C, Miller HL and Levy JL : Granulomatous prostatitis. *Urology* **11**: 320-323, 1983
 - 7) Stillwell TJ, Enger DE and Farrow GM : The clinical spectrum of granulomatous prostatitis. A review of 200 cases. *J Urol* **138**: 320-323, 1987
 - 8) Bush I, Orkin LA and Baufer S : Steroid therapy in non-specific granulomatous prostatitis. *J Urol* **92**: 303-306, 1964
- (Received on October 1, 1990)
(Accepted on November 27, 1990)

和文抄録

ステロイドに著効を示した非特異的肉芽腫性前立腺炎の1例

長崎大学医学部泌尿器科学教室（主任：斉藤 泰教授）

P. K. Saha, 百武 宏幸, 野俣浩一郎

湯下 芳明, 金武 洋, 斉藤 泰

前立腺の炎症性疾患のうち慢性肉芽腫性前立腺炎は稀であり、前立腺癌との鑑別で重要である。慢性肉芽腫性前立腺炎は specific と non-specific の2つに分けられ後者はさらに allergic と non-allergic に分類される。患者は66歳男性、排尿困難を主訴とし来院した。前立腺は触診上鶏卵大で両葉にわたり石様硬で前立腺癌が疑われた。繰り返し行われた針生検にて

fibrinoid necrosis を伴う肉芽形成をみとめ非特異的肉芽腫性前立腺炎と診断した。治療はステロイド内服にて劇的に症状の改善をみとめ、治療開始3週間後の前立腺生検にて肉芽の著しい改善をみたので報告する。

(泌尿紀要 37: 927-930, 1991)