

Title	Clinical results of tubeless cutaneous ureterostomy by Toyoda's method
Author(s)	Maruyama, Kunio; Yajima, Aiji; Torii, Takeshi; Naitoh, Yoshifumi; Toyoda, Yasushi; Ogawa, Hajime
Citation	泌尿器科紀要 (1991), 37(3): 243-248
Issue Date	1991-03
URL	http://hdl.handle.net/2433/117140
Right	
Type	Departmental Bulletin Paper
Textversion	publisher

CLINICAL RESULTS OF TUBELESS CUTANEOUS URETEROSTOMY BY TOYODA'S METHOD

Kunio Maruyama, Aiji Yajima, Takeshi Torii,
Yoshifumi Naitoh and Yasushi Toyoda

From the Department of Urology, Tokyo Metropolitan Hiroo General Hospital

Hajime Ogawa

From the Department of Urology, Social Insurance Tonan General Hospital

Tubeless cutaneous ureterostomy by Toyoda's method was conducted in 67 ureters from 43 patients during the last 9 years. Subjects included 30 males and 13 females, with an average age of 61.4 years. Most of them were afflicted with malignant tumors in the bladder, rectum, prostate, or uterus. For bilateral ureterostomy, the double-barrel method was performed in which the stoma was made at the same site in both the right and left ureters.

Among 60 ureters in which pre- and postoperative changes in the renal pelvis could be traced by IVP, satisfactory results were obtained in 16 of 20 ureters treated by unilateral surgery. Of the 40 ureters treated by the double-barrel method, moderate or severe pyeloectasis was observed in 3 of the 20 ureters on the side of the stoma, while moderate pyeloectasis was seen in 3 of 20 ureters of the side opposite the stoma, and severe pyeloectasis or loss of renal function was noted in 5. Thus, renal function on the side opposite the stoma was frequently influenced by the procedure. A patient who died of disseminated intravascular coagulation syndrome soon after the operation was excluded from analysis. Tubeless cutaneous ureterostomy could be conducted in 39 of 42 patients (92.8%), excluding one whose stoma and its periphery were covered with severe inflammatory granulation and 2 with ureteral constriction.

Key words: Tubeless cutaneous ureterostomy

INTRODUCTION

Continent urinary diversion using the intestine has been frequently performed in recent years. In addition, ileal conduit is also widely used. However, it is difficult to abandon traditional cutaneous ureterostomy in spite of its several defects, since the extent of surgical invasion is small and the procedure is simple. In this study, we examined the postoperative results of tubeless cutaneous ureterostomy conducted in 65 ureters from 42 patients, using Toyoda's method^{1,2)}, in which the surface of the skin is abraded and the ureter is implanted at the site of abrasion.

SUBJECTS

Sixty seven ureters from 43 patients who underwent tubeless cutaneous ureterostomy during the last 9 years were studied. The patients consisted of 30 males and 13 females, and their ages at the time of sur-

gery ranged from 35 to 78 years (average age, 61.4 years). Their underlying diseases included 24 cases of bladder cancer, 8 cases of rectal cancer, 3 cases of prostatic or uterine cancer, 2 cases of sigmoid colon cancer, and 1 case each of ureterostenosis, ovarian cancer, and gastric cancer.

Of the 67 ureters examined, unilateral ureterostomy was performed for 19 ureters, and bilateral ureterostomy for 48 ureters. Bilateral ureterostomy was conducted according to the double-barrel method, except for one case in which stomas were produced on the bilateral sides.

METHODS

Stripping of the ureter should be limited to the minimum required length. When orifices of the bilateral ureters are to be made at the same site, stomas should in principle be generated at the right side. The left ureter is directed to the right side via the retroperitoneal cavity above the in-

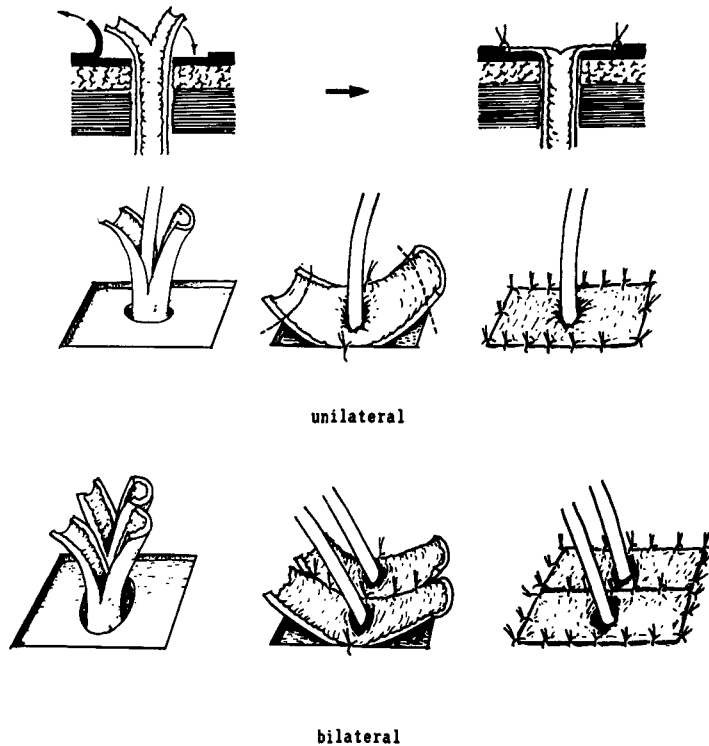


Fig. 1. Toyoda's method for tubeless cutaneous ureterostomy

ferior mesenteric artery. Separation of the retroperitoneum from the back wall is performed manually from the left and right sides, and a retroperitoneal cavity large enough for the width of two fingers is necessary. The left ureter is cut, avoiding the physiologically constricted part, and manipulated so that it is free from twists and excessive tension or looseness.

The position of the stoma should be marked on the skin before the operation at the best site for attachment of the urine bag. The height of the stoma will differ according to the patient's constitution, but the standard position is at the height of the navel near the front axillary line. At the site of the orifice of the ureter, a portion of skin corresponding to the diameter of the ureter is scooped out and the hole is rounded. In particular, the fascia should be excised with sufficient room. The size of the hole should correspond to the diameter of the index finger. What is important here is to provisionally suture the incisional wound on the abdominal wall

corresponding to the orifice site before making the hole. Otherwise, the ureter may not be straight when the surgical wound is closed, resulting in an unsuccessful operation. Moreover, since Gerota's fascia causes the ureter to bend, it should be severed without fail.

The stoma is formed in exact accordance with Toyoda's method^{1,2)} (Fig. 1). After making a hole on the abdominal wall, the ureter is pulled out, taking care to avoid twisting. The stump of the ureter is split longitudinally at 2 sites, avoiding the main vessels running along the ureter. We recommend that the splits be made relatively long, if possible, and that the stumps be cut after starting suturing so that they will fit the abraded surface.

Subsequently, a quadrilateral incision is made on the epidermis corresponding to the size of the split and unfolded 2 walls of the ureter, and the epidermis including the papillary layer is abraded to expose the dermis. However, practically speaking, only enough abrasion to cause slight exu-

dation of blood is required. Blood exudation can be readily stopped by pressing with gauze and so forth. An easy abrasion technique is to make shallow incisions with a sharp scalpel first, then to tear off the dermis by pulling up the fragment of the epidermis. Each side of the quadrilateral abraded area should be longer than the diameter of the ureter.

The inner edges of the two split ureter walls are sutured firmly to the skin using a round needle and thin nylon thread. Then, all the layers of the ureter are simply fitted to the edges of the epidermis. Excessive stumps should be cut and the four sides firmly fixed.

In the case of bilateral ureterostoma, double-barrel ureterostomy is generally conducted (Fig. 1). The walls of the two ureters are sutured first, and the above procedure is followed.

The splint catheter used should be thinner than the inner diameter of the ureter. The splint catheter should be removed as soon as possible, normally 2~5 days after the operation, depending on the postoperative course of the patient. Although the nylon thread is difficult to remove, complete removal is not always required: removal of only the interfering ends of the thread is sufficient.

RESULTS

The postoperative results of tubeless cutaneous ureterostomy by Toyoda's method were examined in 65 ureters from 42 patients. One patient who died from disseminated intravascular coagulation syndrome soon after the operation was excluded. Changes in preoperative and postoperative images of the pelvis in 60 ureters which could be traced by IVP are shown in Table 1, with the degree of renal pelvis expansion (Fig. 2) used as a standard.

Among the 20 ureters treated unilaterally (including one case in which stomas were made on both sides), the pre- and postoperative courses were normal in 6 ureters without expansion of the renal pelvis; the expanded renal pelvis before operation was normalized or improved af-

Table 1. Changes in renal pelvis IVP images
*...Renal function was almost completely lost.

	preop.	postop.	No. of ureters	
unilateral (20 ureters)	N	N	6	
	N	A	2	
	N	B C	1	
	N	C	1	
	A	N	2	
	A	B	1	
	A	C	1	
	A B	N A	1	
	B	N A	1	
	B C	A B	1	
	C	N	1	
	C	N A	2	
	bilateral (40 ureters)	N	N	10
		N	N A	2
N		A	3	
N		B	1	
N		C	2	
N A		N	1	
B C		N A	1	
opposite side		N	N	7
		N	N A	1
		N	A	2
		N	B	4
		N	C	1
		N	*	4
		B	C	1

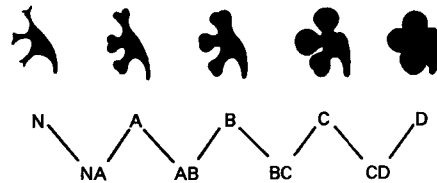


Fig. 2. Criteria for evaluation of the extent of renal pelvis expansion

N: Normal A: The vaulted part of the calix is deformed but retains the scyphoid shape. B: The entire calix is deformed, and moderate expansion is observed in the cervical part of the calix and in the renal pelvis. C: The calix, cervical part of the calix, and renal pelvis are all greatly expanded, but their mutual relationship and arrangement remain normal. D: The calix and renal pelvis are further expanded and large round images are shown. Their relationship and arrangement have become obscure. NA: Intermediate between N and A. AB: Intermediate between A and B. The same shall apply hereafter.

ter operation in 8 ureters; and the renal pelvis showed slight, moderate or large expansion after operation in 2 ureters each.

With respect to the 40 ureters treated with the double-barrel method, 10 on the side of the stoma followed normal pre- and postoperative courses without expansion of the renal pelvis. The expanded renal pelvis was improved by operation in 2 ureters on the side of the stoma, while the renal pelvis was expanded slightly, moderately, and largely after operation in 5, 1 and 2 ureters on the side of the stoma, respectively.

In ureters opposite the stoma, expansion of the renal pelvis was not noted before or after operation in 7 ureters. The renal pelvis was expanded slightly, moderately, and largely in 4, 3 and 2 ureters, respectively, and renal function was almost completely lost in 4 ureters. However, CT scan indicated that the loss of renal function in 1 of these 4 ureters was due to lymph node metastasis in the renal hilus.

Temporary expansion of the renal pelvis presumably caused by edema in the ureter is commonly seen during the postoperative course. When the postoperative courses of 25 ureters with a normal preoperative renal pelvis were examined by IVP until images of the renal pelvis returned to normal, expansion of the renal pelvis was observed between 2 weeks and 2 months after operation, but was normalized 4 to 10 months later at IVP.

As a result, a case treated by exenteration of all the organs of the pelvis in which the peripheral area of the stoma was covered with inflammatory granulation and one of ureterostenosis in the muscular tunics of the abdominal wall after total cystectomy were controlled by nephrostomy. In addition, the catheter was inserted to ureter for ureterostenosis in a case treated by unilateral operation. Consequently, 39 of 42 cases (92.8%), with these 3 cases excluded, could be treated by tubeless cutaneous ureterostomy. In one case, the surface of the stoma was covered with the epithelium of skin to form a pinhole-like

shape, which could be resolved by simple dilation.

DISCUSSION

Cutaneous ureterostomy has a history of nearly one century. The first completely successful tubeless cutaneous ureterostomy was reported by Colby⁵⁾ in 1942. He employed a technique similar to the one presently called the everted nipple method. Before then, it was usual not to remove the catheter. In the 1960s, many new tubeless techniques were reported, and the term "cutaneous ureterostomy" came to imply tubeless methods. However, improvement of the urine collecting apparatus played a major role in the spread of the tubeless technique.

The most important characteristic of Toyoda's method^{1,2)} reported in 1975 is that it is best for conditions likely to achieve primary cure. In this method, the external wall of the ureter and the epidermis-abraded skin adhere to each other over a broad range, with no dead space, and the sutured part is in the same plane. Firm fixation is possible because many suture sites can be distributed in the terminal part of the ureter, and the base is also secure. It is not necessary to bind any sites other than the ureteral stump with thread. Concerning the problem of blood supply, the vascular network of the dermis and the mesh of fine vessels in the ureteral external wall come into contact⁶⁾, and as a result, the epidermis of the skin corresponding to the external wall of the ureteral stump is abraded and excised, including the upper layer of the dermis. This procedure is useful for adhesion of the ureteral wall and dermis. In fact, even if the mucosal surface is necrotic, it will regenerate and cause almost no constriction of the stoma. The technical procedure of Toyoda's method is very simple, because the only new addition is abrasion of the epidermis to the level of the dermis. Consequently, we have experienced no cases of loss or necrosis at the stoma. One defect, however, is the lack of nipple formation.

We obtained satisfactory results with unilateral ureterostomy by Toyoda's method in all except 4 of 20 ureters. The double-barrel method inevitably had a major influence on renal function for 5 ureters in the side opposite the stoma. Severe pyeloectasis occurred in 2 of 20 ureters, and renal function was lost in 3 ureters (25%). By contrast, only 3 ureters (15%) were influenced in the side of the stoma, where moderate pyeloectasis was observed. This result seems to be attributable to factors other than the stoma as well, because the abraded area was larger in the opposite ureter than in the one on the side of the stoma, because no interruption in blood circulation occurred, and because the opposite ureter should pass over the aorta and spine in the retroperitoneal cavity.

Constriction on the skin level was found in only 2 cases, including 1 in which constriction reached the muscular layer.

The squamous epithelium of the skin has been said to cover the mucosal membrane and the stoma to form a pinhole-like shape, unless the nipple is formed. This phenomenon was observed in only 1 of our cases, far fewer than expected, although further techniques may be required to solve this problem. However, if complete primary cure is achieved, constriction is not considered severe enough to require an indwelling catheter, despite the pinhole-like changes in the epidermis.

Indications for cutaneous ureterostomy

are judged on the basis of the type of surgery: unilateral or bilateral, age, prognosis, patient risk, intestinal condition, influence of later treatments such as radiation, and extent of ureteral expansion. When the quality of life of the patient is considered in urinary diversion, the technique of continent urinary diversion should be selected if proper conditions prevail. However, tubeless cutaneous ureterostomy is still worthwhile because of its simplicity, and lighter burden for the patient.

REFERENCES

- 1) Toyoda Y and Shibaki K: Trials on cutaneous ureterostomy. (In Japanese) *Jpn J Urol* **66**: 212, 1975
- 2) Toyoda Y: A new technique for catheterless cutaneous ureterostomy. *J Urol* **117**: 276-278, 1977
- 3) Fujino F: Contributions to study of hydro-nephrosis. 1. Statistical studies on hydro-nephrosis. (In Japanese). *J Nagoya City Univ Med Assoc* **8**: 225-231, 1958
- 4) Toyoda Y and Maruyama K: Method of suture for ureter and renal pelvis in lithotomy. (In Japanese). *Operation* **28**: 1287-1289, 1974
- 5) Colby FH: Cutaneous ureterostomy in active renal tuberculosis *J Urol* **48**: 357-367, 1942
- 6) Sousa A de: Microangiographic aspects of the ureter. *J Urol* **95**: 179-183, 1966

(Received on April 11, 1990)
(Accepted on July 20, 1990)

和文抄録

豊田法による無カテーテル尿管皮膚瘻術の成績

都立広尾病院（医長：丸山邦夫）

丸山 邦夫, 矢島 愛治, 鳥居 毅

内藤 善文, 豊田 泰

社会保険都南総合病院（部長 小川 肇）

小 川 肇

最近9年間に、43症例、67尿管に対し豊田法により無カテーテル尿管皮膚瘻術を行った。対象患者は男性30例、女性13例、平均年齢は61.4歳で、そのほとんどが膀胱、直腸、前立腺、子宮の悪性腫瘍であった。両側性の場合、原則として左右尿管を一カ所に出す二連銃式尿管皮膚吻合術（double barrel ureterostomy）を行った。

術前術後の腎盂像の推移を IVP で追及できた60尿管についてみると、単側性の場合20尿管中4尿管を除けばほぼ満足すべき結果を得ている。Double bar-

rel 法40尿管について、stoma 側では中等度以上の腎盂拡張が20尿管中3尿管であったが、stoma と反対側では腎機能に影響が出る事が多く、20尿管中3尿管に中等度の腎盂拡張が、また5尿管に高度の腎盂拡張または腎機能喪失があった。術後間もなく汎血管内凝固症候群で死亡した1例を除き、結果的には stoma 付近が強い炎症性肉芽に覆われた1例と尿管の狭窄を生じた2例を除いた42例中39例（92.8%）を tubeless の尿管皮膚瘻としてみた。

（泌尿紀要 37：243-248, 1991）