

Title	Renal cell carcinoma metastatic to the tongue: a case report
Author(s)	Ishikawa, Jiro; Morisue, Koichi; Imanishi, Osamu; Kamidono, Sadao
Citation	泌尿器科紀要 (1991), 37(3): 263-265
Issue Date	1991-03
URL	http://hdl.handle.net/2433/117136
Right	
Type	Departmental Bulletin Paper
Textversion	publisher

RENAL CELL CARCINOMA METASTATIC TO THE TONGUE: A CASE REPORT

Jiro Ishikawa, Koichi Morisue, Osamu Imanishi and Sadao Kamidono

From the Department of Urology, Kobe University School of Medicine

We report a case of renal cell carcinoma (RCC) metastatic to the tongue in a 58-year-old female. The patient had undergone radical nephrectomy for renal cell carcinoma 5 years previously, and experienced multiple metastatic disease in lung, bone, and contralateral kidney, before she noticed yellowish tumor on the left border of the tongue. Microscopic appearances of the biopsied lingual tumor were almost identical to those of the primary kidney tumor, thus the diagnosis of lingual metastasis from renal cell carcinoma was established. This case represents the tenth case of RCC metastatic to the tongue.

Key words: Renal cell carcinoma, Lingual metastasis

INTRODUCTION

Renal cell carcinoma (RCC) is an unpredictable tumor which occasionally metastasizes to uncommon sites such as thyroid gland, parotid gland, and gingiva¹⁻³⁾. The tongue has been reported as one such unusual metastatic site⁴⁻¹²⁾.

We report one additional case of a 58-year-old female and also briefly review the literature.

CASE REPORT

A 58-year-old Japanese female noticed a

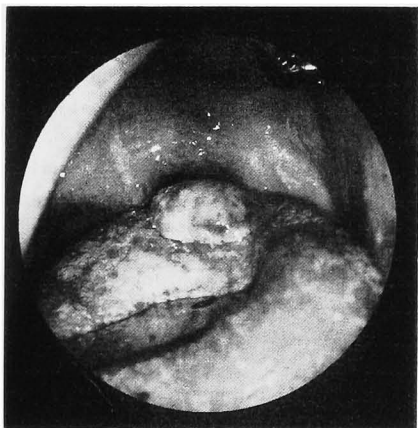
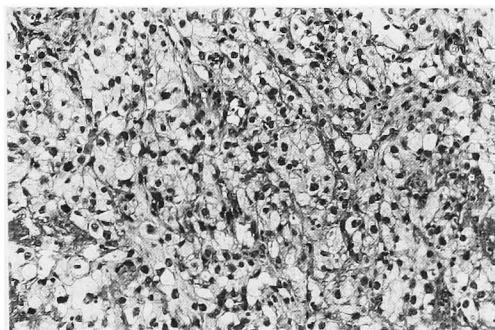
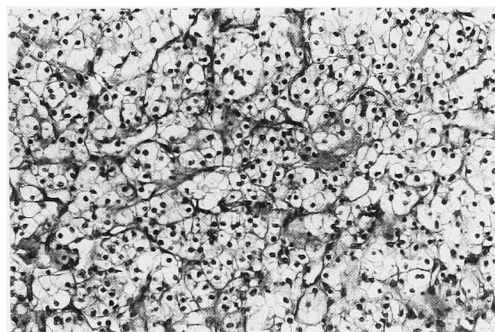


Fig. 1. A yellowish tumor located on the left border of the tongue.

growing yellowish tumor on the left border of the tongue in January 1989 (Fig. 1). She had undergone radical left nephrectomy for RCC 5 years previously. In spite



A



B

Fig. 2A. The lingual tumor consisted of clear tumor cells (H&E, $\times 66$).

2B. Primary renal cell carcinoma of the kidney consisted of clear tumor cells (H&E, $\times 66$).

Table 1. Renal cell carcinoma metastatic to the tongue

Reference	Age/Sex	Other Metastasis	Primary lesion identified
Inai et al.	42/M	lung, bone	lt. kidney
Satomi et al.	41/M	lung, lymph node contralateral kidney	lt. kidney
Kitao et al.	57/M	lung, bone	rt. kidney
Matsumoto and Ito	77/F	lung	lt. kidney
McNattin and Dean	58/F	lung, heart, skin	skin
Schag and Jordan	34/M	lung	lung
Fitzgerald et al.	63/M	brain, gingiva	brain
Kappor et al.	70/M	none	tongue
DelCarmen and Korbitz	77/M	none	lt. kidney
Present case	59/F	lung, bone	lt. kidney

of the postoperative α -interferon therapy, she had metastatic disease in the lung, bone, and contralateral kidney. Microscopic examination of the biopsied lingual tumor revealed that the tumor consisted of tumor cells with clear cytoplasm, essentially identical to those in the primary kidney tumor. Thus the diagnosis of metastatic lingual RCC was established.

The lingual tumor was resected by cryosurgery, metastatic disease progressed and she died of hepatic insufficiency due to multiple liver metastases in June, 1989. Autopsy was not granted for this case.

DISCUSSION

Metastatic tumor to the tongue is extremely rare. Zegarelli et al.¹³⁾ found 15 cases of lingual metastatic carcinoma or malignant melanoma among 6,881 autopsy cases, of which more than 99% were cases of malignant diseases in patients at Roswell Park Memorial Institute from 1955 to 1971. Thus, the incidence was about 0.2%, which was similar to that reported by others^{14,15)}.

Only 10 cases of RCC metastatic to the tongue have been reported including our case⁴⁻¹²⁾ (Table 1). These cases include 6 males and 4 females with the median age of 57.8 (ranging from 41 to 77). Eight cases had other metastatic diseases, which was lung metastasis in 7 cases. Seven of the 8 RCC cases with multiple metastases including the tongue died within one year after discovery of lingual metastasis. The remaining two RCC cases with solitary

lingual metastasis were alive, although the observation periods were not mentioned in the literature. We conclude that RCC patients with multiple metastases including the tongue have poor prognosis, but the lingual metastasis itself is not a prognostic indicator of RCC. The cellular atypism of the metastatic tumor was interesting in our case.

REFERENCES

- 1) Green LK, Ro JY, Mackay B, et al.: Renal cell carcinoma metastatic to the thyroid. *Cancer* **63**: 1810-1815, 1989
- 2) Melnick SJ, Amazon K and Dembrow V: Metastatic renal cell carcinoma presenting as a parotid tumor: a case of the literature. *Hum Pathol* **20**: 195-197, 1989
- 3) Jacobs H, Ruben MP and Lyon J: Renal-cell carcinoma metastatic to the mandible and gingiva. *Oral Surg* **22**: 649-653, 1966
- 4) McNattin RF and Dean AL: A case of renal adenocarcinoma with unusual manifestations. *Am J Cancer* **15**: 1570-1576, 1931
- 5) Scrag AF and Jordan FB: Unusual metastasis from a primary hypernephroma. *Can Med Assoc J* **53**: 168-169, 1945
- 6) Del Carmen BV and Korbitz BC: Oral metastasis from hypernephroma. *J Am Geriatr Soc* **18**: 743-746, 1970
- 7) Satomi Y, Matsuura K, Ogawa H, et al.: Three cases of hypernephroma metastasis in the otorhinopharyngolaryngial region (parotid gland, nasal cavity, tongue and gingiva). *Jpn J Clin Urol* **28**: 611-616, 1974 (in Japanese)
- 8) Fitzgerald RH, Mcinnes BK and Manry HC: Renal cell carcinoma involving oral soft tissues. *J Oral Maxillofac Surg* **40**: 604-606,

- 1982
- 9) Kitao K, Watanabe K, Miyamura K, et al.: Metastatic Grawitz tumor of the base of tongue: a case report. *Otolaryngology* **58**: 67-70, 1986 (in Japanese)
- 10) Matsumoto A and Ito S: Metastasis of renal cell carcinoma to the tongue: a case report. *Nishinippon J Urol* **49**: 1147-1149, 1987 (in Japanese)
- 11) Inai T, Kagawa S, Aga Y, et al.: A renal cell carcinoma with metastasis to the tongue. *Acta Urol Jpn* **33**: 1240-1243, 1987
- 12) Kapoor VK, Mukhopadhyay AK, Chattopadhyay TK, et al.: Renal cell carcinoma metastatic to the tongue. *J Indian Med Assoc* **85**: 119-120, 1987
- 13) Zegarelli DJ, Tsukada Y, Pickren J, et al.: Metastatic tumor to the tongue. *Oral Surg* **35**: 202-211, 1973
- 14) Weitzner S, Hentel W and Mex AN: Metastatic carcinoma in tongue: report of a case. *Oral Surg* **25**: 278-281, 1968
- 15) Abrams HL, Spiro R and Goldstein N: Metastasis in carcinoma: analysis of 1,000 autopsied cases. *Cancer* **3**: 74-85, 1950
- (Received on January 26, 1990)
(Accepted on November 5, 1990)

和文抄録

舌転移をきたした腎細胞癌の1例

神戸大学医学部泌尿器科学教室 (主任: 守殿貞夫教授)

石川 二郎, 森末 浩一, 今西 治, 守殿 貞夫

58歳女性にみられた腎細胞癌の舌転移例を報告する。患者は5年前に腎細胞癌で根治的左腎摘出術を施行された後、肺、骨、対側腎に多臓器転移をきたし、さらに、舌の左縁に増大する黄色調の腫瘤を認めた。

舌腫瘤の生検組織の顕微鏡所見は腎腫瘍とほぼ同一

で、腎細胞癌の舌転移の診断が下された。

本症例は、舌転移をきたした腎細胞癌の第10例目である。

(泌尿紀要 **37**: 263-265, 1991)