

Title	Giant renal angiomyolipoma with an uncommon growth pattern: a case report
Author(s)	Gohji, Kazuo; Gotoh, Akinobu; Kamidono, Sadao
Citation	泌尿器科紀要 (1990), 36(7): 837-840
Issue Date	1990-07
URL	<a href="http://hdl.handle.net/2433/116942">http://hdl.handle.net/2433/116942</a>
Right	
Type	Departmental Bulletin Paper
Textversion	publisher

# GIANT RENAL ANGIOMYOLIPOMA WITH AN UNCOMMON GROWTH PATTERN: A CASE REPORT

Kazuo Gohji, Akinobu Gotoh and Sadao Kamidono

*From the Department of Urology, Kobe University School of Medicine*

A case of a giant renal angiomyolipoma with uncommon growth pattern in a 66-year-old female is reported. The tumor originated from the upper pole of the left kidney and simultaneously grew posteriorly in a sheet-like fashion while a spheroid mass projected upwards. With magnetic resonance imaging (MRI), the relationship between the tumor and adjacent organs was clear. Tumorectomy employing cavitron ultrasonic surgical aspirator (CUSA) was performed, and proved to be a safe and simple procedure. There has been no recurrence of the growth 2 years post-operatively.

**Key words:** Angiomyolipoma, Kidney, MRI, Tumorectomy, CUSA

## INTRODUCTION

Renal angiomyolipoma is a comparatively rare and benign neoplasm<sup>1)</sup>. Radiographically, there are several characteristic findings, one of which is low density in computerized tomography (CT)<sup>2)</sup>. Recently, magnetic resonance imaging (MRI) has come into common use in the diagnosis of various tumors. This technique has several advantages compared to CT, such as its ability to take coronal, sagittal and transverse sections, and clearly reveal major vessels<sup>2-4)</sup>. Thus, the relationship of a tumor and its adjacent organs is well demonstrated. In the present report, we will describe a giant angiomyolipoma which originated from the renal parenchyma with an uncommon growth pattern, and discuss the usefulness of MRI in diagnosis of the disease and cavitron ultrasonic surgical aspirator (CUSA) in tumorectomy.

## CASE REPORT

A 66-year-old female visited our hospital. Routine chest X-ray revealed an abnormality of the left diaphragm. In spite of this finding, the patient manifested no symptoms such as cough or dyspnea (Fig. 1). Physical examination revealed a mass about the size of a grapefruit in

the left latus. Urine and other laboratory findings were within normal limits. In our case, tuberous sclerosis was not a complication, so that there was no evidence of sebaceous adenoma on her face, calcification of the brain nor glioma in the eye. Intravenous pyelograph revealed neither hydronephrosis, nor deformity of renal pelvis and calyces. CT revealed a large mass of uniform low density, the CT value of which was the same as that of adipose tissue (Fig. 2). MRI coronal and transverse sections revealed that the tumor originated in the parenchyma of the left kidney emerging at the upper pole of the kidney in two directions, forming a sheet-like growth which extended posteriorly from the kidney as well as a spheroid mass which pushed up the left side of the diaphragm (Fig. 3, 4, and 5). With MRI, the tumor showed high intensity in T<sub>1</sub> weighted image. Angiography showed a large mass with slight hypervascularity and microaneurysms. Tumorectomy was performed under the diagnosis of angiomyolipoma of the left kidney. The tumor was electrically resected along the inside of the capsula of the tumor (Fig. 5). Residual tumorous tissue was aspirated by CUSA, and large vessels were ligated. Macroscopically, the resected tumor was 1,380 g in weight, 21 cm × 14 cm × 4 cm in

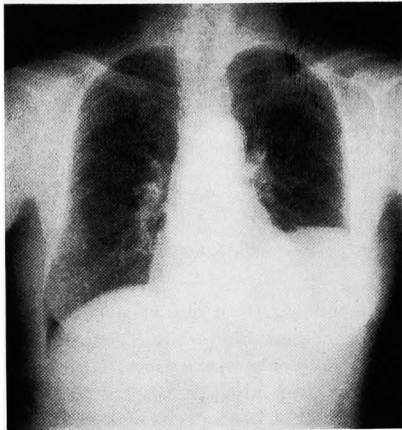


Fig. 1. Chest X-ray revealed the left portion of the diaphragm being pushed up by the spheroid tumor mass.

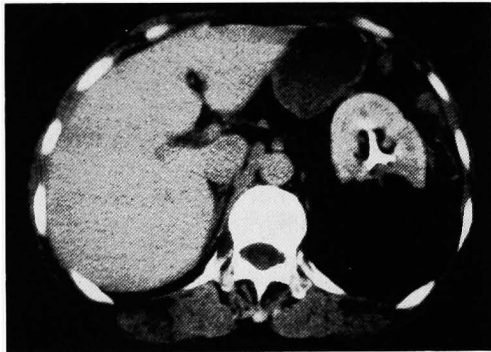


Fig. 2. CT scan revealed a uniformly low density mass emerging from the left kidney.

size, yellow in color with a soft elastic consistency (Fig. 6A). Histological examination revealed that the angiomyolipoma contained mature adipose tissue as well as vascular structures and smooth muscle (Fig. 6B). The course of recovery was excellent and the patient was discharged 14 days after the operation. She has been followed up as an out-clinic patient. At two years after the operation, there was no evidence of disease.

#### DISCUSSION

MRI has unique characteristics and advantages compared to CT<sup>3-5</sup>); 1) sagittal, coronal and transverse views are obtained, 2) vessels are clearly revealed without

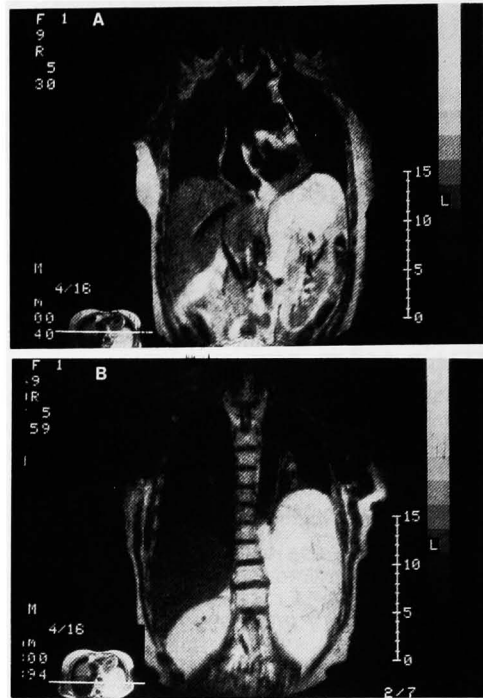

Fig. 3. In coronal view of MRI, a sheetlike growth emerging from the upper pole of the left kidney and projecting posteriorly is revealed in T<sub>1</sub> weighted imaging.

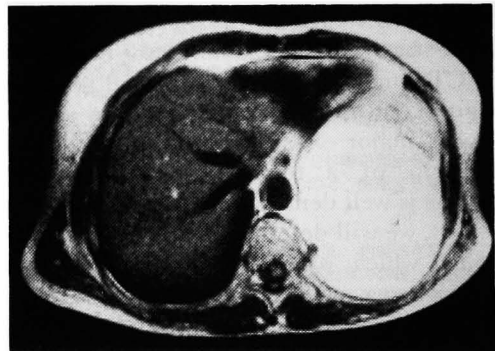


Fig. 4. MRI in transverse view: A high intensity mass emerging from the left kidney is revealed in T<sub>1</sub> weighted imaging.

contrast media, and 3) patients are not subjected to radiation of any kind. Angiomyolipoma generally consists of three components, mature adipose tissue, vascular structures and smooth muscle<sup>6</sup>. The CT and MRI findings vary according to the ratio of the three components<sup>6</sup>. In

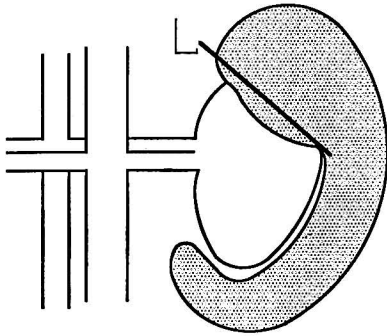


Fig. 5. Illustration of tumor growth pattern. The tumor originated in the parenchyma of the left kidney emerging at the upper pole of the kidney in two directions, forming a sheet-like growth which extended posteriorly from the kidney as well as a spheroid mass which pushed up the left side of the diaphragm. L; line of resection

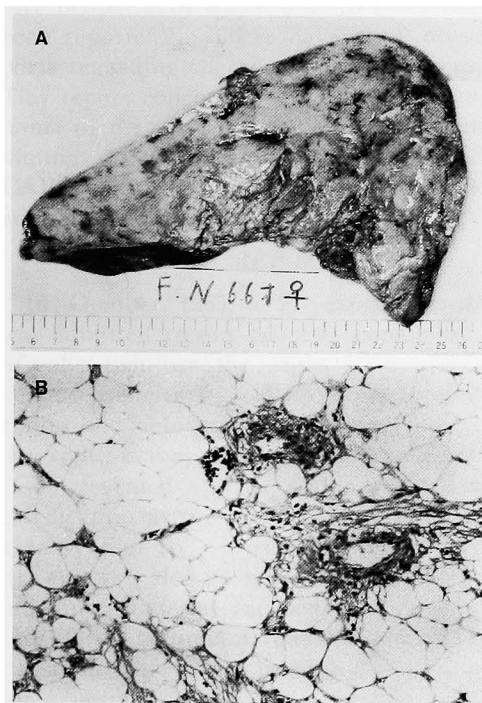


Fig. 6. A, Macroscopic appearance of the resected tumor. The cut surface is yellow and some hemorrhagic foci can be seen. B, Microscopic examination reveals the tumor consists of adipose tissue, vascular structures and smooth muscle. There were no malignant findings (H&E,  $\times 120$ ).

typical angiomyolipoma, the CT value is less than  $-70$  HU, which is the same as adipose tissue<sup>2)</sup>. On the other hand, this tumor shows a high intensity similar to that of adipose tissue in the retroperitoneal space in  $T_1$  weighted image of MRI<sup>5)</sup>.

In our case, CT showed a uniform low density mass, so it could not demonstrate the relationship of the tumor to the kidney. On the other hand, MRI, which showed a high intensity mass in  $T_1$  weighted imaging, indicated a clear relationship in coronal views.

Tumorectomy or partial nephrectomy is generally performed in large angiomyolipoma, because it is no malignancy<sup>7)</sup>. In our case, tumorectomy was performed employing CUSA, which helped to simplify the procedure and to keep the volume of bleeding low. Moreover, using CUSA, the renal parenchyma was left intact. Even after two years, there was no recurrence of disease.

In conclusion, we have found MRI useful in demonstrating the relationship of a tumor and the adjacent organs. Furthermore, employing CUSA proved a safe and simple method in the surgical treatment of angiomyolipoma.

#### REFERENCES

- 1) Hajdu SI and Foote FW Jr: Angiomyolipoma of the kidney: report of 27 cases and review of the literature. *J Urol* **102**: 396-401, 1969
- 2) Hansen GC, Hoffman RB, Sample WF and Becker R: Computed tomography diagnosis of renal angiomyolipoma. *Radiology* **128**: 789-791, 1978
- 3) Karstaedt N, McCullough DL, Wolfman NT and Dyer RB: Magnetic resonance imaging of the renal mass. *J Urol* **136**: 566-570, 1986
- 4) Hricak H, Demas BE, Williams RD, McNamara MT, Hedgcock MW, Amparo EG and Tanagho EA: Magnetic resonance imaging in the diagnosis and staging of renal and perirenal neoplasms. *Radiology* **154**: 709-715, 1985
- 5) Choyke PL, Kressel HY, Pollack HM, Arger PM, Axel L and Mamourian AC: Focal renal masses: magnetic resonance imaging. *Radiology* **152**: 471-477, 1984
- 6) Sherman JL, Hartman DS, Friedman AC,

Madewell JE, Davis CJ and Goldman SM:  
Angiomyolipoma: computed tomographic-  
pathologic correlation on 17 cases. AJR 137:  
1221-1226, 1981

7) Oesterling JE, Fishman EK, Goldman SM

and Marshall FF: The management of renal  
angiomyolipoma. J Urol 135: 1121-1124,  
1986

(Received on October 23, 1989)  
(Accepted on January 12, 1990)

## 和文抄録

### 特異な増殖形態を呈した巨大腎血管筋脂肪腫の1例

神戸大学医学部泌尿器科学教室 (主任: 守殿貞夫教授)

郷司 和男, 後藤 章暢, 守殿 貞夫

66歳女性に見られた特異な増殖形態を有する巨大腎血管筋脂肪腫の1例を報告する。腫瘍は左腎上極より発生し上方へ増殖し横隔膜を挙上すると共に腎の背側へシート状に増殖していた。MRI は本症の診断に有用で腫瘍と周囲臓器との関係を明瞭にすることができた。腎血管筋脂肪腫の診断のもとに CUSA を用いて

腫瘍摘出術を施行した。腫瘍は重量 1,380 g で弾性硬, 黄色調を呈し, 組織学的に血管筋脂肪腫であった。術後経過順調で術後2年を経たが明らかな再発を認めていない。

(泌尿紀要 36: 837-840, 1990)