

Title	Microsurgical transvaso-vasostomy
Author(s)	Fujioka, Hideki; Matsui, Takayuki; Doi, Yasuhiro; Takeyama, Masami; Koh, Eitetsu; Kondoh, Nobuyuki; Okuyama, Akihiko
Citation	泌尿器科紀要 (1990), 36(3): 367-369
Issue Date	1990-03
URL	<a href="http://hdl.handle.net/2433/116847">http://hdl.handle.net/2433/116847</a>
Right	
Type	Departmental Bulletin Paper
Textversion	publisher

## MICROSURGICAL TRANSVASO-VASOSTOMY

Hideki Fujioka\*, Takayuki Matsui\*\*, Yasuhiro Doi\*\*\*,  
Masami Takeyama\*\*\*\*, Eitetsu Koh and Nobuyuki Kondoh

*From the Department of Urology, Osaka Central Hospital*

Akihiko Okuyama

*From the Department of Urology, Osaka University Hospital*

We report a case of an infertile man treated successfully with microsurgical transvaso-vasostomy. The patient had a normal testicle with an obstructed vas deferens on one side and an atrophied testicle with a normal vas on the other side. We anastomosed the proximal vas from the functioning testicle to the opposite intact vas through the median scrotal raphe. As a result, the patient fathered a child 16 months after operation.

**Key words:** Transvaso-vasostomy, Microsurgery

### INTRODUCTION

For the treatment of male infertility caused by obstruction of the reproductive tract, surgical treatment is the principal successful modality. Various surgical techniques have been employed for anastomosis of the vas deferens, especially for the reversal of vasectomy. Although conventional macroscopic procedures have not yielded satisfactory results, microsurgical anastomosis has<sup>1-2)</sup>

We report a case of successful microsurgical transvaso-vasostomy, a cross-over anastomosis of one of the vasa deferentia to the other side through the median scrotal raphe. The infertile man who underwent this operation, had one normal testicle with an obstructed vas while the opposite testicle was atrophied but with a patent seminal duct.

### CASE REPORT

A 26-year-old man was referred to our hospital with 3 years of infertility and a previous history of mumps orchitis at the age of 15. Physical examination revealed a left atrophied testicle without any other

abnormalities in the genital organ. Analysis of the semen, 2.2 ml on average, showed azoospermia. Serum endocrine studies, including those of testosterone, luteinizing hormone and follicular stimulating hormone, were within normal limits. Vesiculography was performed, revealing extended obstruction of the right seminal duct at the inguinal level but patency on the opposite side (Fig. 1). As he had no anamnesis of epididymitis or inguinal trauma, the genesis of the right vasal obstruction was unknown. Testicular biopsy indicated spermatogenesis in the right testicle, but not in the left one, which was thought to have been affected by mumps orchitis.

To achieve continuity of the reproductive tract in this patient, we designed an operation to anastomose the proximal vas from the right functioning testicle to the patient distal vas on the left side across the scrotal septum. This procedure is referred to as transvaso-vasostomy. After we confirmed the presence of motile spermatozoa in the intravasal fluid, anastomosis was performed microsurgically with the two-layer anastomosis technique using 10-0 nylon as schematically shown in Figure 2. Sperm were detected in the patient's ejaculate one month later and 16 months postoperatively he fathered a

\*: Kinki Central Hospital

\*\* : Chifune Hospital

\*\*\* : Minami Osaka Hospital

\*\*\*\* : Sakai Municipal Hospital

healthy daughter.

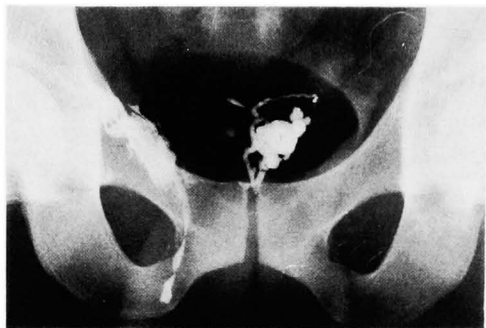

Fig. 1. Vesiculography shows extensive obstruction and extravasation of the contrast medium in the right vas deferens, but patency in the opposite one.

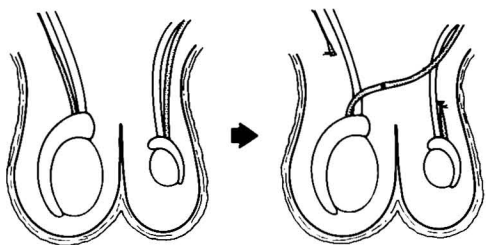


Fig. 2. Schematic presentation of "transvaso-vasostomy". The proximal vas from the right functioning testicle is anastomosed to the left intact vas of the atrophied testicle through the median scrotal raphe.

### DISCUSSION

The operative method we employed to achieve continuity of the reproductive tract across the scrotal septum was previously suggested by Dubin and Amelar<sup>3)</sup>. On a patient with unilateral testicular atrophy on the right side and an injured left vas incidental to a difficult low ureterolithotomy, resulting in sterility they performed a cross-over anastomosis of the vas deferens, the same procedure we employed in our transvaso-vasostomy. Recently, several cases of successful transvaso-vasostomy have been reported. Lizza and associates<sup>4)</sup> reported two pregnancies from eleven patients who had had this procedure and Hamidinia<sup>5)</sup> described 2 subsequent pregnancies in 5 patients.

Similarly, Silber described a cross-over

vasoepididymostomy, or anastomosis of the vas deferens to the opposite epididymis through the median scrotal raphe<sup>6)</sup>. With this surgical procedure success was achieved in a clinical case where the patient had congenital absence of the vas deferens but a normal testicle and epididymis on the left, and a normal vas on the right. Though there is a difference in the obstructive pattern of the seminal tract between Silber's case and the present case, the concept of our surgical procedure is the same as Silber's.

When infertile men are diagnosed as sterile because of unusual obstruction of the seminal tract as mentioned above, transvaso-vasostomy or cross-over vasoepididymostomy should be the treatment of choice. The reason is that the results of construction of an artificial spermatocele are not satisfactory as yet and it is therefore important to use the natural tract for reconstruction of the affected pathway of the sperm. Finally, it must be emphasized that microsurgical techniques used in the present case and others described in the literature<sup>1,2)</sup>, which are currently yielding a high success rate, promise good results for the patients.

### REFERENCES

- 1) Yarbro ES and Howards SS: Vasovasostomy. *Urol Clin North Am* 14: 515-526, 1987
- 2) McClure RD: Microsurgery of the male reconstructive system. *World J Urol* 4: 105-114, 1986
- 3) Dubin L and Amelar RD: Surgery for male infertility. In: *Male infertility*. Edited by Amelar RD, Dubin L and Walsh PC. Chapt. 11, pp. 215-236, W.B. Saunders Co., Philadelphia, 1977
- 4) Lizza EF, Marmar JL, Schmidt SS, Lanasa JA, Jr, Sharlip ID, Thomas AJ, Belkner AM and Nagler HM: Transseptal crossed vasovasostomy. *J Urol* 134: 1131-1132, 1985
- 5) Hamidinia A: Transvasovasostomy—An alternative operation for obstructive azoospermia. *J Urol* 140: 1545-1548, 1988
- 6) Silber SJ: Microsurgery of the male genitalia. In: *Microsurgery*. Edited by Silber SJ. Chapt. 9, pp. 307-375, The Williams & Wilkins Co., Baltimore, 1979

(Received on September 4, 1989)

(Accepted on October 17, 1989)

(迅速掲載)

## 和文抄録

## 顕微鏡下交叉性精管精管吻合術による妊娠成立の1例

健保連大阪中央病院泌尿器科（院長：戸田良郎）

藤岡 秀樹，松井 孝之，土井 康裕

竹山 政美，高 栄哲，近藤 宣幸

大阪大学医学部附属病院泌尿器科（主任：園田孝夫教授）

奥 山 明 彦

26歳男性，3年間の不妊にて来院。精液中に精子を認めず，血中テストステロン，LH，FSHは正常範囲。理学的所見では，15歳時のムンプス精巣炎によると思われる左精巣の萎縮を認めるほか異常なし。精管造影で，左側は正常であるが右側精管は鼠径部で完全閉塞，精巣生検では右側精巣の精子形成能はほぼ正常であったが左側は廃絶。この特異な精路通過障害の整備を目的として，右側正常精巣の閉塞前の中枢側精管

と対側正常精管末梢側とを，陰囊隔壁を通し，顕微鏡下に transvaso-vasostomy を施行した。術後1カ月目に精子の出現をみ，6カ月目に妊娠成立，満期安産にて正常女児を出産した。このような特異な精路通過障害の整備には，可能な限り生来の精路を用いる手術法がとられるべきで，その際には顕微鏡下での手術が成績向上のために必要と考えられる。

（泌尿紀要 36 : 367-369, 1990）