

Title	Metastatic renal tumor from the lung with regional lymph node involvement: a case report
Author(s)	Ishihara, Satoshi; Kobayashi, Satoru; Yamaha, Masayoshi; Takeuchi, Toshimi; Kuriyama, Manabu; Ban, Yoshihito; Kawada, Yukimichi; Takahashi, Yoshito; Horie, Masanobu; Isogai, Kazutoshi
Citation	泌尿器科紀要 (1990), 36(1): 51-54
Issue Date	1990-01
URL	http://hdl.handle.net/2433/116808
Right	
Type	Departmental Bulletin Paper
Textversion	publisher

METASTATIC RENAL TUMOR FROM THE LUNG WITH REGIONAL LYMPH NODE INVOLVEMENT: A CASE REPORT

Satoshi Ishihara, Satoru Kobayashi, Masayoshi Yamaha,
Toshimi Takeuchi, Manabu Kuriyama, Yoshihito Ban
and Yukimichi Kawada

From the Department of Urology, Gifu University School of Medicine

Yoshito Takahashi, Masanobu Horie and Kazutoshi Isogai

From the Department of Urology, Ogaki Municipal Hospital

We report a case of metastatic renal tumor from lung cancer. A 53-year-old man presented with gross hematuria 2 years after treatment of the primary lesion. Investigations suggested a metastatic tumor in the right kidney from the lung which was accompanied with regional lymph node metastasis. Surgical treatment was not performed because of his poor condition and the lymph node involvement. Therefore, the combination chemotherapy of 5-fluorouracil, vincristine and doxorubicin, OK-432 was applied. Although this conservative management was effective, he died of progression 6 months later and an autopsy confirmed the diagnosis of metastatic renal tumor.

Key words: Metastatic renal tumor, Lung cancer, Lymph node involvement

INTRODUCTION

Metastatic renal tumor is rarely found in the live patient. There have been about forty documented cases in the Japanese literature since 1968¹⁾. We describe a patient with this occurrence.

CASE REPORT

A 53-year-old man was admitted to Ogaki Municipal Hospital with gross hematuria 2 years after a right upper lobectomy for an adenocarcinoma of the lung. He denied other urologic symptoms or chest symptoms. Cystoscopic examination showed bloody efflux from the right ureteral orifice with normal bladder mucosa. A renal sonography revealed a highly echogenic mass with ill-demarcation in the lower half of the right kidney, which was confined in the regular capsular echo (Fig. 1). An excretory urography (IVP) showed incomplete opaciation of the right renal pelvicaliceal system. A subsequent retrograde ureterogram (RP) demonstrated a filling defect which showed a cobble-

stone-like appearance (Fig. 2). A CT scan demonstrated a low density, not contrast-enhanced area without clear rim in the lower half of the right kidney and hilar lymph node involvement (Fig. 3). A selective angiogram of the right renal artery (Fig. 4) and a digital subtraction angiogram (DSA) confirmed a hypovascular tumefaction with an encasement of the surrounding intrarenal arteries. A chest radiograph showed multiple nodular shadows in both lung fields. The hematology profile showed macrocytic anemia, but other serum chemical studies and serological studies were normal. Repeated urinary cytologic examinations were negative.

Diagnosis was recurrent lung cancer and metastatic renal tumor from the lung accompanied the regional lymph node metastasis. The latter was supported by the radiographic and sonographic findings and his past history. The negative urinary cytology argued against a primary uroepithelial carcinoma. Nephrectomy was not performed because of his poor performance status and the hilar lymph node

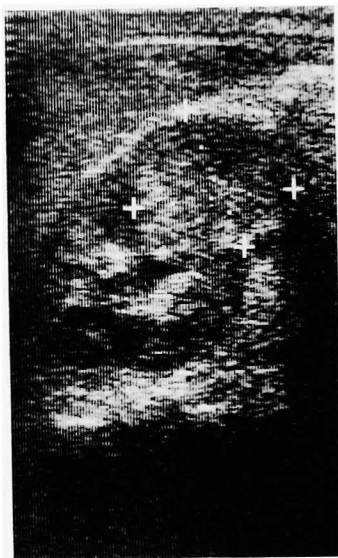

Fig. 1. Renal sonography: An ill-defined echogenic mass was found in the right kidney.

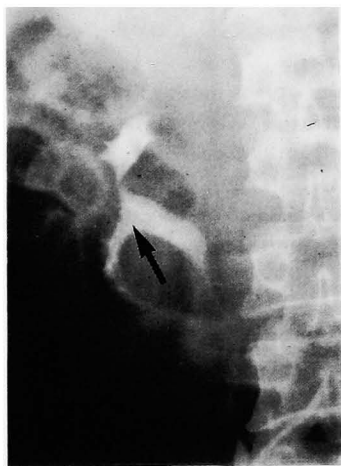

Fig. 2. Retrograde ureterogram showed multiple nodular appearance in the right pelvis (arrow).

involvement.

He was rehospitalized to Gifu University Hospital 3 months later with right flank pain and general malaise. Physical examination disclosed a severe anemic state and decreased respiratory sound in the left lung field. Bloody pleural fluid was obtained and its cytologic examination revealed class V adenocarcinoma. Systemic

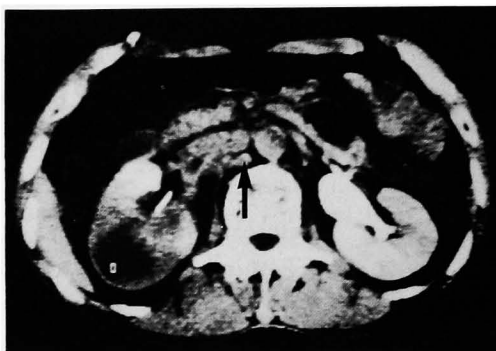

Fig. 3. Contrast-enhanced CT showed a low density mass in the right kidney and hilar lymph node involvement (arrow).

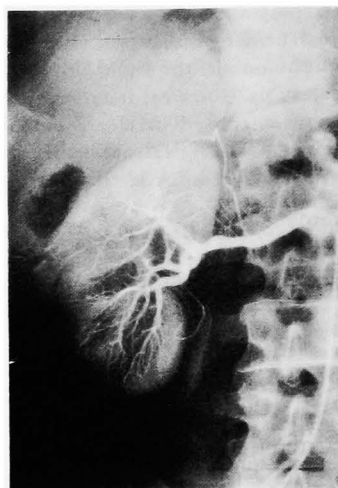


Fig. 4. Selective renal angiogram showed a hypovascular tumefaction with an encasement of the surrounding arteries.

chemotherapy of 5-fluorouracil, vincristine and doxorubicin and intrathoracic instillation of OK-432 and doxorubicin were begun. However, his condition deteriorated gradually and he died of dyspnea on the 91st hospital day. The autopsy confirmed recurrence of lung cancer with metastases to the right kidney (Fig. 5, 6) and retroperitoneal lymph nodes.

DISCUSSION

Metastatic neoplasms in the kidney are rarely identified in the live patient and are commonly discovered at autopsy. Klinger²⁾ reviewed 5,000 autopsies and found 118 instances of metastatic renal

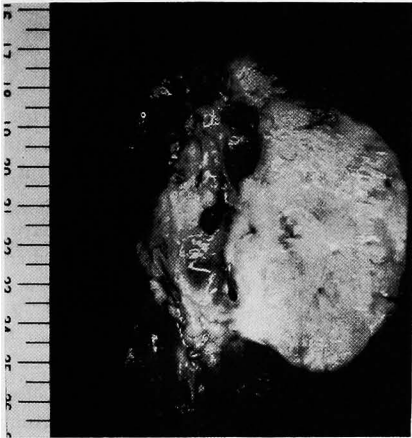

Fig. 5. Gross appearance of cut surface of the postmortem specimen revealed metastasis to the middle of the right kidney.

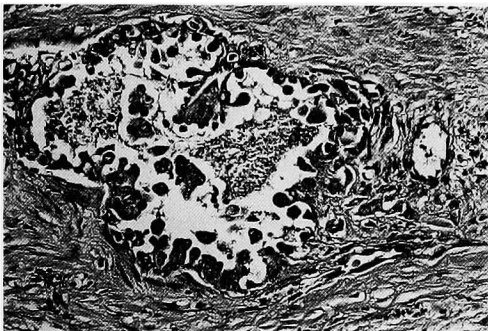


Fig. 6. Microscopic appearance of the right kidney revealed the nest of adenocarcinoma to be similar to the primary lesion.

tumor. In a review of 4,413 autopsies, Wagle et al³⁾ found 81 cases of metastatic renal tumor and these tumors were most commonly metastasized from the lung (20%), breast (12%), stomach (11%), and the opposite kidney (9%). Olsson et al⁴⁾ also reported 19.1% of patients dying of lung cancer had renal metastases. In a review of the Japanese literature since 1968, 43 cases with metastatic renal tumors are reported (including our case); 18 are metastasized from the lung, 6 from the esophagus and 5 from the thyroid gland.

These tumors seldom present clinical symptoms such as hematuria or flank pain, and the diagnoses are seldom made before death. Those that are asymptomatic may

be visualized on radiogram or sonogram by chance.

Pyelograms are less helpful to detect this tumefaction. They often give false normal results and, in addition, when pyelographical anomalies are detected, they are not specific. Computed tomograms and sonograms can characterize the tumefaction. Metastatic tumors usually demonstrate low density and heterogeneous appearances. However, to distinguish them from primary renal tumors, angiography is necessary. On the angiogram these tumors are usually round and hypovascular or avascular, and sometimes multiple, whereas most renal cell carcinomas are hypervascular and single. However, any hypervascular tumor that metastasize to the kidney will give rise to hypervascular metastases: thyroid carcinoma is typical, which is indistinguishable from renal cell carcinoma⁵⁾. In our review, 19 cases presented hypo/avascular tumefaction, and 4 cases did hypervascularly, the latter includes 2 cases of metastases from the thyroid gland. Also "encasement" of the renal arteries is helpful to distinguish from renal cell carcinoma because the encasement is usually seen in tumors that contain much fibrous stroma such as uroepithelial carcinomas or metastatic tumors, and is rare in renal cell carcinomas that has minimal fibrotic content⁵⁾. In our case, the renal angiography performed for the second time revealed progressed encasement, obliterated peripheral branches and more hypovascular tumefaction. These findings are supported by the autopsy which showed the infiltrative tumor with a strong stromal reaction.

In our case, a metastasis to the regional lymph nodes is accompanied, which is thought to be a tertiary lymphatic metastasis from the metastatic renal tumor, as is the case with a secondary lymphatic metastasis from a primary renal tumor. To our knowledge, there are only two documented cases^{6,7)} of the regional lymph node metastasis of the metastatic renal tumor identified with some diagnostic images in a living patient in Japan.

The prognosis of patients with metastatic

renal tumor is unfavorable and depends on the efficacy of treatment of the primary lesion and the resectability of the metastatic tumor. In our review, most cases are treated by nephrectomy, but the resectability is sometimes not satisfactory. Nephrectomy may only be meaningful for tumor mass reduction or symptomatic tumor. We believe that nephrectomy is a satisfactory treatment only if metastatic lesion is located within a kidney and if mass reduction is thought to bring about a significant prolongation or a well-being of life. In our case, multiple recurrence of the lung and his poor condition failed to make nephrectomy feasible. For unresectable tumor, noninvasive techniques such as embolization⁸⁾ of the metastatic tumor are available in order to reduce tumor bulk and some symptoms.

REFERENCES

- 1) Takayasu H, Kumamoto Y, Terawaki Y and Ueno A: A case of bilateral metastatic renal tumor originating from a thyroid carcinoma. *J Urol* **100**: 717-719, 1968
- 2) Klinger ME: Secondary tumors of the genitourinary tract. *J Urol* **65**: 144-153,

1951

- 3) Wagle DG, Moore RM and Murphy GP: Secondary carcinomas of the kidney. *J Urol* **114**: 30-32, 1975
- 4) Olsson CA, Moyer JD and Laferte RO: Pulmonary cancer metastatic to the kidney—a common renal neoplasm. *J Urol* **105**: 492-496, 1971
- 5) Frieland GW, Filly R, Goris ML, Gross D, Kempson RL, Korobkin M, Thurber BD and Walter J: Tumefaction. In: *Uroradiology—an integrated approach*. vol. 2, pp. 782-814, Churchill Livingstone, New York, 1983
- 6) Maeda O, Kameoka H, Miyoshi S, Iwao N and Mizutani S: Metastatic renal tumors: clinical report on three cases and review of 136 cases including 38 cases from the Japanese literature. *Acta Urol Jpn* **33**: 572-578, 1987
- 7) Kitami K, Masuda M, Chiba K and Kumagai H: Metastatic renal tumor originating from esophageal carcinoma: a case report. *Acta Urol Jpn* **33**: 1221-1225, 1987
- 8) Nieh PT, Waltman AC and Althausen AF: Therapeutic embolization of symptomatic secondary renal tumors. *J Urol* **117**: 378-380, 1977

(Received on April 8, 1989)
(Accepted on August 25, 1989)

和文抄録

所属リンパ節転移を伴った肺癌原発の転移性腎腫瘍の1例

岐阜大学医学部泌尿器科学教室 (主任: 河田幸道教授)

石原 哲, 小林 覚, 山羽 正義, 竹内 敏視

栗山 学, 坂 義人, 河田 幸道

大垣市民病院泌尿器科 (部長: 磯貝和俊)

高橋 義人, 堀江 正宣, 磯貝 和俊

腎転移をきたした肺癌の1例を経験したので報告する。症例は53歳男性で肺癌に対する右上肺葉切除から2年経過後、血尿を主訴として来院し、右腎にhypovascularな腫瘍と腎門部リンパ節の腫大を認め、肺癌の腎転移および所属リンパ節転移と診断し

た。全身状態の悪化とリンパ節浸潤のため腎摘は行えず、化学療法を行ったが、6カ月後、肺病変のために死亡した。剖検にて上記診断を確認した。

(泌尿紀要 **36**: 51-54, 1990)