

Title	Osteoma of the testis with its histogenetic consideration
Author(s)	SASAKI, Koichi; KINOSHITA, Yuzo; HARADA, Masaoki; FUKUNAGA, Noboru
Citation	泌尿器科紀要 (1989), 35(11): 1965-1968
Issue Date	1989-11
URL	<a href="http://hdl.handle.net/2433/116733">http://hdl.handle.net/2433/116733</a>
Right	
Type	Departmental Bulletin Paper
Textversion	publisher

# OSTEOMA OF THE TESTIS WITH ITS HISTOGENETIC CONSIDERATION

Koichi SASAKI and Yuzo KINOSHITA

*From the Department of Urology, Yokohama Seamen's Insurance Hospital*

Masaoki HARADA

*From the Laboratory of Pathology, Clinical Research Institute, Kanagawa Cancer Center*

Noboru FUKUNAGA

*From the Laboratory of Pathology, Yokohama Seamen's Insurance Hospital*

Although a few cases of osteoma in renal pelvis and urinary bladder have been reported, no cases of osteoma in the testis have been presented. A case of so-called osteoma of the testis incidentally found in a 30-year-old man was presented with discussion for its histogenetic considerations.

**Key words:** Osteoma, Testis, Histogenetic consideration

## INTRODUCTION

Benign tumor growth consisting of bone or cartilage, generally referred to as osteoma, chondroma, or osteochondroma is extremely rare in the urogenital tissue. Although a few cases of osteoma in the renal pelvis and urinary bladder have been reported<sup>1-3)</sup>, osteoma of the testis has not been reported to our knowledge. This is a case report of so-called osteoma of the testis with discussion of its histogenetic considerations.

## CASE REPORT

A thirty-year-old male patient was admitted to the urology service on December 13, 1984. He had subjective sensation of residual urine. Subsequently, tumescence, pain and pyrexia occurred in the left scrotal content on December 8, 1984. The patient visited a physician on December 10 and received medication, but tumescence and pain occurred also in the right scrotal content. For this reason, the patient was referred to our clinic. There was no history on scrotal content trauma and parotitis. Rubor was observed in the scrotal regions. The left scrotal content was palpated as a lump in a size of small hen's egg, and the tenderness was remar-

kable. On the right side, the epididymis was tumescent, and the tenderness was remarkable. Tenderness was observed also in the left prostatic lobe. Otherwise, moderate swelling of parotid glands were noted, and there was tenderness in them.

Urinalysis showed a trace of protein and 3+ blood, 20 to 25 red blood cells and 3 to 4 white blood cells per high power field, and 2 to 3 granular casts and 4 to 5 hyaline casts per all fields. Urine culture was negative for common bacteria. The white blood cell count was 8,100/mm<sup>3</sup>, with 62 percent granulocytes, 21 percent bands, 16 percent lymphocytes and 1 percent monocytes. Erythrocyte sedimentation rate was elevated between 68 and 97 mm, per hour. C-reactive protein was 6+.

This inflammation was considered to occur in connection with parotitis. These inflammatory signs were relieved gradually subsequent to administration of antibiotics and cold wet pack. However, the little finger-tip sized induration which was not noticed at admission was palpated in the right testis adjacent to the epididymal body, when sufficient palpation had become possible as a result of alleviation of the tumescence and pain in the bilateral scrotal content. The roentgenogram re-




Fig. 1. The roentgenogram of the right testicular body revealed calcification corresponding to the little finger-tip sized induration.

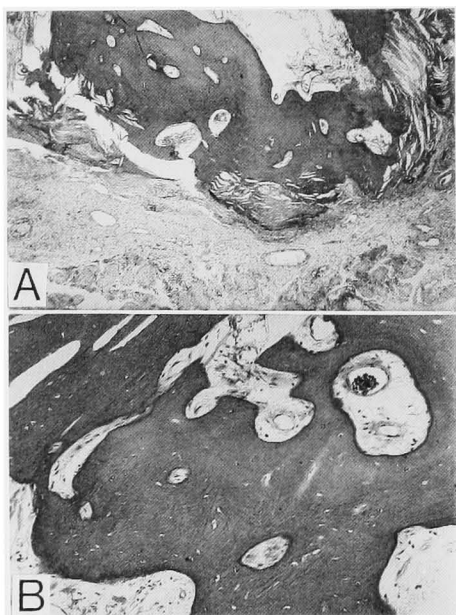


Fig. 2. A: Low power view of the resected tissue showing well circumscribed nodular growth mainly consisting of bony tissue (H.E.  $\times 25$ ).  
B: High power view of an area of compact bone showing well developed osseous matrix and haversian canals (H.E.  $\times 100$ ).

vealed calcification on this indurated region (Fig. 1).

The exploratory incision was made on the right scrotum. A stony hard spheroidal nodule was observed in the testis just beneath the tunica albuginea. This nodule was resected together with surrounding testicular tissue.

Histologically, the resected tissue revealed

a well circumscribed nodular lesion consisting of compact bone and fibrous connective tissues. Haversian canals were well developed in these bone trabeculae. However, no distinctive osteoblastic cell rim of the bone could be seen. The peripheral part of the nodule revealed lamellated fibrous tissue layer with irregular calcium deposition, and the incompletely mineralized layer merged into the compact bone tissue. In addition these included numerous cholesterol-like crystalloid clefts in these fibro-osseous transitional zone. Few multinucleated giant cells resembling osteoclasts were observed in loose edematous intertrabecular fibrous tissue. No chondrocartilaginous tissue could be found. Tiny aggregates of faintly basophilic amorphous spheroidal bodies resembling vacuolated shadowy degenerative epidermal cells were scarcely present at the marginal area of the nodule. However, these could not be identified as true epidermal cells. There was no definite teratoid tissue component. The surrounding testicular tissue showed hyalinized or Sertoli's cell only atrophic seminiferous tubules and inflammatory cell infiltration in the edematous interstitium, mainly consisting of lympho-plasmacytic cells (Fig. 2).

From these findings, the nodular lesion was diagnosed as so-called "osteoma" incidentally associated with non-specific subchronic orchitis.

#### DISCUSSION

There is much controversy about the term and nature of osteoma whether it is true neoplasia, hamartoma or simple exaggerated over-growth of osseous tissue. Ashley<sup>4)</sup> mentioned that the term osteoma in skeletal tissue is occasionally applied erroneously to osseous overgrowths resulting from trauma or infection, to markedly ossified osteoplastic lesions and to completely ossified osteochondroma. While, the term osteoma cutis is applied to cases of primary cutaneous ossification<sup>5)</sup>. Osteoma cutis is developed as a metaplastic change of dermal collagen tissue rather than the true neoplastic

process<sup>6)</sup>.

We consider the following three possibilities in the histogenesis of the lesion presented in this report.

1) The lesion may be leading in consequence of ossification of inflammatory granuloma in a course of orchitis.

2) The tumor may be formed as a true neoplastic process as well as a teratoma differentiated into exclusively bone tissue.

3) The tumor may be primary osteoma developed as metaplastic or hamartomatous processes.

The surrounding testicular tissue revealed mild nonspecific subchronic orchitis. The nodular lesion, however, was well circumscribed and apparently separated from the surrounding testicular parenchymal tissue. There was no evidence of chronic abscess nor granuloma nor foreign body reaction. Inflammatory reaction in surrounding testicular tissue might be secondary or incidentally associated with the tumor growth. Therefore, the first assumption can not be proved.

Dounis<sup>7)</sup> reported a case of primary chondroma of testis. He noted that was the first case of testicular teratoma consisting exclusively of normal cartilaginous tissue. Benign mesenchymal tumors such as hemangioma, fibroma, and lipoma are rarely encountered in the testis<sup>8)</sup>. Such tumors also raise the possibility of one-sided development from some teratomatous tissue elements. Thus, this case could also be a case of teratoma with one-sided growth to osseous tissue. Epidermal cyst which is considered as another example of one-sided differentiating teratoid tumor can be rarely seen in the testis<sup>9)</sup>. In cutaneous epitheliomatous lesions such as pilomatrixoma, metaplastic ossification to the pre-existing epidermal tissue is occasionally found<sup>5)</sup>. These facts suggest that this tumor developed as secondary metaplastic ossification of pre-existing epitheliomatous lesion including teratoid origin.

Osteogenic potentiality of urothelium such as urinary bladder, ureter and renal pelvis has been suggested experimentally by Huggins<sup>9)</sup>. From this view, the pre-

viously reported osteoma of the renal pelvis and urinary bladder might have developed by metaplastic or hamartomatous processes of urothelium or mesenchymal tissue. While osseous tissue of the presented tumor was mature, well developed thick bone tissue, the peripheral area of this tumor suggested metaplastic ossification from the fibrous tissue or secondary osseous change resulted from mineralization of collagen tissues. Numerous cholesterol-like crystals appearing in these fibroosseous junctional areas were also suggestive of metaplastic processes.

Although the exact histogenesis of the presented case can not be clarified and the histogenetic possibility of teratoma with one-sided differentiation to the osseous tissue can not be completely denied, histological features of this tumor strikingly resembled that of so-called osteoma as well as osteoma cutis. This may not be true neoplastic growth and may be a rather hamartomatous tumor. The term hamartoma generally designates an excessive focal overgrowth of mature normal cells and tissues in an organ, composed of identical cellular elements. Although bone tissue is not a normal constituent of the testis, testicular mesenchymal tissue also has a potential to form osseous tissue leading by metaplastic process as well as mesenchymal tissue in other site tissue and organ. Thus it is conceivable that the lesion presented in this report could be developed from such process.

#### REFERENCES

- 1) Plemister DB: Ossification in kidney stones attached to the renal pelvis. *Ann Surg* **78**: 239-249, 1923
- 2) Collings CW and Welebir F: Osteoma of the bladder. *J Urol* **46**: 494-498, 1941
- 3) Ookita K and Oomori H: Osteoma of the urinary bladder with calculus: report of a case. *Acta Urol Jpn* **7**: 1030-1035, 1961
- 4) Ashley DJB: Evans' histological appearances of tumours. 3rd ed., pp. 114-115, Churchill Livingstone Co., Edinburgh, 1978
- 5) Lever WF and Schaumburg-Lever G: Histopathology of the skin. 6th ed., pp. 660-663, J.B. Lippincott Co., Philadelphia, 1983
- 6) Allen AC: Skin. In: Anderson's Pathology.

- Edited by Kissane JM. 8th ed., vol. 2, pp. 1570-1641, The C.V. Mosby Co., St. Louis, 1985
- 7) Dounis A: Primary chondroma of testis. Br J Urol 56: 334-335, 1984
- 8) Mostofi FK and Price EB Jr: Tumors of the male genital system. In: Atlas of Tumor Pathology. Edited by Mostofi FK and Price EB Jr. 2nd ser. Fascicle 8, pp. 59-67, AFIP, Washington D.C., 1973
- 9) Huggins CB: The formation of bone under the influence of epithelium of the urinary tract. Arch Surg 22: 377-408, 1931 (Accepted for publication January 10, 1989)

## 和文抄録

## 睪丸骨腫の1例

横浜船員保険病院泌尿器科 (部長: 佐々木紘一)

佐々木 紘 一, 木 下 裕 三

神奈川県立がんセンター臨床研究所病理 (主任: 原田昌興)

原 田 昌 興

横浜船員保険病院病理 (顧問: 福永 昇)

福 永 昇

泌尿器系の骨腫については、少数例の腎盂と膀胱の骨腫が報告されている。しかし、睪丸骨腫の症例は調べた範囲ではまだ報告されていない。われわれは30

歳の男性の睪丸骨腫を経験したので、組織形成に関する考察を加え報告した。

(泌尿紀要 35: 1965-1968, 1989)