

Title	Lobulated polypoid tumor of the ureter showing histologically high grade malignancy: report of a case
Author(s)	Takeuchi, Hideo; Konami, Teruo; Takayama, Hidenori; Tomoyoshi, Tadao; Yoshitomi, Joji
Citation	泌尿器科紀要 (1989), 35(8): 1401-1404
Issue Date	1989-08
URL	<a href="http://hdl.handle.net/2433/116629">http://hdl.handle.net/2433/116629</a>
Right	
Type	Departmental Bulletin Paper
Textversion	publisher

# LOBULATED POLYPOID TUMOR OF THE URETER SHOWING HISTOLOGICALLY HIGH GRADE MALIGNANCY: REPORT OF A CASE

Hideo TAKEUCHI, Teruo KONAMI, Hidenori TAKAYAMA  
and Tadao TOMOYOSHI

*From the Department of Urology, Shiga University of Medical Science*

Joji YOSHITOMI

*From the Department of Surgery, Obama Hospital*

A case of a lobulated polypoid tumor of the ureter showing histologically high grade malignancy is reported. Such a tumor is rare in the bladder, and to date none have been documented in the ureter. This tumor is probably the most malignant urothelial tumor of the inverted type in the urinary tract, including inverted papilloma.

**Key words :** Ureter, Cancer, Transitional cell carcinoma, Polypoid tumor, Inverted type

## INTRODUCTION

Inverted papillomas are rare tumors of the urinary tract characterized by a polyp like configuration and an endophytic growth pattern, and are generally regarded as benign tumors<sup>1-6</sup>). Papillary carcinomas of the inverted type have also been found in the bladder<sup>7,8</sup>). However, to date none have been documented in the ureter. We report here a case of lobulated polypoid tumor of the ureter showing high grade malignancy.

## CASE REPORT

A 59-year-old man was hospitalized with sudden onset of severe epigastralgia, nausea and vomiting. The presumptive diagnosis was acute pancreatitis because the serum amylase level was high, and he was treated with aprotinin. Although he had had no episode of gross hematuria, urinalysis showed microscopic hematuria.

An excretory pyelography (IVP) showed mild stasis in the ureter and retrograde pyelography showed an irregular filling defect in the lower portion of the ureter on the right side (Fig. 1). Ureteral tumor on the right side was suspected and nephroureterectomy was done.

The surgical specimen showed a pedun-

culated polypoid tumor with a smooth surface, measuring  $2.8 \times 0.9 \times 0.6$  cm located in the lower third of the right ureter (fig. 2). The tumor was pale tan resembling normal ureteral mucosa and part of it was nodular and firm.

Microscopically, the tumor was composed of nodular lesions and some papillary lesions, and had a pedicle with partially cancerous changes. Moreover, cancerous change was noted in the area adjacent to the pedicle. The tumor showed no invasion of the muscle layer of the ureter (Fig. 3). Low power magnification showed that most of the surface of the tumor was covered with smooth connective tissue and part of it with non-cancerous epithelial cells (Fig. 4A, B). The tumor cells proliferating irregularly showed a papillary configuration. No muscle invasion, vascular invasion or lymphatic involvement was seen. At a higher magnification, these tumor cells demonstrated striking variability in nuclear size and shape, and mitotic activity was present (Fig. 5).

On the basis of these findings, the tumor was considered to be transitional cell carcinoma grade 3 of the superficial-nodular inverted type described by Yamada et al<sup>7</sup>).

The patient received adjuvant chemo-

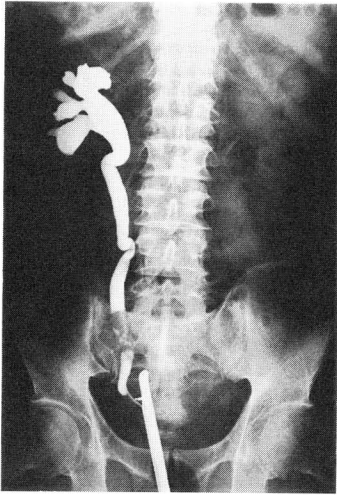

Fig. 1. Retrograde pyelogram showing an irregular filling defect in right lower ureter.

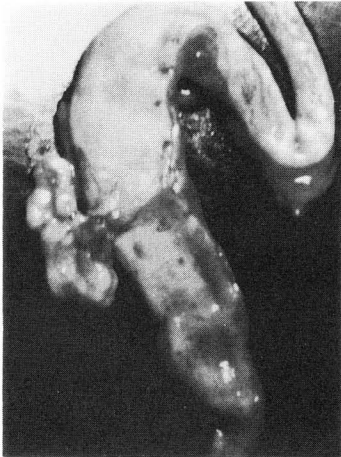


Fig. 2. Pedunculated polypoid tumor in the lower ureter. Note smooth surface.

therapy, including cis-DDP, after operation and was followed up. However, he died of massive bleeding due to a peptic ulcer three months later. Autopsy was not done.

#### DISCUSSION

Since inverted papillomas of the bladder were described in 1963 by Potts and Hirst<sup>1)</sup>, more than 100 cases have been reported<sup>6,8)</sup>. Although most of the tumors have been in the bladder, ureteral and renal pelvic tumors also have been documented<sup>9-11)</sup>. It has been repeatedly stressed




Fig. 3. Low power view of the polypoid tumor. HE reduced from  $\times 2$ . The tumor is composed of nodular and partially papillary lesions. In the pedicle and adjacent portion cancerous changes are also noted.

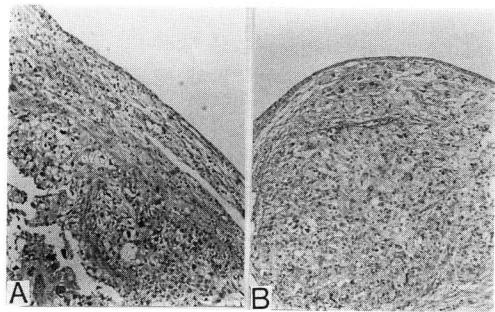


Fig. 4. A, Most of the surface of the tumor is covered with smooth connective tissue. B, The tumor is covered partially with non-cancerous epithelial cells. HE reduced from  $\times 50$ .

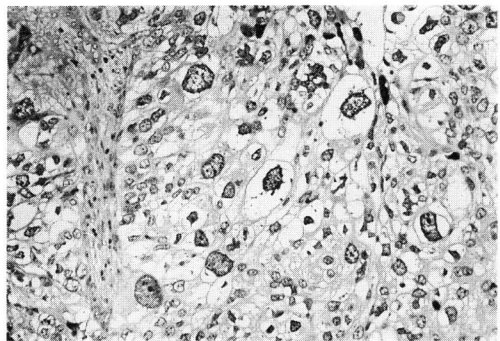


Fig. 5. Tumor cells demonstrating striking variability of nuclear size and shape. HE reduced from  $\times 200$ .

that this benign lesion must be differentiated from malignant or non-papillary tumors. However, the possibility of malignant transformation of inverted papillomas has been stressed<sup>11-13)</sup>.

On the other hand, inverted papillary carcinomas of the bladder have been reported<sup>5,7</sup>. We also have seen several cases of tumor of the bladder of the inverted type, but such tumors in the ureter have not been reported.

Yamada et al. divided tumors of the bladder of the inverted type into three subtypes: inverted papilloma, well differentiated inverted proliferating tumor and superficial nodular proliferating cancer<sup>7</sup>. According to their studies, superficial nodular proliferating cancer of the bladder was most malignant and showed rapid progression, most patients dying within 1~2 years. Our case was thought to be a superficial nodular proliferating cancer of the ureter. There may be various types of inverted tumor of the urinary tract between inverted papilloma and superficial nodular proliferating cancer, as there are various types of papilloma, papillary cancer (transitional cell carcinoma grade 1~3), and of non-papillary cancer among tumors showing an exophytic growth pattern. Our case may be described pathologically as papillary cancer, inverted type, transitional cell carcinoma grade 3.

The features of inverted type tumor are thought to be as follows: 1) pedunculated tumor showing polyp-like configuration, 2) normal or non-cancerous epithelial layers on the surface and pedicle of the tumor with little or no muscle invasion. Therefore, segmental ureterectomy may be considered in the treatment of tumor of the inverted type if the tumor is solitary. However, adjuvant chemotherapy is essential for superficial nodular proliferating cancer because vascular invasion is often noted.

#### REFERENCES

1) Potts IF and Hirst E: Inverted papilloma

- of the bladder. *J Urol* **90**: 175-179, 1963
- 2) Assor D and Taylor JN: Inverted papilloma of the bladder. *J Urol* **104**: 715-717, 1970
- 3) DeMeester LJ, Farrow GM and Utz DC: Inverted papilloma of the urinary bladder. *Cancer* **36**: 505-513, 1975
- 4) Henderson DW, Allen PW and Bourne AJ: Inverted urinary papilloma, report of five cases and review of the literature. *Virchows Arch (Path Anat)* **366**: 177-186, 1975
- 5) Cameron KM and Lupton CH: Inverted papilloma of the lower urinary tract. *Br J Urol* **48**: 567-577, 1976
- 6) Caro DJ and Tessler A: Inverted papilloma of the bladder, a distinct urological lesion. *Cancer* **42**: 708-713, 1978
- 7) Yamada T, Yokogawa M, Inada T, Mitani G and Oowada F: Clinicopathologic studies on the urinary bladder cancer; a new classification of the cancer with special references to the histopathologic architecture and their developmental tempo. *Jap J Cancer Clin* **21**: 184-193, 1975
- 8) Kunze E, Schauer A and Schmitt M: Histology and histogenesis of two different types of inverted urothelial papillomas. *Cancer* **51**: 348-358, 1983
- 9) Geisler CH, Mori K and Leiter E: Lobulated inverted papilloma of the ureter. *J Urol* **123**: 270-271, 1980
- 10) Fromowitz FB, Steinbook ML, Lautin EM, Friedman AC, Kahan N, Bennet MJ and Koss LG: Inverted papilloma of the ureter. *J Urol* **126**: 113-116, 1981
- 11) Uyama T and Moriwaki S: Inverted papilloma with malignant change of renal pelvis. *Urology* **17**: 200-201, 1981
- 12) Lazarevic B and Garret R: Inverted papilloma and papillary transitional cell carcinoma of urinary bladder, report of four cases of inverted papilloma, one showing papillary malignant transformation and review of the literature. *Cancer* **42**: 1904-1011, 1978
- 13) Whitesel JA: Inverted papilloma of the urinary tract: malignant potential. *J Urol* **127**: 539-540, 1982

(Accepted for publication October 19, 1988)

## 悪性度の高い組織像を示したポリープ様尿管腫瘍の1例

滋賀医科大学泌尿器科学教室（主任：友吉唯夫教授）

竹内 秀雄，神波 照夫，高山 秀則，友吉 唯夫

公立小浜病院外科（主任：吉富錠二）

吉 富 錠 二

悪性度の高い組織像を示したポリープ様の尿管腫瘍症例を報告した。この腫瘍は逆行型増殖を示したもので、膀胱では稀にみられるが、尿管腫瘍での報告はみられない。本症例は inverted papilloma を含めた逆

行性増殖を示す尿路上皮腫瘍の中で最も悪性度の高いものと思われる。

（泌尿紀要 35：1401-1404, 1989）