

Title	Prolapsed benign polyp of ureter associated with giant ureteral calculus
Author(s)	Terai, Akito; Terachi, Toshiro; Yoshida, Shuzo
Citation	泌尿器科紀要 (1989), 35(5): 871-873
Issue Date	1989-05
URL	<a href="http://hdl.handle.net/2433/116525">http://hdl.handle.net/2433/116525</a>
Right	
Type	Departmental Bulletin Paper
Textversion	publisher

# PROLAPSED BENIGN POLYP OF URETER ASSOCIATED WITH GIANT URETERAL CALCULUS

Akito TERAI, Toshiro TERACHI and Shuzo YOSHIDA

*From the Department of Urology, Kurashiki Central Hospital*

We report a case of a benign fibroepithelial polyp of the lowermost ureter, which prolapsed into the bladder and was associated with a huge, impacted ureteral stone. The polyp was considered to have resulted from chronic irritation of the ureteral mucosa caused by the stone. Review of the literature showed that six out of 74 reported cases had concomitant stones but the polyp was apparently caused by the calculi in only one case.

**Key words:** Ureteral polyp, Prolapse, Giant ureteral stone

## INTRODUCTION

Benign fibrous polyps of the ureter are rare and only 74 cases have been reported in the literature<sup>1)</sup>. The majority of them had unknown causes. Herein, we report a case of a fibroepithelial polyp of the ureter which prolapsed into the bladder and was associated with a huge impacted ureteral stone.

## CASE REPORT

A 37-year-old male was hospitalized because of right lower abdominal pain. He had had transient attacks of pain in the same region several times a year for the past twenty years. An intravenous urogram showed a giant ureteral stone in the right lowermost ureter, multiple small renal stones in the right lower calyx associated with a marked hydronephrosis and a 2 cm filling defect in the bladder (Fig. 1). On cystoscopy, an irregularly polypoid tumor with a smooth surface was seen in the position corresponding to the right ureteral orifice, which itself was unidentifiable (Fig. 2). Transurethral resection was performed. The tumor was firm and bled little and on resecting its pedicle, a normal ureteral lumen could be observed in the medial aspect of the cut surface. Microscopically, the tumor was composed of loose connective tissue covered by normal transitional epithelium. Multiple subepithelial cell nests, so-called

Brunn's nests, were also present but inflammatory cell infiltration was scarce (Fig. 3). Histological diagnosis was a benign fibroepithelial polyp.

Considering the benign nature of the disease, percutaneous nephrolithotomy (PNL) was performed at first and all renal stones were easily removed. A postoperative nephrostogram revealed that the right ureter was markedly dilated throughout its length but showed active peristaltic movements. Open ureterolithotomy was carried out five days after PNL. There was much difficulty in dissecting the ureter owing to severe periureteral adhesion. On ureterotomy, the ureteral wall was found to be markedly thickened and the stone to be impacted snugly. The ureteral mucosa distal to the calculi showed tiny polypoid lesions, which were neither resected nor coagulated. A 8.5 Fr single J ureteral stent was placed in the kidney and bladder to exit from a percutaneous cystostomy. Postoperative convalescence was uneventful. The ureteral stent was removed on the eighth postoperative day and the nephrostomy catheter on the tenth day. An intravenous urogram at one month postoperatively showed that right hydronephrosis was persistent but excretory function recovered considerably. The calculus measured 4×3×3 cm and weighed 15 g. Its surface had a rough dentation and a cut section showed multiple concentric layers of crystalliza-

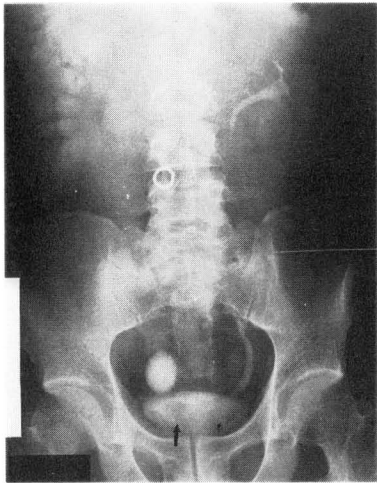

Fig. 1. Intravenous urogram shows right hydronephrosis, giant calculus and intravesical filling defect (arrow).

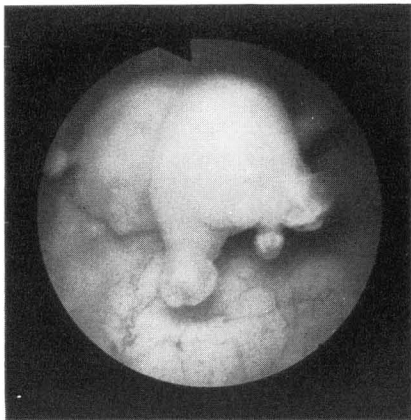


Fig. 2. Cystoscopy shows irregular and polypoid tumor.

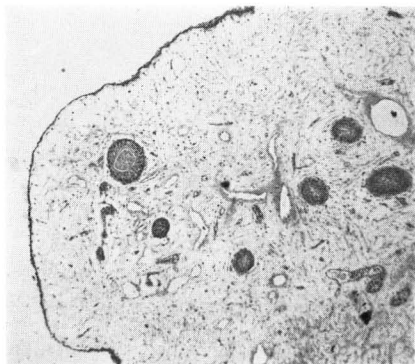


Fig. 3. Microscopically, tumor consists of loose connective tissue surrounded with transitional epithelium. Subepithelial cell nests can be seen (H & E,  $\times 40$ ).

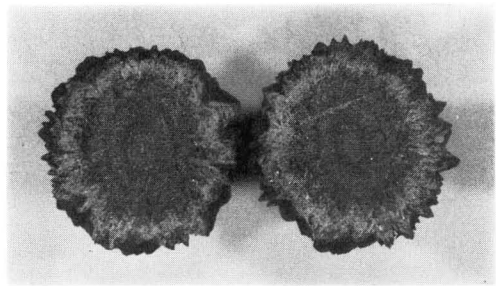


Fig. 4. Cut surface of calculus shows multiple concentric layers of crystallization.

tion (Fig. 4). Stone analysis revealed that all parts of the ureteral stone consisted purely of calcium oxalate, as well as the renal calculi.

#### DISCUSSION

Benign fibroepithelial polyps of the ureter are rare. Such factors as obstruction, trauma, irritation, infection, exogenous or endogenous carcinogens, hormonal imbalance, and allergy have been proposed as causative agents<sup>1)</sup>. Stones may cause chronic irritation of the ureteral wall, with or without urinary infection but their actual role is uncertain. Of 74 patients with histologically proved benign fibrous polyps of the ureter recently reviewed by Chang et al<sup>1)</sup>, only six had polyps associated with concomitant stones<sup>1-6)</sup>. In three of them<sup>1-3)</sup> coexistence of stones and polyps seems to be incidental because stones were in the calyces. One patient<sup>4)</sup> had passed ureteral calculi spontaneously five years previously and had another concomitant stone in the calyx. Another patient<sup>5)</sup> had a ureteral stone with a several-month duration caudal to the polyp.

The case reported by Melicow et al.<sup>6)</sup> is interesting in this regard. The patient had severe hydroureteronephrosis with pyonephrosis, a stricture at the left ureteropelvic junction and a 4 cm polyp suspending from it. There were multiple renal calculi, a small ureteral calculus impacted at the stricture and two large calculi (each  $2 \times 2 \times 1.5$  cm, 5 g) in the lower ureter. All calculi were clearly infection-related ones. A logical explana-

tion seems to be that both the stricture and polyp resulted from constant irritation of the ureteral mucosa at the ureteropelvic junction caused by urinary calculi.

It is hard to believe in our case that such a giant and spiculate calculus descended from the kidney. The impacted stone must have increased in the ureter. The ureter must be markedly dilated for a ureteral stone to grow into an ovoid shape, instead of an elongated form as a giant ureteral stone usually does. Furthermore, a long time is necessary for a stone to grow to this large size in the absence of urinary infection. In our case, we believe that the stone was impacted in the lowermost ureter at the Waldyer's sheath and that the polyp developed as a local reaction to chronic irritation caused by the stone. The stone must have been present for over twenty years, as the patient's history shows, and urinary infection must have played no role in the process of stone growth, as stone analysis shows.

The causes of the majority of fibroepi-

thelial polyps are unknown and they are usually considered to be hamartomatous growth. Although the histological appearance may be identical, the polyp in our case was probably a local response to chronic irritation and may be pathogenetically different from other reported cases.

#### REFERENCES

- 1) Chang HH, Ray P, Ockuly E and Guinan P: Benign fibrous ureteral polyps. *Urology* **30**: 114-118, 1987
- 2) Howard TL: Giant polyps of ureter. *J Urol* **79**: 397-402, 1958
- 3) Sommerhaug RG and Mason T: Peutz-Jeghers syndrome and ureteral polyposis. *JAMA* **211**: 120-122, 1970
- 4) Hughes FA and Davis CS: Multiple benign ureteral fibrous polyps. *Am J Roentgenol* **126**: 723-727, 1976
- 5) Vandendris M: Fibrous polyp of the ureter. *Br J Urol* **51**: 233, 1979
- 6) Melicow MM and Findlay HV: Primary benign tumors of the ureter. *Surg Gynecol & Obstet* **54**: 680-689, 1932

(Accepted for publication May 31, 1988)

#### 和文抄録

#### 尿管ポリープの膀胱内脱出を伴った巨大尿管結石の1例

倉敷中央病院泌尿器科 (部長: 吉田修三)

寺井 章人, 寺地 敏郎, 吉田 修三

37歳男性が、20年以上前から間欠的に継続する右下腹部痛のため入院した。右尿管下端部の巨大結石および尿管ポリープ (径 2 cm) の膀胱内脱出が認められ、経尿道的ポリープ切除と右尿管切石術により治療せしめた。ポリープは組織学的に良性の線維上皮性ポリープであった。結石は 4×3×3 cm, 15 g で純粋なシュウ酸カルシウムからなっていた。ポリープは結石

による慢性的刺激の結果生じたものと思われた。外国の文献で尿管の線維上皮性ポリープは74例報告されているが、結石を合併したものは6例のみで、両者の因果関係は不明であった。自験例は組織学的には線維上皮性ポリープと診断されたが、他のものとは発生機序が異なるのかもしれない。

(泌尿器要 **35**: 871-873, 1989)