

Title	Leiomyoma of the spermatic cord extending along the vas deferens
Author(s)	SAKAI, Naoki; YAMADA, Tetsuo; MURAYAMA, Tetsuo; ASAO, Takeshi
Citation	泌尿器科紀要 (1998), 44(2): 121-123
Issue Date	1998-02
URL	http://hdl.handle.net/2433/116119
Right	
Type	Departmental Bulletin Paper
Textversion	publisher

LEIOMYOMA OF THE SPERMATIC CORD EXTENDING ALONG THE VAS DEFERENS

Naoki SAKAI, Tetsuo YAMADA and Tetsuo MURAYAMA
From the Department of Urology, Sagamihara National Hospital

Takeshi ASAO
From the Department of Pathology, Sagamihara National Hospital

We report an unusual case of a leiomyoma of the spermatic cord. The tumor did not present as a mass but presented as a hard structure along the spermatic cord. To our knowledge, this is the first case report of a leiomyoma of the spermatic cord with such an unusual appearance.

(Acta Urol. Jpn. 44: 121-123, 1998)

Key words: Leiomyoma, Spermatic cord, vas Deferens

INTRODUCTION

Leiomyoma is a benign neoplasm that generally presents as a mass. Leiomyoma of the spermatic cord is an extremely uncommon neoplasm. Only a few cases have been reported in the literature¹⁻⁶⁾ All of them have been reported to present as a mass in the spermatic cord. We report an unusual case of a leiomyoma of the spermatic cord presenting as a hard spermatic cord. To our knowledge, this is the first case report of such a tumor.

CASE REPORT

A 67-year-old man presented with left scrotal pain and a 1-year history of a thick and hard linear structure; he did not notice any enlargement in the left inguinal region. The medical history was unremarkable. A physical examination revealed that it was approximately 1 cm in diameter,

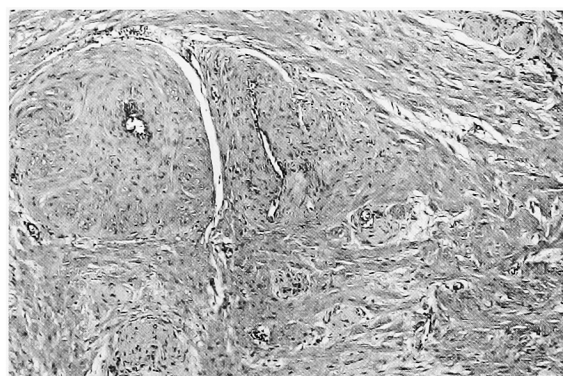
extending along the left spermatic cord. Laboratory studies including urinalysis were negative. High-resolution inguinal sonography showed an isoechoic, thick spermatic cord but did not show the "whorled appearance"; typical of leiomyomas developing in other sites. We considered inflammatory disorders, such as tuberculosis. In order to identify the linear structure, an operation was performed through a left

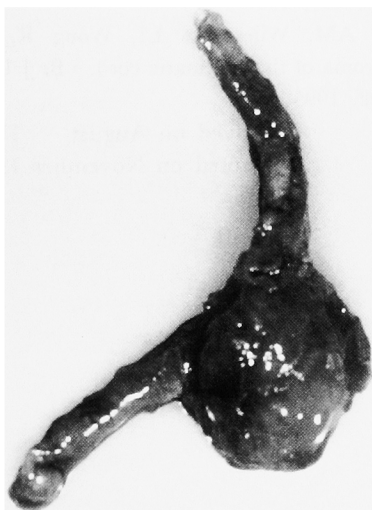
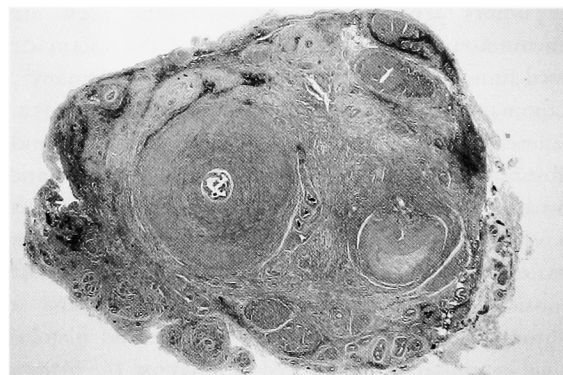
Fig. 1. Macroscopic appearance of the resected specimen. Upper; vas deferens. Center; tail of the epididymis with surrounding fat. Lower left; head and body of the epididymis.



A



B

Fig. 2. Microscopic findings of the leiomyoma of the spermatic cord. (A): Left; vas deferens. Right; spermatic vessels. HE stain. Original magnification $\times 3.3$. (B): Interlacing bundles of smooth muscle cells are seen. HE stain. Original magnification $\times 25$.

inguinal incision. An intraoperative examination revealed that the vas deferens was thick and hard from the junction with the epididymis, extending beyond the internal inguinal ring. As the vas was easily dissected from the spermatic cord and the testis appeared to be normal, it was resected up to the portion at the internal inguinal ring, with the epididymis (Fig. 1). Macroscopically, the surgical specimen showed a white cut surface of a markedly thick vas deferens. A pathological examination revealed that the vas deferens itself was normal but appeared to be somewhat constricted (Fig. 2A). The vas deferens and neighboring blood vessels were surrounded by irregularly proliferated smooth muscular tissues appearing to be occasionally transitional to the muscular layer of the blood vessels (Fig. 2B). The lumen of the epididymis was dilated, especially in the tail (not shown). No mitosis was seen in the lesion. These findings were pathologically identical with those of leiomyoma, although the lesion did not form a mass. Histological diagnosis was vascular leiomyoma of the spermatic cord.

DISCUSSION

Tumors arising from the spermatic cord are uncommon. Approximately 70% of the spermatic cord tumors are benign, while 30% are malignant¹⁾. Lipomas are the most common tumors in this area, followed by mixed mesodermal tumors, and fibromas¹⁾. In contrast, leiomyoma of the spermatic cord is an extremely rare tumor with a few cases having been reported¹⁻⁶⁾. They usually develop in patients between 40 and 60 years of age¹⁻⁶⁾. The consistency is between that of a lipoma and a fibroma⁶⁾. However, surgical excision and histological examination is required to diagnose the benign nature of the tumor.

Clinically, most spermatic cord tumors appear as a discrete nodular mass. Leiomyoma in other areas generally presents as a mass. Leiomyomas of the spermatic cord also present as a painless mass¹⁻⁶⁾. However, in this case the neoplasm did not present

as a mass but extended along the vas deferens. To our knowledge, this is the first reported case of a leiomyoma of a spermatic cord with such an unusual appearance.

Leiomyoma is a benign neoplasm that could arise from any organ containing smooth muscle cells¹⁾. Leiomyoma of the spermatic cord could originate from the smooth muscle of the cremaster, blood vessels of the cord, and the vas deferens¹⁾. In this case, a microscopic examination revealed that the proliferated smooth muscle tissues were transitional to the vessel walls. Therefore, we consider that the neoplasm developed from the blood vessels in the spermatic cord.

In this case, the epididymal lumen was dilated, especially in the epididymal tail. Histologically, the proliferated tissues compressed the vas deferens. Therefore, it is possible that the obstruction of the vas deferens resulted in the dilation of the epididymal lumen.

In conclusion, it should be noted that, although the exact mechanism remains unclear, leiomyoma can extend along the vas deferens without forming a mass.

REFERENCES

- 1) Belis JA, Post GJ, Rochman SC, et al.: Genitourinary leiomyomas. *Urology* **18**: 424-429, 1979
- 2) Dougall AJ and Wilson RR: Leiomyoma of the vas deferens. *Br J Urol* **41**: 348-350, 1969
- 3) Sarma DP and Weilbaecher TG: Leiomyoma of the spermatic cord. *J Surg Oncol* **28**: 318-320, 1985
- 4) Kawashima K, Matsuo Y, Shimizu N, et al.: A case of leiomyoma of the spermatic cord. *Acta Urol Jap* **34**: 1479-1481, 1988
- 5) Elmer EB, Levine R and Nolan J: Leiomyoma of spermatic cord with unusual features. *Urology* **33**: 236-237, 1989
- 6) Taylor AM, Wijesuriya LI, Wong R, et al.: Leiomyoma of the spermatic cord. *Br J Urol* **75**: 101-102, 1995

(Received on August 11, 1997)
(Accepted on November 13, 1997)

和文抄録

精管に沿って発生した精索平滑筋腫の1例

国立相模原病院泌尿器科 (医長: 村山鉄郎)

酒井 直樹, 山田 哲夫, 村山 鉄郎

国立相模原病院検査科 (医長: 浅尾武士)

浅 尾 武 士

腫瘍の形成はなく, 精管に沿って発生した精索平滑筋腫の1例を報告する. 精索に発生した平滑筋腫でこのような特異な形態を呈した症例は文献上報告がな

く, 本症例が最初の報告である.

(泌尿紀要 44: 121-123, 1998)