

Title	Mainz pouch with appendix-umbilical stoma using catheterizable conduit elongated with continuous cecal segment: a case report
Author(s)	OKADA, Yusaku; YOSHIMURA, Naoki; TAKAMI, Nobuhiko; KAKEHI, Yoshiyuki; TERACHI, Toshiro; YOSHIDA, Osamu
Citation	泌尿器科紀要 (1996), 42(12): 973-975
Issue Date	1996-12
URL	http://hdl.handle.net/2433/115866
Right	
Type	Departmental Bulletin Paper
Textversion	publisher

MAINZ POUCH WITH APPENDIX-UMBILICAL STOMA USING CATHETERIZABLE CONDUIT ELONGATED WITH CONTINUOUS CECAL SEGMENT : A CASE REPORT

Yusaku OKADA, Naoki YOSHIMURA, Nobuhiko TAKAMI
Yoshiyuki KAKEHI, Toshiro TERACHI and Osamu YOSHIDA
From the Department of Urology, Faculty of Medicine, Kyoto University, Kyoto, Japan

The Mainz pouch with appendix-umbilical stoma is a very stable method for continent, self-catheterizable urinary reservoir in the presence of a healthy appendix. If the appendix is too short or an unexpected stenosis is seen at its distal portion, the elongation of the conduit using a part of the cecum and the implantation of the conduit to the pouch by the Mitrofanoff method can be a good alternative procedure. We herein report our experience in a 53-year-old male with high grade, invasive bladder tumor, who underwent cystourethrectomy and appendix Mainz pouch operation using the above technique.

(Acta Urol. Jpn. 42: 973-975, 1996)

Key words : Continent urinary diversion, Appendix Mainz pouch, Short appendix, Cecal elongation

INTRODUCTION

The Mainz pouch with appendix-umbilical stoma¹⁾ can be one of the most attractive forms of the catheterizable cutaneous continent diversions now available, in the presence of the healthy, good appendix, which can be used as an excellent catheterizable conduit. However, the appendix is not always available. Even if it is present, the lumen may be obliterated due to inflammation, carcinoid tumor or mucocoele in about one third of the cases²⁾. When the appendix is too short to reach the skin or it has a single stenosis located in the distal portion, elongation of the catheterizable conduit using an autosuture³⁾ can be a good alternative method. Among 12 patients who underwent urinary reconstruction using the appendix either as a catheterizable conduit or as a urinary conduit⁴⁾, one patient with the shortened appendix is herein reported focusing on the operative procedure and its clinical implications.

OPERATIVE TECHNIQUE

The method was originally reported by Mitchell's group³⁾ in constructing continent appendicovesicostomy in children with neurogenic bladder or vesical exstrophy to facilitate intermittent catheterization. The portion of cecum is tubularized to elongate the conduit, using a GIA stapler® (GIA 50P No. 030470, cartilage No. 030424, US Surgical Co., Norwalk, Connecticut, USA), and the freed appendico-cecal tube is reimplanted by the Mitrofanoff's method. Care should be taken to preserve the blood supply from the appendicular artery, and the appendix is severed from the inferior

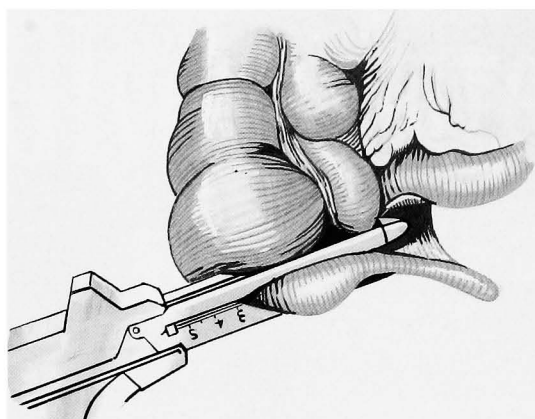
aspect of the cecum, placing the jaws of the stapler in such a way to lengthen the available tube. The isolated appendix is opened distally and proximally. Implantation of the conduit was performed along the tenia by Leadbetter's method from outside of the pouch.

CASE REPORT

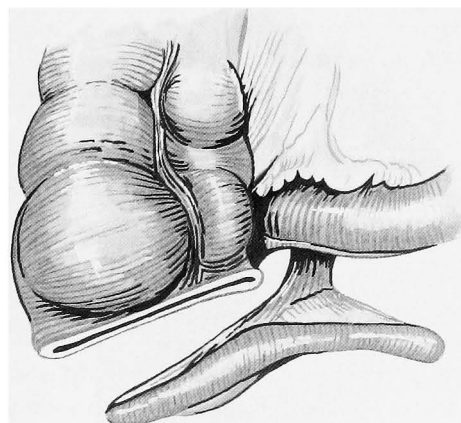
The patient was a 53-year-old male suffering from invasive bladder cancer (transitional cell carcinoma, G3, pT1b with diffuse carcinoma in situ (CIS)). He denied any history of appendicitis. Radical cystourethrectomy with a Mainz pouch was performed in January, 1995. During the operation, a 15 cm portion of the right colon and 30 cm portion of the terminal ileum was isolated. The appendix appeared to be healthy and it measured 8 cm in length. From the opened distal tip, bougienage was tried. At 3 cm from the distal tip, however, there was a severe stenosis of the lumen. The cecum was then incised and antegrade bougienage was tried. There was no additional obstruction. A 3 cm long distal segment of the appendix was cut off including the stenotic portion to render a 5 cm long appendix. The appendicular conduit was elongated with the cecum using a GIA stapler®, making a 9 cm long conduit (Fig. 1).

After completion of Mainz pouch, the freed appendicocecal tube was implanted along the tenia using Leadbetter's method. A 3 cm long distal portion was embedded submucosally. The proximal portion was anastomosed to the umbilical funnel end-to-end to make the appendicocutaneous stoma.

The postoperative course was uneventful. The patient started self-catheterization three weeks after



A



B

Fig. 1. A, GIA stapler is being placed across the inferior aspect of the cecum so that appendiceal conduit can be lengthened. B, Elongated appendix is isolated on its vascular pedicle. (Reproduced from literature 3).

the operation using a 14 Fr. catheter without any difficulty. The capacity of the pouch became 500 cc in three weeks, and he has been well without recurrence of tumor for 12 months postoperatively.

DISCUSSION

The Mainz pouch with appendix-umbilical stoma¹⁾ can be one of the most attractive forms of the catheterizable cutaneous continent diversions now available, in the presence of a healthy, good appendix, which can be used as an excellent catheterizable conduit. The length of the appendix must be at least 9–10 cm and it should be dilatable up to 16–18 Fr. without difficulty by bougienage¹⁾ The submucosally embedded in situ appendix is brought to the umbilicus and approximated to the umbilical funnel.

The characteristics of this method are; 1) excellent body image because of disappearance of intestinal mucosa from the skin level, 2) easy catheterization even for obese patients or patients confined to a wheelchair, 3) complete continence, and 4) rare

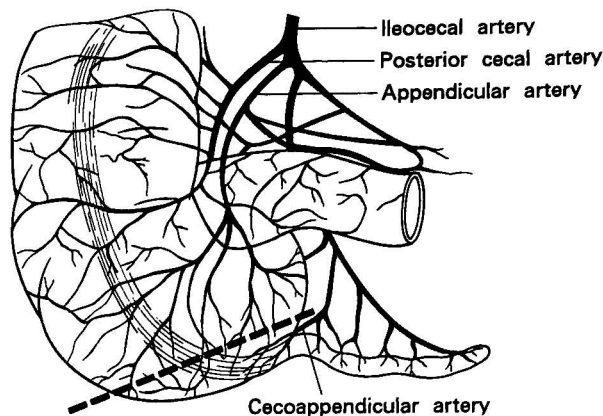


Fig. 2. Blood supply to the vermiform appendix and cecum. The appendicular artery descends behind the termination of the ileum and it anastomoses with a branch from the posterior cecal artery.

complication of parastomal hernia due to strong fascia at the umbilicus. However, the appendix is not always available. The frequency of histological abnormalities in the appendix is reportedly relatively high; fibrous obliteration in 28.7%, carcinoid tumor in 1.6%, and mucocele in 0.8% out of 122 urological patients²⁾. When the stenosis is not complicated and located in the distal portion, elongation of the conduit using the cecum is a useful method to obtain adequate length. In isolating the conduit with a good blood supply, it is important to avoid injury to the appendicular artery which anastomoses to the posterior cecal artery and to preserve the cecoappendicular artery (Fig. 2)⁵⁾

The disadvantage of the appendix stoma is that only a narrow catheter (14 to 16 Fr.) can be used for the drainage of urine, making it difficult to irrigate the reservoir to remove mucus. If the appendix turns out to be unusable as a conduit, our policy is to change it to the Indiana pouch by the ileal patching method. Therefore, the appendix should be examined for its patency at an early step of the operative procedure. In the presence of a healthy, good appendix, we feel that the Mainz pouch with appendix-umbilical stoma can be one of the most attractive forms of the catheterizable cutaneous continent diversions now available.

REFERENCES

- 1) Riedmiller H, Burger R, Muller S, et al.: Continent appendix stoma: a modification of the Mainz pouch. *J Urol* **43**: 1115–1117, 1990
- 2) Leibovitch I, Avigad I, Nativ O, et al.: Frequency of histopathological abnormalities in incidental appendectomy in urological patients: the implications for incorporation of the appendix in urinary tract reconstruction. *J Urol* **148**: 41–43, 1992

- 3) Sumfest JM, Burns MW and Mitchell ME: The Mitrofanoff principle in urinary reconstruction. J Urol **150**: 1875-1878, 1993
- 4) Okada Y, Ogura K, Ueda T. et al. : Use of the appendix in urinary reconstruction as a urinary conduit and catheterizable conduit : experience in 12 patients. Int J Urol (in press)
- 5) Gray's Anatomy, 36 th ed., Williams & Warwick (eds), p. 716, Churchill-Livingstone, Norwich, 1980

(Received on July 29, 1996)
(Accepted on August 20, 1996)

和文抄録

盲腸を利用して虫垂導尿管の延長を図った虫垂臍ストーマ Mainz pouch の1例

京都大学医学部泌尿器科学教室 (主任: 吉田 修教授)

岡田 裕作, 吉村 直樹, 高見 信彦
笥 善行, 寺地 敏郎, 吉田 修

虫垂臍ストーマ Mainz pouch は、自己導尿管型尿管変向のうちでも最も安定した術式の一つである。しかし、種々の原因で虫垂が短い場合、導尿管に利用するには困難になることがある。われわれは、8 cm の虫垂の遠位側 3 cm に強い炎症性狭窄が術中に判明した症例で、盲腸部を GIA 自動縫合器を用いて管状化することにより、虫垂導尿管の延長 (4 cm の延長で計

9 cm) を図った。得られた遊離虫垂を Mitrofanoff 法でパウチ吻合を行い、盲腸側断端を臍窩と吻合した。術後経過は順調で、軽度ストーマ狭窄はあるもののブジーのみで軽快し、良好な結果がえられたので手術手技を中心に報告した。

(泌尿紀要 **42** : 973-975, 1996)