

Title	A pediatric case of ureteropelvic junction obstruction treated with retrograde endopyelotomy
Author(s)	UMEKAWA, Tohru; ISHIKAWA, Yasuaki; KAJIKAWA, Hiroshi; IGUCHI, Masanori; KURITA, Takashi
Citation	泌尿器科紀要 (1996), 42(11): 895-898
Issue Date	1996-11
URL	<a href="http://hdl.handle.net/2433/115845">http://hdl.handle.net/2433/115845</a>
Right	
Type	Departmental Bulletin Paper
Textversion	publisher

## A PEDIATRIC CASE OF URETEROPELVIC JUNCTION OBSTRUCTION TREATED WITH RETROGRADE ENDOPYELOTOMY

Tohru UMEKAWA, Yasuaki ISHIKAWA, Hiroshi KAJIKAWA,  
Masanori IGUCHI and Takashi KURITA

*From the Department of Urology, Kinki University School of Medicine*

To determine the feasibility of retrograde endopyelotomy in the management of pediatric ureteropelvic junction (UPJ) obstruction, we treated one girl aged 6 years with the Acucise® cutting balloon device for symptomatic UPJ obstruction. The Acucise catheter (7 Fr, flexible) was placed by a cystoscope over a guide wire with fluoroscopic guidance under general anesthesia. After cutting the stenotic area electrically and dilation until 24 Fr for 10 seconds, a 6/10 Fr endopyelotomy ureteral catheter was left in situ for 8 weeks after the operation. Total operating time was 45 minutes and the child was discharged 3 days after the operation. There were no acute complications and short-term, follow-up 8 months after the operative results were satisfactory as determined by intravenous pyelography and diuretic renogram. UPJ obstruction in children may be treated by retrograde endopyelotomy with the Acucise® catheter as well as adults. The principal potential advantage of this procedure is reduced morbidity as compared with antegrade endopyelotomy.

(Acta Urol. Jpn. 42: 895-898, 1996)

**Key words:** Ureteropelvic junction obstruction, Acucise® cutting balloon device, Endopyelotomy, Retrograde endopyelotomy, Endourology

### INTRODUCTION

Ureteropelvic junction (UPJ) obstruction is identified frequently in children. Although they traditionally present with a history of urinary tract infections, flank pain, or failure to thrive, they are now diagnosed prenatally and are asymptomatic. Traditional treatment of UPJ obstruction has been by open plastic surgical techniques. Dismembered pyeloureteroplasty is the standard treatment, with a success rate of over 90%<sup>1,2)</sup>. However, open pyeloplasty has several drawbacks, including significant postoperative pain, prolonged convalescence, and a prominent skin incision. In an effort to overcome the shortcomings of this procedure, several endoscopic techniques have been developed as alternative to open pyeloplasty<sup>3-11)</sup>. Although percutaneous antegrade endopyelotomy has reduced the morbidity of treating UPJ obstruction in adults, it has not replaced open surgery in children. The morbidity of percutaneous nephrostomy drainage tubes, the relatively large caliber of the endoscopes and accessories used in treatment, and success rate of 64% to 89%<sup>8-11)</sup> have limited the enthusiasm for its use in children<sup>12)</sup>.

Retrograde endopyelotomy with the Acucise® cutting balloon device (Acucise®, Applied Medical, Laguna Hills, CA) is a recently reported technique for the management of adult UPJ obstruction<sup>13)</sup> (Fig. 1). To determine if it is feasible in children, we treated one girl aged 6 years.

### CASE REPORT

A 6-year-old girl (weight 18.0 kg) presented with episodes of abdominal pain associated with microhematuria. Abdominal ultrasonography revealed a markedly dilated right renal pelvis and calices. Voiding cystourethrography revealed no reflux, furosemide diuretic renography and intravenous pyelograph (IVP) were consistent with a UPJ obstruction. The child's parents expressed the wish to avoid an open surgical incision. Although, the Acucise® catheter is generally utilized for the operation of retrograde endopyelotomy, that is not approved by the Japanese Ministry of Public Welfare for the medical treatment, although it is approved in the U.S.A..

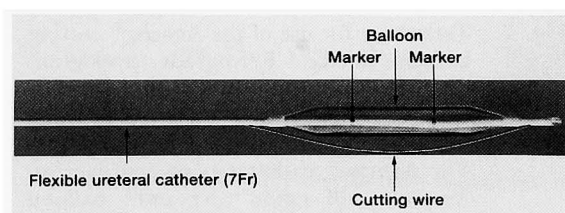


Fig. 1. Acucise® cutting balloon device is a flexible ureteral catheter (7 Fr) with a 3-cm long balloon (maximally dilated for 24 Fr), wide electro-surgical cutting wire (150 μm) and markers (cutting wire can be activated between them) for fluoroscopic guidance. For optimal efficiency, balloon inflation and incision of ureter are performed together.

An 13 Fr cystoscope was used to place an Amplatz stiff guide wire (0.035 inch, 150 cm, Applied Medical, Laguna Hills, CA). The Acucise® catheter was advanced over the guide wire and positioned across the UPJ under fluoroscopic control with the aid of radiodense markers on the balloon. The balloon was filled with 1 ml of 30% radiocontrast fluid to ensure satisfactory positioning at the level of the UPJ with a tight waist at the midpoint of the balloon. The balloon was distended progressively with an additional 1 ml of diluted radiocontrast fluid over 2 seconds period, during which incision was undertaken with a 75 W pure cutting current. Extravasation of contrast medium from the treated area was noted. The Acucise® catheter was withdrawn and a 6/10 Fr endopyelotomy ureteral stent was placed. The total operating time was 45 minutes and blood loss was negligible. A 14 Fr bag catheter was left in the bladder for 24 hours to optimized drainage (Fig. 2 and 3).

The child was discharged from our hospital three days after the operation. For few days, she experienced slightly urinary frequency, right lumbago and fever up, however, these symptoms resolved with anticholinergic agents and antibiotics. An otherwise uneventful recovery ensued and the stent was re-

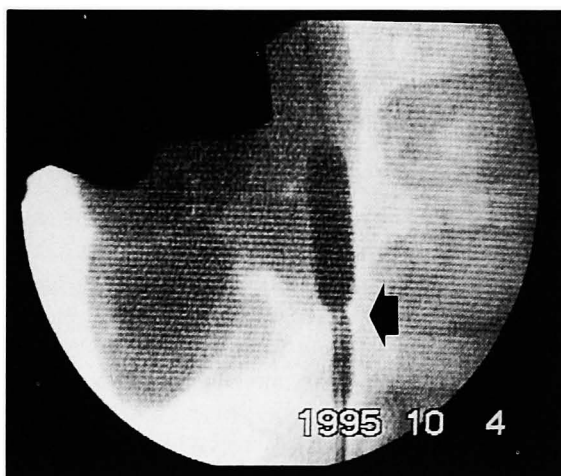

Fig. 2. Technique for use of the Acucise® cutting balloon device. Retrograde pyelogram demonstrates severe right hydronephrosis due to ureteropelvic junction (UPJ) obstruction and normal distal ureter. The Acucise® catheter is passed over an Amplatz stiff guide wire until balloon markers straddle area of UPJ obstruction and rotated until cutting wire is directed posteriolaterally. Cutting wire and balloon dilation (2 ml of contrast medium) are done together to achieve simultaneous incision and expansion of ureter. The stenotic area (←), where the balloon can not be expanded enough, on the balloon before cutting wire activation (pure cutting, 75 W for 3 seconds).

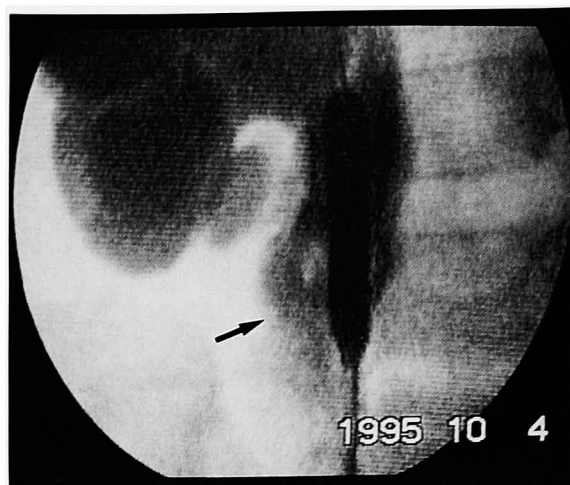
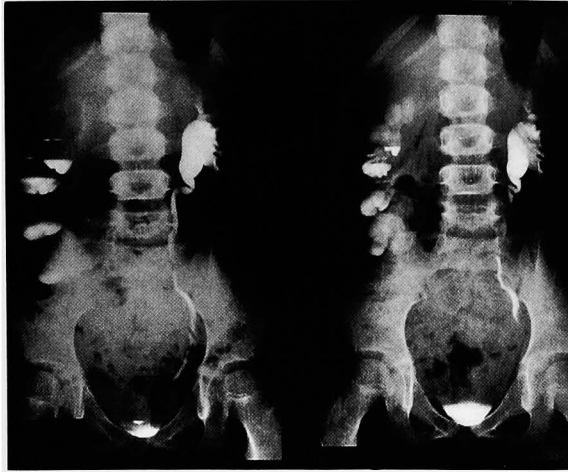

Fig. 3. Technique for use of the Acucise® cutting balloon device. The stenotic area on the balloon disappeared after cutting the wire activation. Extravasation of contrast medium (→) at area of obstruction confirms adequate incision by the Acucise® catheter.

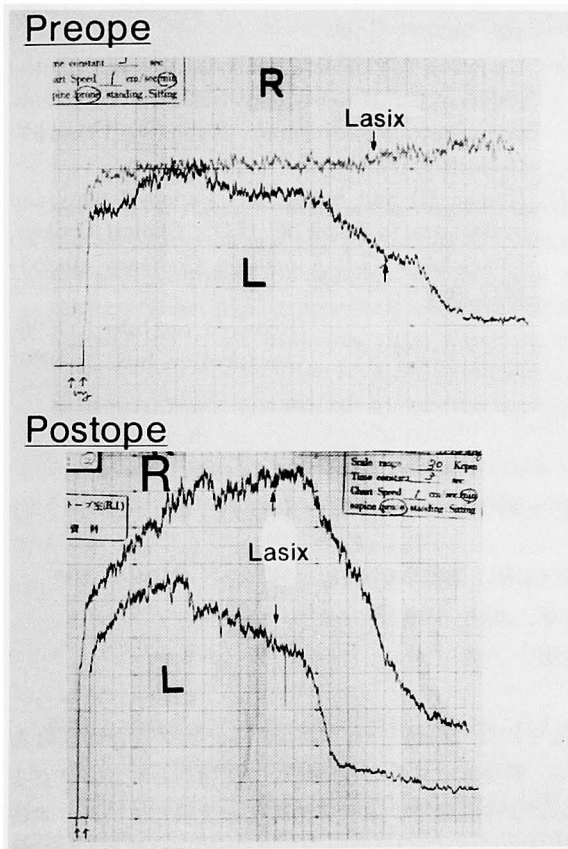
moved after 8 weeks after the operation. The child's initial complaints of abdominal pain were resolved, and an intravenous pyelogram and diuretic renal scan 8 months after the operation demonstrated reduction in the caliceal deformity and dilatation and suggested reduction of UPJ obstruction (Fig. 4).

#### DISCUSSION

The patient and surgeon have a variety of therapeutic options when faced with an UPJ obstruction. This has traditionally been treated by open pyeloplasty, which, although associated with a low complication rate, necessitates an abdominal or flank incision and a hospital stay of several days. Endoscopic procedures have substantially reduced the morbidity of treating UPJ obstruction in adults, but they have not been widely adopted in children<sup>1-3</sup>). Through antegrade endoscopic incision at UPJ is technically more challenging in the pediatric kidney and ureter, accounting for a greater failure rate. Retrograde endopyelotomy recently has been investigated as an alternative for reducing the morbidity of treating UPJ obstruction. Chandhoke and associates<sup>13</sup>) reported objective improvement of the upper urinary tracts in 24 of 28 patients (85%) after Acucise® retrograde endopyelotomy, and Albala and Asbury<sup>14</sup>) successfully treated 21 of 27 patients (78%) with the Acucise® catheter. In other hands, antegrade endopyelotomy was successful in about 70 ~80% of the treated cases<sup>4-11</sup>), thus it appears that antegrade and Acucise® retrograde endopyelotomy offer similar success rates. Our early findings indicate that retrograde endopyelotomy using the Acucise® catheter is technically feasible in treating UPJ obstruction even in children (at least above 6



IVP before endopyelotomy (left) and after 8 months (right).



Diuretic renogram before endopyelotomy (upper) and after 8 months (lower).

Fig. 4. Intravenous pyelogram (IVP) and diuretic renal scintigraphy using <sup>123</sup>I-Hippuran 8 months after retrograde endopyelotomy by the Acucise® cutting balloon device demonstrates reduction in caliceal and pelvic dilation and improvement of patency in ureteropelvic junction.

years) as well as adults<sup>13,14</sup>).

Preliminary human application of the Acucise® ureteral cutting balloon device was first reported in 1993<sup>13</sup>) Post-operative studies have demonstrated

normal upper urinary tracts in 71% of adult patients and an improved radiologic appearance in an additional 14%<sup>13</sup>) Since the patients treated in the series reported by Chandhoke et al.<sup>13</sup>) and Bolton et al.<sup>12</sup>) were between 16 and 81 years, our patient, at 6 years, is very young to be treated by this technique.

The potential advantages of retrograde endopyelotomy with the Acucise® catheter are based on a well-studied principle. Transmural ureteral incisions provide long-term relief of obstruction by healing around a stent, a physiologic principle first used by Davis<sup>15</sup>) However, in contrast to Davis's open incision from outside, the Acucise® device allows for a transmural ureteral incision from the inside of the ureter. Histologic studies have not revealed any significant differences in tissue injury after ureteral incision produced by a variety of methods, including the Acucise catheter and the cold knife<sup>11,12,17,18</sup>). The potential for damaging a lower pole renal vessel during a blind incision, resulting in lower pole renal ischemia or uncontrolled hemorrhage. Appropriate informed consent, however, should alter patients and their families of this potential, yet unlikely event<sup>12</sup>) Anecdotal reports have been made concerning significant hemorrhage after incising the UPJ, yet no description could be found to confirm this in the literature<sup>12,19,20</sup>). We believe this is likely to be a rare occurrence as the incision is performed only on the lateral aspect of the UPJ.

With further refinements in endopyelotomy, the renal challenge for the urologist may be diagnosing which patients with "asymptomatic" hydronephrosis will be followed conservatively<sup>21</sup>).

**ACKNOWLEDGMENTS**

We thank Mr. Morihara and Mr. Sumiyama (ADACHI Co. Ltd., Osaka, Japan) for help in preparing this manuscript.

**REFERENCES**

- 1) Gerber GS and Lyon ES : Endopyelotomy : patient selection, results, and complications. *Urology* **43** : 2-10, 1994
- 2) Saing H, Chan FL, Yeung CK, et al. : Pediatric pyeloplasty : 50 patients with 59 hydronephrotic kidneys. *J Pediatr Surg* **24** : 346-349, 1989
- 3) Tan HL, Najmaldin A and Webb DR : Endopyelotomy for pelvic-ureteric junction obstruction in children. *Eur Urol* **24** : 84-88, 1993
- 4) Ramsay JW, Miller RA, Kellet MJ, et al. : Percutaneous pyelolysis : indications, complications and results. *Br J Urol* **56** : 586-588, 1984
- 5) Motola JA, Badlani GH and Smith AD : Results of 212 consecutive endopyelotomies : an 8-year follow up. *J Urol* **149** : 453-456, 1993
- 6) Korth K, Kunkel M and Erschig M : Percutaneous pyeloplasty. *Urology* **31** : 503-509, 1988

- 7) Brannen GE, Bush WH and Lewis GP: Endopyelotomy for primary repair of ureteropelvic junction obstruction. *J Urol* **139**: 29-32, 1988
- 8) Van Cangh PJ, Jorion JL, Wese FX, et al.: Endoureteropyelotomy: percutaneous treatment of ureteropelvic junction obstruction. *J Urol* **141**: 1317-1322, 1989
- 9) Martelli A, Buli P, Spatafora S, et al.: Endourologic procedures for ureteropelvic junction stenosis: techniques and results. *Urol* **36**: 47-51, 1990
- 10) Cassis AN, Brannen GE, Bush WH, et al.: Endopyelotomy: review of results and complications. *J Urol* **146**: 1492-1495, 1991
- 11) Meretyk I, Meretike S and Clayman RV: Endopyelotomy: comparison of ureteroscopic retrograde and antegrade percutaneous techniques. *J Urol* **148**: 775-783, 1992
- 12) Bolton DM, Bogaert GA, Mevorach RA, et al.: Pediatric ureteropelvic junction obstruction treated with retrograde endopyelotomy. *Urology* **44**: 609-613, 1994
- 13) Chandhoke PS, Clayman RV, Stone AM, et al.: Endopyelotomy and endoureterotomy with the Acucise ureteral cutting balloon device: preliminary experience. *J Endourol* **7**: 45-51, 1993
- 14) Albala DM and Asbury JB: Acucise balloon catheter for the treatment of ureteropelvic junction obstruction (Abstract. 671). *J Urol* **151**: 671A, 1994
- 15) Davis DM: Intubated ureterotomy. *Surg Gynecol Obstet* **76**: 513-523, 1943
- 16) Oppenheimer R and Hinman Jr: Ureteral regeneration: contracture vs. hyperplasia of smooth muscle. *J Urol* **74**: 476-484, 1955
- 17) Figenshau RS, Clayman RV, Wick M, et al.: Acute histologic changes associated with endoureterotomy in the normal pig ureter. *J Endourol* **5**: 357-361, 1991
- 18) Aronson WJ, Barbaric Z, Fain J, et al.: Cautery-wire/balloon catheter for fluoroscopically guided incision of ureteral strictures: a phase I study in pigs. *J Endourol* **5**: 337-340, 1991
- 19) Brooks JD, Kavoussi LR, Preminger GM, et al.: Comparison of open and endourologic approaches to the obstructed ureteropelvic junction. *Urology* **46**: 791-795, 1995
- 20) Umekawa T, Yamate T, Ishikawa Y, et al.: Clinical results of percutaneous endopyelotomy for ureteropelvic junction obstruction. *Nishinon J Urol* **57**: 1073-1076, 1995
- 21) Horgan JD and Smith AD: Endopyelotomy and pyeloplasty, in Krane RJ (ED): *Clinical Urology*, Philadelphia. J.B. Lippincott Company, pp 433-443, 1994

(Received on July 1, 1996)  
(Accepted on July 19, 1996)

## 和文抄録

### 腎盂尿管移行部狭窄症に逆行性エンドピエロトミーを行った小児の1例

近畿大学医学部泌尿器科学教室 (主任: 栗田 孝教授)

梅川 徹, 石川 泰章, 梶川 博司  
井口 正典, 栗田 孝

右腎盂尿管移行部狭窄症の6歳女児に対し、アキュサイス®尿管切開バルーン装置 (軟性尿管カテーテル, 7 Fr) を用いた逆行性エンドピエロトミーを行いその実用性を検討した。全身麻酔下でアキュサイス®カテーテルを膀胱鏡操作下に腎盂内にまで挿入し、狭窄部を電氣的に切開しさらに同部位をバルーンで24 Frまで拡張した。切開終了後にエンドピエロトミー用尿管カテーテル (6/10 Fr) を留置し、これを8週間後に抜去した。手術時間は45分間で、患者は術

後3日目に退院した。特に手術に関する合併症はなく、術後8カ月目の経静脈性腎盂撮影と利尿レノグラムによる評価で、水腎症の程度は改善していた。本術式は順行性エンドピエロトミーに比べてはるかに侵襲性が低く、成人のみならず小児 (少なくとも6歳程度にまでは) にも実用性が期待できることが示唆された。

(泌尿紀要 **42**: 895-898, 1996)