

Title	Two cases of intrascrotal liposarcoma
Author(s)	KATSUNO, Satoshi; HIBI, Hatsuki; TAKASHI, Munehisa; YAMAMOTO, Masanori; MIYAKE, Koji; SAKATA, Takao
Citation	泌尿器科紀要 (1996), 42(10): 751-754
Issue Date	1996-10
URL	http://hdl.handle.net/2433/115829
Right	
Type	Departmental Bulletin Paper
Textversion	publisher

TWO CASES OF INTRASCROTAL LIPOSARCOMA

Satoshi KATSUNO, Hatsuki HIBI, Munchisa TAKASHI,
Masanori YAMAMOTO and Koji MIYAKE

From the Department of Urology, Nagoya University School of Medicine

Takao SAKATA

From the Department of Urology, Kasugai Municipal Hospital

Liposarcomas in the scrotum are relatively rare and only 40 cases have previously been reported in Japan. The inside wall of the scrotum is an unusual origin and we report here two cases arising at this site that have been followed for 21 and 40 months, respectively, after surgical resection. Case 1: the patient was a 24-year-old male who noticed a left intrascrotal mass which was histologically demonstrated to be a myxoid type liposarcoma. Case 2: the patient was a 66-year-old male who had the complaint of a left intrascrotal swelling. He underwent radical orchiectomy and histologic examination of the resected tumor revealed a well-differentiated type of liposarcoma. These two cases are the 41st and 42nd intrascrotal liposarcomas reported in Japan.

(Acta Urol. Jpn. 42: 751-754, 1996)

Key words: Liposarcoma, Scrotum

INTRODUCTION

Liposarcomas, which comprise about 15% of malignant soft tissue tumors, are derived from primitive mesenchymal cells and show various stages of differentiation to lipoblasts¹⁾ The intrascrotal area, particularly the wall of the scrotum, is an unusual site of origin²⁾ Preoperative diagnosis is usually difficult²⁻⁶⁾. Most intrascrotal liposarcomas are of a low-grade malignancy, and treatment is wide local excision with radical orchiectomy^{2-5,7,8)} At present there are no clear indications for chemotherapy and radiotherapy. Long-term follow-up is necessary because the propensity for local recurrence is high. Herein we report two cases of liposarcoma arising in the scrotum.

CASE REPORTS

CASE 1.

The patient was a 24-year-old male who presented with a two-week history of a bulge about 4 cm in diameter in the left scrotum. There was no tenderness in the area. He had undergone resection of a joint mouth at the left elbow joint at 14 years of age.

Physical examination revealed a painless, soft mass without transillumination near the left testis but separated from the testis and other scrotal contents. The white blood cell count was elevated at 9,900/mm³ Serum basic fetoprotein (BFP) was also above the normal range (130 ng/ml as compared to less than 75 ng/ml), but the alpha-fetoprotein level was normal at 3 ng/ml. Chest X-ray findings were normal and a scrotal X-ray demonstrated no calcified lesion. Scrotal ultrasonography showed a homogeneous soft tissue mass in the left scrotum.

Computed tomography (CT) revealed a homogeneous mass. Bone scintigraphy demonstrated no hot areas. The preoperative diagnosis was an intrascrotal tumor.

Under lumbar anesthesia the left scrotal skin was incised. The tumor was clearly separated from the left testis and spermatic cord, and could be simply dissected from the scrotal wall since it was covered with a fibrous thin capsule. The gross specimen was 5.5×4.5×4.2 cm in size and was 28 gm in weight, the cut surface being gelatinous, and brownish red (Fig. 1). Histologic examination revealed a myxoid type liposarcoma (Fig. 2).

After the operation, serum BFP decreased to 89 ng/ml. No postoperative chemotherapy or radiation therapy was performed and he was found to be well with no evidence of recurrence 21 months after the operation.

CASE 2.

A 66-year-old male was admitted with a complaint of left intrascrotal swelling. He had noticed a small mass on the left scrotum 20 years previously but it had become markedly enlarged within the last 2 months. He had no history of local trauma.

Physical examination revealed a painless, elastic mass showing transillumination close to but separate from the left testis. A complete blood count revealed a slightly elevated number of white blood cells at 8,600/mm³ and chest X-ray results were normal. Scrotal ultrasonography showed a hyperechoic mass which was of low density without calcification on CT. There was no lymph node swelling and the preoperative diagnosis was of an intrascrotal tumor.

Under lumbar anesthesia, left high orchiectomy was performed. The complex multilobulated lipomatous tumor was adherent to the spermatic cord

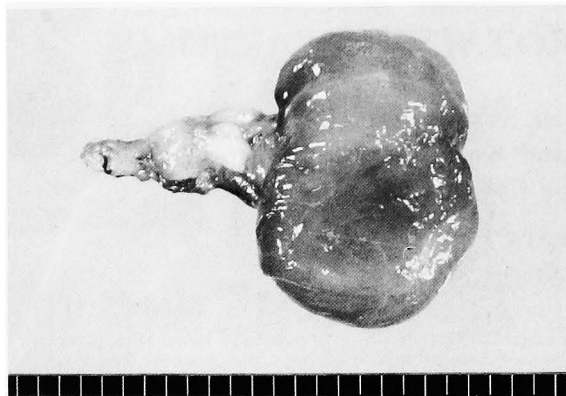

Fig. 1. Case 1. Macroscopic appearance of the tumor.

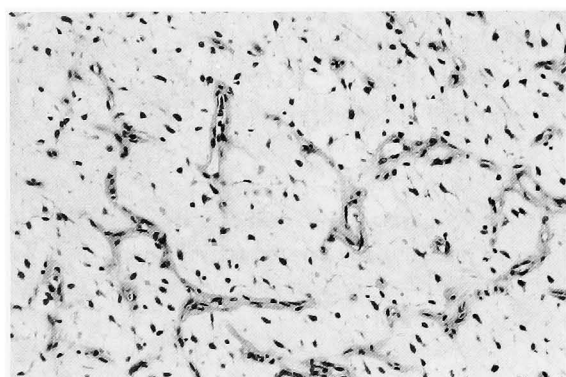


Fig. 2. Case 1. Histological appearance of the tumor (HE staining, $\times 140$). Note the solid structure with scant myxomatous stroma and the typical plexiform vascular pattern.

structures and scrotal wall, but was clearly demarcated from the testis. The gross specimen was $8.0 \times 3.0 \times 4.0$ cm in size, and weighed 150 gm (Fig. 3). Histologic examination revealed a well differentiated type of liposarcoma partially with bizarre giant cells (Fig. 4). No evidence of recurrence was present 40 months after the operation.

DISCUSSION

Paratesticular tumors are rare, more than 75% of these tumors arise from the spermatic cord. Most spermatic cord tumors are benign (70 to 80%) and are primarily comprised of lipomas, with nearly all malignant counterparts being sarcomas (90%). Rhabdomyosarcomas are the most aggressive and predominate in children and adolescents, whereas more differentiated sarcomas including leiomyosarcomas, fibrosarcomas and liposarcomas, are more frequently observed in the adult population. Liposarcomas represent 3 to 7% of all spermatic cord sarcomas reported⁴⁾ In Japan, Sone and associates (1987) reviewed 37 cases of intrascrotal liposarcoma⁷⁾, and 3 cases of spermatic cord liposarcoma have been reported thereafter. Our two cases are the 41st and 42nd intrascrotal liposarcomas reported in Japan.

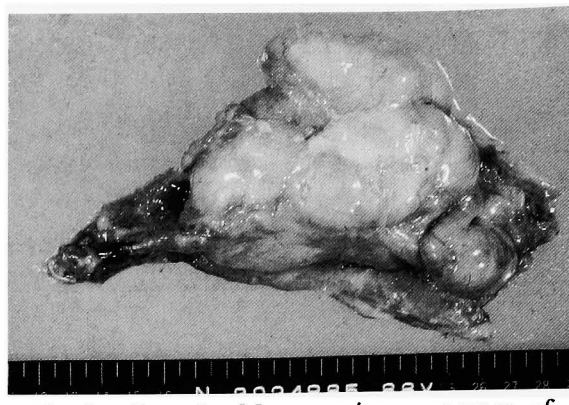


Fig. 3. Case 2. Macroscopic appearance of the tumor.

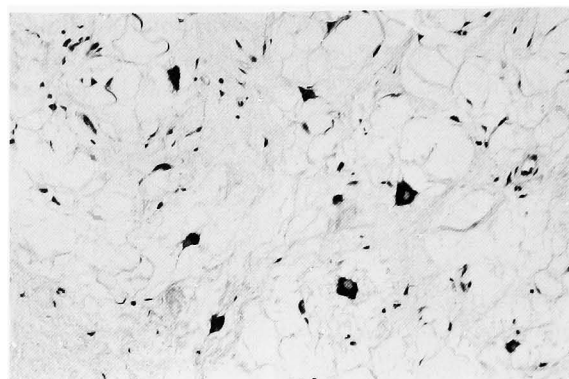


Fig. 4. Case 2. Histological appearance of the tumor showing well differentiated features partially with bizarre giant cells (HE staining, $\times 140$).

The mean age of the total of 42 patients was 54.3 years (ranging from 10 to 88 years). The patient in case 1 was thus quite young (24 years old). It is of interest that all six intrascrotal liposarcomas found in young patients (age range: 10 to 24 years) in Japan belonged to the myxoid type, including our case.

The causes of intrascrotal masses include testicular tumors, testicular torsion, hydrocele, and epididymitis. Liposarcomas have rarely been diagnosed preoperatively and have most commonly been mistaken as inguinal hernias or hydroceles. Rarely, liposarcomas may be accompanied by hematoma formation⁹⁾. Their occasional transillumination may lead to diagnostic confusion²⁻⁶⁾. However, liposarcomas are characteristically of low density and can be well-demarcated on CT^{3,10)}

Liposarcomas are derived from primitive mesenchymal cells and show various stages of differentiation to lipoblasts. Their gross appearance varies markedly, depending upon histologic type. Usually, the tumors consist of smooth, lobulated or nodular masses¹¹⁾, larger lesions often being multilobulated and having a variegated appearance⁴⁾ In most cases, the liposarcomas are encapsulated and can be detached easily from the surrounding tissues¹¹⁾. The first exploratory operation may in fact lead to tumor

resection because the apparent circumscription does not look like a malignancy¹²⁾.

The consistency and color of the tumors vary considerably with the histologic type. The jelly-like, moist, glistening appearance of myxoid tumors is often associated with lipoma-like features of the well-differentiated type, while some round cell and pleomorphic tumors have a more brainlike quality. The cut surfaces range in color from grayish white to different shades of red and yellow¹¹⁾, our findings thus being typical.

Regarding the histological classification of the World Health Organization, liposarcomas in general are subdivided into 5 categories: (1) myxoid, (2) round cell, (3) well-differentiated, (4) dedifferentiated and (5) pleomorphic types. In addition, there are several subtypes within the well-differentiated category: lipoma-like, inflammatory, and sclerosing¹⁾. The intrascrotal liposarcomas documented predominantly belong to the well differentiated or myxoid types.

Radical orchiectomy is the treatment of choice for this tumor^{2-5,7,8)}. Wide local incision is mandatory to prevent local recurrence⁸⁾. Retroperitoneal lymphadenectomy is not indicated since metastasis to the retroperitoneal lymph nodes has not been documented and metastatic spread is usually through the hematogenous route. Radical orchiectomy accompanied by retroperitoneal lymph node dissection seems not to improve patient survival⁸⁾.

Whether postoperative chemotherapy is necessary for the intrascrotal liposarcoma remains uncertain. Fukuma and associates have indicated that adjuvant chemotherapy may be needed when the liposarcoma mass (round cell or pleomorphic) is more than 5 cm in diameter while routine follow-up is sufficient, with intervention to control local recurrence, if the histological subtype is well differentiated or myxoid liposarcoma¹³⁾. Regarding radiotherapy, the myxoid liposarcoma appears to be the most radiosensitive of the subtypes^{9,14)}

Myxoid and well-differentiated liposarcomas demonstrate a much better prognosis (80% 5-year survival; 50% 10-year survival) than the more aggressive round cell and pleomorphic types (20% 5-year survival; 5% 10-year survival)¹⁴⁾ Regarding spermatic cord liposarcomas, no data on survival have been reported. However, there appears to be a significant relationship between survival and histologic type of tumor. Patients with low-grade well-differentiated and myxoid types of liposarcomas have a favorable prognosis, whereas high-grade, round cell or pleomorphic liposarcomas are more likely to cause death. Because local recurrence may

occur more than 10 years after the surgical resection^{3,4)}, long-term follow-up is mandatory.

REFERENCES

- 1) Enzinger FM and Weiss SW: Liposarcoma. In: Soft tissue tumors. Edited by Enzinger FM and Weiss SW. 3rd ed., : 431-466, Mosby-Year Book, St. Louis, 1995
- 2) Certo LM, Avetta L, Hanlon JT, et al.: Liposarcoma of spermatic cord. *Urology* **31**: 168-170, 1988
- 3) Schwartz SL, Swierzewski III SJ, Sondak VK, et al.: Liposarcoma of the spermatic cord: Report of 6 cases and review of the literature. *J Urol* **153**: 154-157, 1995
- 4) Vorstman B, Block NL and Politano VA: The management of spermatic cord liposarcomas. *J Urol* **131**: 66-69, 1984
- 5) Mackenzie I and Roberts GH: Liposarcoma of paratesticular origin: a case report. *Br J Urol* **46**: 467-470, 1974
- 6) Bissada NK, Finkbeiner AE and Redman JF: Paratesticular sarcomas: review of management. *J Urol* **116**: 198-200, 1976
- 7) Sone M, Doi J and Morikawa Y: Giant liposarcoma of the spermatic cord: a case report. *Acta Urol Jpn* **35**: 147-151, 1989
- 8) Torosian MH and Wein AJ: Liposarcoma of the spermatic cord: case report and review of the literature. *J Surg Oncol* **34**: 179-181, 1987
- 9) Lissmer L, Kaneti J, Klain J, et al.: Liposarcoma of the perineum and scrotum. *Int Urol Nephrol* **24**: 205-210, 1992
- 10) Isoyama R, Shirataki S, Takihara H, et al.: Utility of preoperative imaging diagnosis in spermatic cord liposarcoma. *Acta Urol Jpn* **36**: 721-724, 1990
- 11) Enzinger FM and Winslow DJ: Liposarcoma. A study of 103 cases. *Virchows Arch Pathol Anat* **335**: 335-388, 1962
- 12) Tanaka M, Hizawa K and Tonai M: A clinicopathological study on 136 cases based on the histologic subtyping of WHO. *Jpn J Cancer Clin* **20**: 1036-1047, 1974
- 13) Fukuma H, Beppu Y and Nishikawa K: Adjuvant chemotherapy in the treatment of primary soft tissue sarcomas with special reference to intra-arterial infusion chemotherapy. *Jpn J Cancer Chemother* **11**: 1729-1735, 1977
- 14) Bauer JJ, Sesterhenn IA and Costabile RA: Myxoid liposarcoma of the scrotal wall. *J Urol* **153**: 1938-1939, 1995

(Received on April 19, 1996)
(Accepted on June 16, 1996)

陰囊内脂肪肉腫の2例

名古屋大学医学部泌尿器科学教室（主任：三宅弘治教授）

勝野 暁，日比 初紀，高士 宗久，山本 雅憲，三宅 弘治

春日井市民病院泌尿器科（部長：安藤 正）

坂 田 孝 雄

陰囊内原発の脂肪肉腫は稀であり，わが国ではこれまでに40例の報告がみられるのみである．著者らは陰囊内に原発した脂肪肉腫の2例を経験したので文献的考察を加えて報告する．症例1は24歳男性．左側陰囊内腫瘍は，精巣・精索などの陰囊内容物と明らかに分離しており腫瘍摘除術を施行した．病理組織診断は脂

肪肉腫・類粘液型であり手術後21カ月再発を認めていない．症例2は66歳男性．左側陰囊内腫瘍は，精索より発生しており高位精巣摘除術を施行した．病理組織学的には脂肪肉腫・分化型であり手術後40カ月再発を認めていない

(泌尿紀要 42 : 751-754, 1996)