

Title	Lupus cystitis. report of a case
Author(s)	Takezawa, Yutaka; Ohtake, Nobuaki; Nakano, Katsuya; Yamanaka, Hidetoshi
Citation	泌尿器科紀要 (1994), 40(8): 717-720
Issue Date	1994-08
URL	<a href="http://hdl.handle.net/2433/115326">http://hdl.handle.net/2433/115326</a>
Right	
Type	Departmental Bulletin Paper
Textversion	publisher

## LUPUS CYSTITIS: REPORT OF A CASE

Yutaka Takezawa and Nobuaki Ohtake

*From the Department of Urology, Tone Chuo Hospital*

Katsuya Nakano and Hidetoshi Yamanaka

*From the Department of Urology Gunma University School of Medicine*

A 42-year-old female with a history of systemic lupus erythematosus (SLE) visited the Department of Internal Medicine at our hospital complaining of anorexia. Hydronephrosis was diagnosed, and she was referred to our department for further evaluation. Intravenous pyelography (IVP) revealed bilateral hydronephrosis and hydroureters. Computerized tomography (CT) showed retention of ascitic fluid and thickening of the intestinal and bladder walls with contrast effects in the serosa and mucosa. Lasix-loaded renography showed that both kidneys were normal. Examination of a biopsy specimen revealed interstitial edema, fibrosis, and infiltration of inflammatory cells. Cystometry showed normal intravesical pressure. A diagnosis of lupus cystitis was made and administration of 40mg of prednisolone was started. The anemia was ameliorated, and thickening of the bladder and intestinal walls was no longer seen on CT. Hydronephrosis of the left kidney was less prominent. However, aggravation of the right ureteral stenosis was noted, and a stent was inserted in the stenosed ureter. Stenosis was successfully relieved by the stent, and internal drainage was established. The patient is still receiving steroids and is being followed at our department.

Twenty-two reported cases of lupus cystitis in Japan are reviewed.

(Acta Urol. Jpn. 40: 717-720, 1994)

**Key words:** Lupus cystitis, Hydronephrosis, Steroid therapy

### INTRODUCTION

SLE is well known for its pathological involvement of multiple organs and for its varying clinical symptoms<sup>1)</sup>. However, bladder disease is a rare complication of SLE. We describe a patient with SLE in whom interstitial cystitis with accompanying gastrointestinal symptoms and bilateral hydronephrosis developed. In addition the literature with regard to previously reported cases of lupus cystitis in Japan is reviewed.

### CASE REPORT

Patient: 42-year-old female

Chief complaint: Anorexia, evaluation of hydronephrosis

Medical history and family history: unremarkable

Present illness: A butterfly lesion first appeared in 1988. The patient visited a local physician, and a diagnosis of SLE was made. Treatment was begun, and the

patient responded well. She decided to discontinue treatment in April 1992 because her general condition had improved. In April 1993, she became anorexic, and she visited her physician again. CT demonstrated hydronephrosis, and the patient was referred to our department for further evaluation.

Physical examination on admission: There was no evidence of a butterfly lesion. The patient appeared thin. The abdomen was distended, and abdominal fluctuations were observed. Laboratory studies revealed anemia, leucocytopenia (red blood cell count  $312 \times 10^4/\text{mm}^3$ , hemoglobin 8.6 g/dl, hematocrit 26.6%, white blood cell count  $3,500/\text{mm}^3$ , platelet  $26 \times 10^4/\text{mm}^3$ ). The erythrocyte sedimentation rate (26 mm/hour) was slightly elevated. Urinalysis, blood urea nitrogen (14 mg/dl) and creatinine (0.49 mg/dl) were within normal limits. The titer of anti-nucleus antibody ( $\times 80$ ) was elevated.  $C_3$  (33 mg/dl)  $C_4$  (8 mg/dl) and CH50 (16.4 U) levels were decreased.

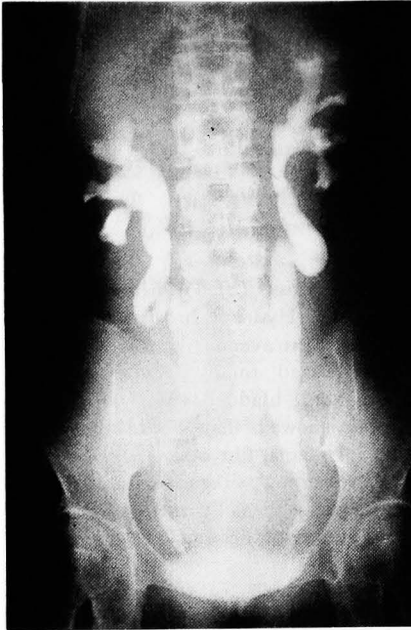

Fig. 1. IVP showed bilateral hydronephrosis and hydroureters

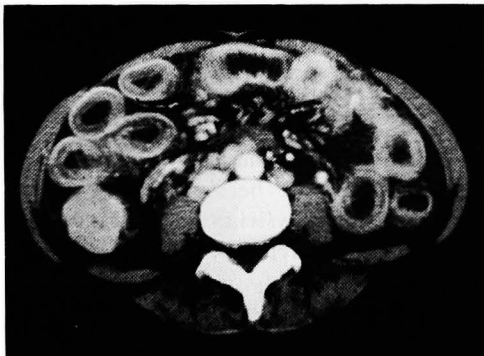


Fig. 2. Retention of ascitic fluid and thickening of the intestinal walls were visualized on CT. Contrast effects in the serosa and mucosa were also observed

Chest radiographs revealed retention of pleural fluid. IVP showed bilateral hydronephrosis and hydroureters (Fig. 1). No retroperitoneal tumor was visible by CT. Retention of ascitic fluid and thickening of the intestinal walls and urinary bladder were visualized on CT. Contrast effects in the serosa and mucosa were also observed (Fig. 2, 3). Examination of bladder tissue obtained from biopsy revealed interstitial edema, fibrosis, and infiltration of inflam-

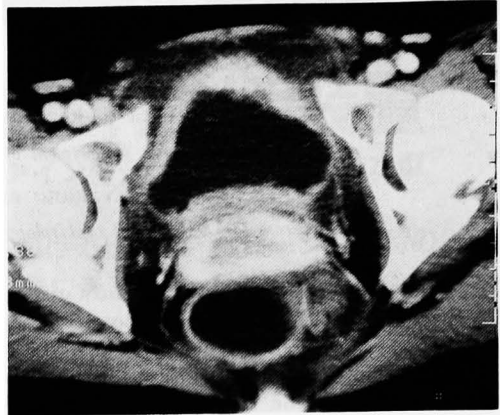


Fig. 3. Thickening of urinary bladder and contract effects in the serosa and mucosa were shown on CT

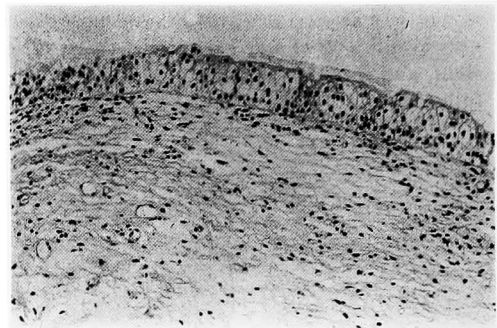


Fig. 4. Bladder tissue biopsy revealed interstitial edema, fibrosis, and infiltration of inflammatory cells

matory cells (Fig. 4). Lasix-loaded renography showed that both kidneys were normal. The intravesical pressure was measured. The first desire to void was experienced when the bladder was filled to a volume of 146 ml. The maximum desire to void was seen at 302 ml. The intravesical pressure (excretory pressure) at this point was 57 cm H<sub>2</sub>O which was almost within normal limits.

#### PATIENTS COURSE

Intravenous hyperalimentation using a central vein was started to improve the nutritional status. A diagnosis of lupus cystitis was made, and the patient was given 40 mg/day of prednisolone. Her appetite started to improve after 2 weeks of

steroid administration. Three weeks after the initiation of treatment, intravenous hyperalimentation was discontinued. CT findings of thickening of the intestinal and bladder walls became less prominent, as well as the anemia. Hydronephrosis of the left kidney was ameliorated, but that in the right kidney was aggravated. Retrograde pyelography demonstrated stenosis in the lower portion of the right ureter. A CT scan in the same region showed ureteral thickening, but there was no lesion causing extrinsic compression of the ureter. Ureteroscopic examination disclosed a submucosal protuberance. A biopsy specimen was obtained from the stenosed portion of the right ureter which revealed findings similar to those of the bladder biopsy (interstitial edema, fibrosis, and infiltration of inflammatory cells). Insertion of a ureteral stent effectively ameliorated the hydronephrosis on the affected side with establishment of internal drainage. Presently, the patient is receiving steroids and is being followed at our department.

### DISCUSSION

SLE is an automimmune disease characterized by the appearance of autoantibodies in the serum and multiple organ involvement. The most common manifestation of the disease in the urinary system is lupus nephritis<sup>1</sup>. Reports of bladder disease associated with SLE are rare. Orth et al.<sup>2</sup> reported the clinical characteristics of 6 cases of interstitial cystitis which complicated SLE. Iio et al.<sup>3</sup> described 19 Japanese patients with lupus cystitis, and in total, 22 such patients have been reported in Japan including the cases reported by Iju et al.<sup>4</sup>, Watanabe et al.<sup>5</sup>, and our own. SLE occurs more frequently in females<sup>1</sup>. Of the 21 patients reported so far, 19 were female. The age of onset ranged from 19 to 51 years. The mean age of the patients was 31 years.

Lupus cystitis is characterized by reduction of urinary bladder volume, hydronephrosis, and gastrointestinal as well as central nervous system (CNS) symptoms<sup>2</sup>. Gastrointestinal symptoms were seen in all

22 patients reported in Japan, but CNS symptoms were manifested in only 2 patients. The pathological features of lupus cystitis are interstitial edema, fibrosis, and infiltration of inflammatory cells<sup>2</sup>. Tissue deposition of immune complexes has also been reported<sup>6</sup>. Since similar pathological findings have been observed in the gastrointestinal system<sup>7</sup>, the production of a common autoantibody which reacts with both the bladder and the digestive tract is speculated to be the main pathogenetic mechanism in lupus cystitis.

Although bilateral hydronephrosis was observed in an IVP, lasix-loaded renography showed that both kidneys were normal. These findings suggest that the hydronephrosis in lupus cystitis is caused not only by stenosis in the ureterovesical junction but also by intrinsic dilatational changes in the pelves and ureters. There were no symptoms due to bladder irritability, and cystometry revealed almost normal findings. However, a CT scan showed thickening of the bladder wall, and pathological examination showed interstitial edema, fibrosis, and infiltration of inflammatory cells. Segovia et al.<sup>8</sup> found evidence of interstitial cystitis in 11 of 35 autopsies of SLE patients. It is probable that many cases of lupus cystitis remain undiagnosed, but are nevertheless present in SLE patients at a subclinical level.

Nineteen patients including ours received steroid therapy. Most patients were treated with an initial dose of 40 mg~60 mg of prednisolone. Three patients underwent pulse therapy. Nephrostomy was performed in 9 patients. Surgical creation of an ureterocutaneostomy and incision of the ureteral orifice were each performed in 1 patient. One patient was successfully treated by intravesical infusion of dimethyl sulfoxide alone which effectively ameliorated hydronephrosis<sup>3</sup>. Four patients were unresponsive to treatment, and 2 died of serious damage to the digestive tract. Surgical dilatation of the bladder using an intestinal patch and total cystectomy + ureterosigmoid anastomosis were each performed in 1 patient. Prognosis was generally more favorable in those patients in

whom steroids were given during the earlier stages of SLE<sup>8)</sup>.

CT scan clearly delineated the thickening of the bladder and intestinal walls in our patient. Our case was interesting in that on the one hand, the general condition, intestinal symptoms, thickness of bladder wall and intestinal wall and impairment due to the pyeloureteral lesion were ameliorated by steroid therapy, while on the other hand, stenosis of a portion of the right ureter progressed simultaneously. Since a biopsy specimen of the stenosed ureter revealed findings of chronic inflammation similar to those the bladder tissue, the patient is at present maintained on steroids and is being followed at our department.

#### REFERENCES

- 1) Steinberg AD: Systemic lupus erythematosus. In: Cecil Text book of medicine. Edited by Wyngaarden JB, Smith LH Jr. 17th ed., pp. 1924-1932, WB saunders, Philadelphia, 1985
- 2) Orth RW, Weisman MH, Cohen AH, et al.: Lupus Cystitis: Primary bladder manifestations of systemic lupus erythematosus. *Ann Intern Med* 98: 323-326, 1983
- 3) Iio S, Yokoyama M, Iwata E, et al.: Lupus cystitis which responded well to systemic steroid therapy: A case report. *Nishinon J Urol* 54: 355-360, 1992 (In Japanese)
- 4) Iju M, Ozawa H, Yasuda M, et al.: Successful treatment of lupus cystitis with dimethyl sulfoxide (DMSO). Report of a case and review of literature. *Kidney and Dialysis* 31: 150-154, 1991 (in Japanese)
- 5) Watanabe T, Kohjimoto Y, Inagaki T, et al.: Lupus cystitis associated with bilateral hydronephrosis: A case report. *Jpn J Urol Surg* 5: 527-530, 1992 (In Japanese)
- 6) Weisman HD, McDonald EC and Wilson CB: Studies of the pathogenesis of interstitial cystitis, obstructive uropathy and intestinal malabsorption in a patient with systemic lupus erythematosus. *Am J Med* 70: 875-881, 1981
- 7) Takabayashi K: Lupus cystitis. *Immunological Pharmacology* 4: 225-228, 1986. (In Japanese)
- 8) Rikiishi T, Kakizaki H, Kobayashi S, et al.: Lower urinary disturbance in patients with systemic lupus erythematosus. *Jpn J Urol Surg* 3: 955-960, 1990 (In Japanese)
- 9) Segovia DA, Mendosa AM, Gutierrez ER, et al.: Involvement of the urinary bladder in systemic lupus erythematosus. A pathologic study. *J Rheumatol* 11: 208-210, 1984  
(Received on December 25, 1993)  
(Accepted on March 22, 1994)

#### 和文抄録

### ループス膀胱炎の1例

利根中央病院泌尿器科

竹沢 豊, 大竹 伸明

群馬大学医学部泌尿器科学教室 (主任: 山中英寿教授)

中野 勝也, 山中 英寿

42歳, 女性. SLE で経過を観察中に食思不振となり当院内科を受診. 精査中に水腎症を発見され泌尿器科紹介となった. IVP で両側水腎尿管を認めた. CT では腹水貯留と粘膜と漿膜に造影効果を有する腸管壁および膀胱壁の肥厚を認めた. ラジックス負荷レントグラムは両側腎とも正常であった. 膀胱生検では間質の浮腫, 繊維化と炎症細胞浸潤を認めた. 膀胱内圧

測定ではほぼ正常であった. ループス膀胱炎の診断でプレドニソロン 40 mg を開始した. CT 上, 膀胱壁, 腸管壁の肥厚も消失し貧血も改善した. 左水腎症は改善したが右尿管狭窄が悪化したため尿管ステントを挿入しステロイド療法を継続しながら経過を観察している.

(泌尿紀要 40: 717-720, 1994)