

Title	Acute pulmonary embolism after conservative surgery for renal cyst: a case report
Author(s)	Satake, Ichiro; Nakagomi, Kazuaki; Tari, Kiyonobu
Citation	泌尿器科紀要 (1994), 40(6): 525-528
Issue Date	1994-06
URL	<a href="http://hdl.handle.net/2433/115285">http://hdl.handle.net/2433/115285</a>
Right	
Type	Departmental Bulletin Paper
Textversion	publisher

## ACUTE PULMONARY EMBOLISM AFTER CONSERVATIVE SURGERY FOR RENAL CYST: A CASE REPORT

Ichiro Satake, Kazuaki Nakagomi and Kiyonobu Tari

*From Urology Clinic, Saitama Cancer Center*

A case of acute pulmonary embolism which developed one week after conservative surgery of the renal cyst is reported. He was 41 year old and had a long habit of cigarette smoking. He underwent wedge resection of the renal mass which was proved to be a multilocular renal cyst pathologically. The acute pulmonary embolism which developed on the seventh postoperative day was confirmed by lung scintigraphy. The patient recovered from the disease by thrombolytic therapy. Postoperative bed rest seemed to be closely associated with the incidence in this case. Early ambulation is recommended. In addition, the thromboprophylactic therapy may be justified in patients undergoing kidney-sparing surgery which requires postoperative bed rest.

(Acta Urol. Jpn. 40: 525-528, 1994)

**Key words:** Renal surgery, Postoperative pulmonary embolism

### INTRODUCTION

Since the introduction of modern imaging techniques, particularly that of ultrasonography, the number of renal tumors found in asymptomatic patients has been increasing. Kidney-sparing surgery may be the logical choice for small tumors<sup>1)</sup>, which are more often found in asymptomatic cases than in those with clinical symptoms. Under these circumstances, conservative surgery such as partial nephrectomy and enucleation of the tumor will have a certain place in urological surgery. We herein report a case of pulmonary embolism which developed on the seventh postoperative day (POD) after wedge resection of the suspected renal tumor.

### CASE REPORT

A 41-year-old man was suspected to have a small renal mass on his regular health-checkup in July 1993 and was referred to us in September 1993. He was slightly obese but was free from clinical symptoms and did not have a previous history of cardiovascular disease. He smoked twenty cigarettes a day for twenty years. On admission, he was 168 cm in height and wei-

ghed 75 kg. His blood pressure was 132/88 and electrocardiogram was normal. Regular blood counts and chemistries were normal except for slight elevation of triglycerides, 161 mg/dl (normal range: 40~125 mg/dl). Bleeding time, activated partial thrombin time and prothrombin time were all normal. Computerized tomography of the abdomen revealed a right renal mass, 19 mm in diameter, which had heterogeneous contents (Fig. 1). Angiographic and magnetic resonance imaging studies of the kidney were done, which demonstrated that the renal mass was avascular with a normal adjacent structure. He was fully informed of these results and requested surgical management of the suspected renal mass.

In November 1993, he underwent wedge resection of the renal mass by lumbotomy under general anesthesia. The renal vessels were clamped for fifteen minutes. The operative time was eighty-five minutes and blood loss was 320 gr. No blood transfusion was done. Epidural catheterization was done just before induction of anesthesia and morphine was infused continuously until the third POD through the catheter. Central venous catheter was not inserted. Pathological diagnosis of the resected spec-

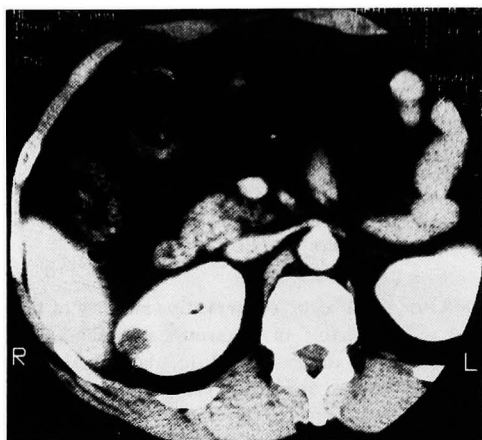


Fig. 1. CT scan of the abdomen revealed a right renal mass, 19mm in diameter, with heterogeneous contents.

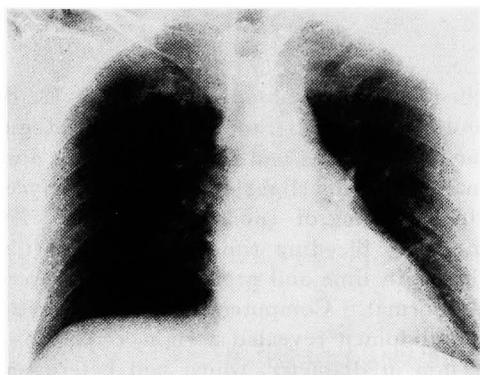


Fig. 2. Chest X-P taken after thromboembolic episode. Slight translucency of right lung was noted.

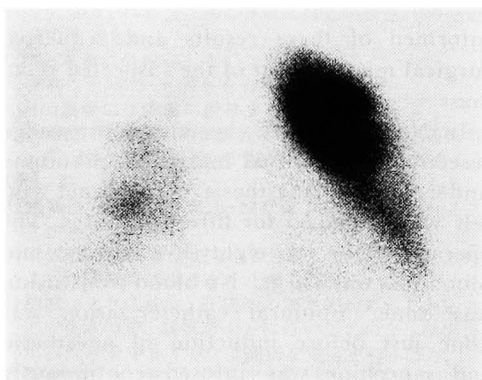


Fig. 3. Lung scintigram using  $^{99m}\text{Tc}$  demonstrated lack of perfusion in whole right and lower left lungs.

imen was that of multilocular renal cysts.

Bed rest was advised for him to avoid secondary postoperative hemorrhage and the convalescence was uneventful until the seventh POD, when he was permitted to stand up and walk. He complained of palpitation and dyspnea after several minutes of walking. The heart rate was 120 beats per minute and blood pressure was 110/60. Arterial blood gas analyses under an oxygen flow of 6 liters per minute revealed; pH 7.392,  $\text{Paco}_2$  43.6 mmHg and  $\text{Pao}_2$  67.6 mmHg. Slight hyperlucency of right lung was noted on chest X-P but was interpreted as a non-specific finding (Fig. 2). Although he was relaxed and felt well following bed rest and oxygen inhalation, tachycardia persisted. Lung scintigram using  $^{99m}\text{Tc}$  aggregated albumin on the next day (eighth POD) revealed perfusion defects in right lung and lower left lung. Only left upper lung was functioning (Fig. 3). Immediately, heparin and urokinase therapy was constituted at a dose of 24,000 units/day and 480,000 units/day, respectively, on the diagnosis of acute pulmonary embolism. Since the arterial blood gas analysis revealed persistent hypoxemia, he was referred to a coronary care unit of another hospital to undergo further treatment including surgery. He recovered from the disease by thrombolytic therapy alone and was discharged from the hospital four weeks later.

#### DISCUSSION

Postoperative pulmonary embolism usually occurs within two weeks of surgery<sup>2)</sup>. Deep venous thrombosis and pulmonary embolism affect up to 66% of the patients undergoing major urological operations<sup>3)</sup>. Although the incidence of postoperative deep venous thrombosis and of postoperative major pulmonary embolism demonstrated by autopsy have been decreasing during the last decade, pulmonary embolism remains to be a major cause of death in surgical patients<sup>4,5)</sup>. According to a recent report from Japan, a pulmonary embolism was noted in 15.4% and the acute fatal pulmonary embolism was the cause of death in 6.0% of 500 serial autopsy cases<sup>6)</sup>.

These rates are higher than have been reported in Japan, and almost parallel those in the United States and Western Europe. We should be aware of the frequent incidence of this disorder.

Cigarette smoking, obesity, prolonged bed rest and general anesthesia as seen in this patient were, among others, risk factors for deep venous thrombosis which subsequently develops to acute pulmonary embolism<sup>4)</sup>. Of these, prolonged bed rest was particularly associated with the acute pulmonary embolism in this case, since the disease abruptly occurred when he left his bed to walk after being bed ridden for one week postoperatively. The necessity of postoperative bed rest, which may vary with the individual patient, is largely empirical. Postoperative bed rest should be shortened and early ambulation is recommended.

The most common symptoms of acute pulmonary embolism are tachypnea and tachycardia of sudden onset. Arterial blood gas analysis may reveal decreased  $P_{aO_2}$  and  $P_{aCO_2}$ . Hyperlucency of the involved lung field, prominence of proximal pulmonary artery and cardiomegaly may be noted in the chest X-P. The electrocardiogram may show ST-T changes<sup>7)</sup>. Scintillation scanning of the lung seems to be particularly useful for the correct diagnosis as in this case.

Thrombolytic therapy using urokinase via a catheter in the pulmonary artery with co-administration of heparin has been advocated for postoperative pulmonary embolism<sup>2)</sup>. Some investigators have recommended embolectomy if a large embolus is detected<sup>7)</sup>. Patients undergoing conservative renal surgery are sometimes required to have bed rest for two days or more, which imposes on them a considerable risk for the deep vein thrombosis and subsequent pulmonary embolism. Therefore, postoperative thromboprophylaxis, such as

heparin and compression stockings<sup>3)</sup>, may be justified for these patients. We always administer low-dose heparin in those with central venous catheter<sup>8)</sup>, another risk factor for thromboembolism<sup>4)</sup>. Unfortunately, this patient, for whom central venous catheter was not necessary, did not receive thromboprophylactic therapy by heparin.

#### REFERENCES

- 1) Steinbach F, Stöckle M, Müller SC, et al.: Conservative surgery of renal cell tumors in 140 patients: 21 years of experience. *J Urol* **148**: 24-30, 1992
- 2) Molina JE, Hunter DW, Yedlicka JW, et al.: Thrombolytic therapy for postoperative pulmonary embolism. *Am J Surg* **163**: 375-380, 1992
- 3) Hansberry KL, Thompson IM Jr, Bauman J, et al.: A prospective comparison of thromboembolic stockings, external sequential pneumatic compression stockings and heparin sodium/dihydroergotamine mesylate for the prevention of thromboembolic complications in urologic surgery. *J Urol* **145**: 1205-1208, 1991
- 4) Persson AV, Davis RJ and Villavicencio JL: Deep venous thrombosis and pulmonary embolism. *Surg Clin North Am* **71**: 1195-1209, 1991
- 5) Lindblad B, Eriksson A and Bergqvist D: Autopsy-verified pulmonary embolism in a surgical department: analysis of the period from 1951 to 1988. *Br J Surg* **78**: 849-852, 1991
- 6) Ito M: Pathology of pulmonary embolism. *Kokyu To Junkan* **89**: 567-572, 1991
- 7) Maeta H, Imawaki S, Shiraiishi Y, et al.: Clinical profile and treatment of acute pulmonary embolism. *Kokyu To Junkan* **40**: 261-266, 1992
- 8) Tari K, Satake I and Takeuchi S: Treatment of acute renal failure by intravenous hyperalimentation with heparin. *Jpn J Clin Urol* **38**: 45-49, 1984

(Received on December 20, 1993)  
(Accepted on January 25, 1994)

## 和文抄録

## 腎嚢胞に対する腎保存術後にみられた急性肺塞栓症の1例

埼玉県立がんセンター泌尿器科（部長：田利清信）

佐竹 一郎，中込 一彰，田利 清信

腎嚢胞に対する腎保存手術から1週間後にみられた急性肺塞栓症の1例を報告した。本症例は41歳男性で、長年にわたる喫煙歴を有する。腎の病変に対しては楔状切除を施行したが、病理診断は多房性嚢胞であった。肺塞栓症は術後7日目に出現し、肺シンチグラフィで確認された。本症例は血栓溶解療法にて軽快

した。本症例における肺塞栓症は術後の安静に関係したものと考えられた。術後早期の離床が必要と思われた。また、術後安静を要する腎保存症例においては、血栓症の予防を考慮すべきと思われた。

（泌尿紀要 40：525-528, 1994）