

Title	Leiomyosarcoma of the spermatic cord: a case report
Author(s)	Kawanishi, Hiroaki; Yoshida, Toru; Kouhei, Naoki; Sasaki, Miharu; Itoh, Tadahiro; Yamamoto, Masashi
Citation	泌尿器科紀要 (2003), 49(9): 551-554
Issue Date	2003-09
URL	http://hdl.handle.net/2433/115039
Right	
Type	Departmental Bulletin Paper
Textversion	publisher

LEIOMYOSARCOMA OF THE SPERMATIC CORD: A CASE REPORT

Hiroaki KAWANISHI, Toru YOSHIDA, Naoki KOUHEI and Miharu SASAKI
From the Department of Urology, Shizuoka City Hospital

Tadahiro ITOH
From the Department of Pathology, Shizuoka City Hospital

Masashi YAMAMOTO
From the Department of Radiology, Shizuoka City Hospital

A 61-year-old man presented to our hospital with a 1.5-year history of a gradually enlarging mass in the left scrotum. The mass was apart from the testis and fixed to the spermatic cord. The firm consistency and heterogeneous expression on ultrasonography suggested a malignant tumor. Orchiectomy with high ligation of the spermatic cord was performed and a histological examination revealed leiomyosarcoma of the spermatic cord. Distant metastases were not observed. Because the incidence of local recurrence has been reported to be high, we performed irradiation to control the disease. At 32 months post-surgery he was alive with no evidence of disease.

(Acta Urol. Jpn. 49 : 551–554, 2003)

Key words : Spermatic cord, Leiomyosarcoma, Radiotherapy

INTRODUCTION

Sarcomas of the spermatic cord are rare. We report a case of leiomyosarcoma of the spermatic cord, which was treated by orchiectomy with high ligation of the spermatic cord (radical orchiectomy) and local adjuvant radiotherapy. Since the reports on leiomyosarcomas of the spermatic cord were mostly of a small series or single cases it has been difficult to collect a sufficient number of cases to document the nature and draw any firm conclusions regarding treatment. We briefly discuss about the management of leiomyosarcoma of the spermatic cord.

CASE REPORT

A 61-year-old man was admitted to our hospital with a 1.5-year history of a gradually enlarging mass in the left scrotum. Physical examination revealed a well-defined, smooth, firm, nontender mass of 5 by 5 cm in the left scrotum. The mass was apart from the testis and fixed to the spermatic cord. The results of laboratory examinations were normal. Ultrasonography showed a heterogeneous mass with a hyperechoic lesion in the center. The firm consistency and heterogeneous expression on ultrasonography suggested a malignant tumor. Pelvic and abdominal computed tomography revealed no metastases.

Left radical orchiectomy was performed. Macroscopically, the testis and epididymis appeared to be normal and the surgical stump of the spermatic cord was free from disease. A well-circumscribed tumor, measuring 6.0 by 5.5 by 4.0 cm, was found in the spermatic cord. The cut surface was white with

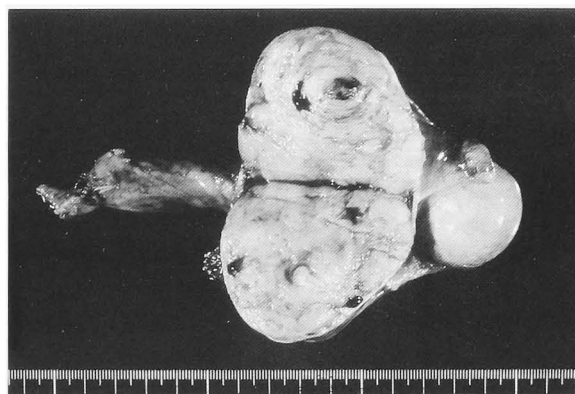


Fig. 1. The extirpated specimen. A well-circumscribed tumor with a white cut-surface, measuring 6.0 by 5.0 by 4.0 cm, was found in the spermatic cord.

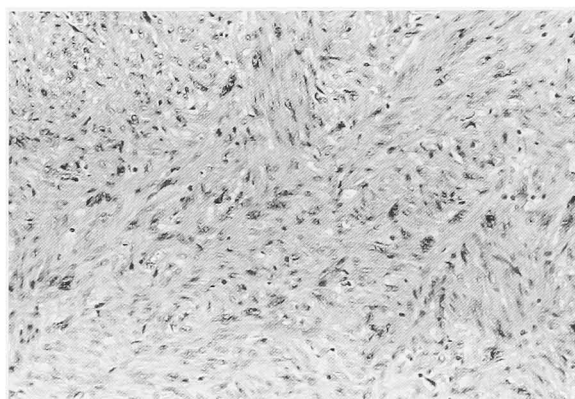


Fig. 2. Microscopic appearance of the tumor. The tumor had elongated cells with central nuclei, arranged in fascicles (original magnification $\times 200$; H & E).

hemorrhage in the center (Fig. 1). Microscopically, elongated cells with central nuclei, arranged in fascicles, were observed (Fig. 2). The tumor showed no necrotic change, had a 1.4 mitoses/10 high-power field (HPF), and had occasional pleomorphic nuclei. There was a strongly positive immunostaining for smooth muscle actin and desmin on the paraffin sections. The tumor was diagnosed as leiomyosarcoma of the spermatic cord. The tumor grade according to the National Cancer Institute (NCI) system¹⁾ was grade 1.

Because the incidence of local recurrence is known to be high, we gave the patient local adjuvant radiotherapy with a dose of 5,040 cGy in 28 fractions, using 6 MV X-ray beam with bolus to the ipsilateral iliac and inguinal lymph nodes, the spermatic cord bed and the hemiscrotum. Although the patient has been suffering from moderate lymphedema in the left thigh induced by radiotherapy, he had no evidence of disease at 32 months post-surgery.

DISCUSSION

Neoplasms arising in the spermatic cord are uncommon, and most differentiate from the mesenchyma. If one excludes lipomas, most neoplasms are sarcomas. Sarcomas occur mostly in the scrotal part of the spermatic cord while benign tumors are nearly always located in the inguinal lesion²⁾. Firm consistency and multilobulation are also indicators favoring sarcoma. Sarcomas of the spermatic cord should be removed by radical orchiectomy because the incidence of local recurrence following simple excision is very high. The role of frozen section is not established as the differential diagnosis between benign and malignant lesions may be difficult. In our case, as the tumor was strongly suspected to be sarcoma, radical orchiectomy was performed without frozen section analysis.

Leiomyosarcomas of the spermatic cord are rare and, to our knowledge, 23 cases have been reported in Japan³⁾. Because of the low incidence, the natural course has been unsettled. Fisher et al. reported the largest series of leiomyosarcomas of the spermatic cord: 14 cases with clinical follow-up information⁴⁾. The median follow-up was 53 months (range: 3–124 months). All ten patients with grades 1 and 2 tumors were alive with no evidence of disease at a mean of 46.5 months, but all four patients with grade 3 tumors died of disease at a mean of 71 months. They claim that histological grading provides useful prognostic information.

Although all investigators agree that radical orchiectomy is an essential component in the management for sarcomas including leiomyosarcoma, the role of adjuvant therapy remains controversial. Concerning the dissemination, the following three patterns have often been pointed out:

1) local recurrence in the scrotum, inguinal canal or pelvis along the path of the vas deferens, 2) spread to pelvic and para-aortic lymph nodes, and 3) distant hematogenous metastasis, usually to the lung⁵⁾.

Local recurrence is the most common pattern of failure. In the report by Ballo et al., the actuarial local recurrence rate after surgery alone was 30% at 10 years and 42% at 15 years⁶⁾. Several reports suggest that adjuvant radiotherapy may reduce the incidence of local recurrence^{6–8)}. Ballo et al. claim that sarcoma of the spermatic cord, regardless of its grade and size, has a high propensity for local recurrence after surgery alone and should be managed with surgery and adjuvant radiotherapy⁶⁾. In the randomized prospective trial on extremity soft tissue sarcoma, adjuvant radiotherapy was shown to result in a statistically significant reduction in local recurrence in patients with either high-grade or low-grade tumor⁹⁾. Therefore, we gave our patient adjuvant radiotherapy although the pathological grade was low.

There has been controversy with respect to prophylactic treatment for lymph nodes metastases. Recent reports showed a low incidence of lymph node metastasis^{6,8)}. The true incidence of para-aortic and pelvic nodal metastasis has not been reported, and the benefits of prophylactic nodal treatment remain unclear. Systemic chemotherapy may have a role in eliminating the hematogenous metastatic potential in high-grade tumors. However, so far this modality has not been defined as adjuvant therapy for soft tissue sarcoma except for pediatric embryonal rhabdomyosarcoma⁸⁾.

In conclusion, adjuvant radiotherapy seems to be highly effective in preventing local recurrence for leiomyosarcoma of the spermatic cord. The role of prophylactic nodal treatment and systemic chemotherapy has yet to be defined.

REFERENCES

- 1) Costa J, Wesley RA, Glatstein E, et al.: The grading of soft tissue sarcomas: results of a clinicohistopathologic correlation in a series of 163 cases. *Cancer* **53**: 530–541, 1984
- 2) Puts JJ, Boerema JB and van Haelst UJ: Leiomyosarcoma of spermatic cord. *Urology* **23**: 187–193, 1984
- 3) Yoshii T, Ashizawa Y, Hariu K, et al.: A case of leiomyosarcoma of the spermatic cord. *Acta Urol Jpn* **48**: 225–227, 2002
- 4) Fisher C, Goldblum JR, Epstein JI, et al.: Leiomyosarcoma of the paratesticular region: a clinicopathologic study. *Am J Surg Pathol* **25**: 1143–1149, 2001
- 5) Blitzer PH, Dosoretz DE, Proppe KH, et al.: Treatment of malignant tumors of the spermatic cord: a study of 10 cases and a review of the

- literature. *J Urol* **126**: 611–614, 1981
- 6) Ballo MT, Zagars GK, Pisters PW, et al.: Spermatic cord sarcoma: outcome, patterns of failure and management. *J Urol* **166**: 1306–1310, 2001
- 7) Fagundes MA, Zietman AL, Althausen AF, et al.: The management of spermatic cord sarcoma. *Cancer* **77**: 1873–1876, 1996
- 8) Catton CN, Cummings BJ, Fornasier V, et al.: Adult paratesticular sarcomas: a review of 21 cases. *J Urol* **146**: 342–345, 1991
- 9) Yang JC, Chang AE, Baker AR, et al.: Randomized prospective study of the benefit of adjuvant radiation therapy in the treatment of soft tissue sarcomas of the extremity. *J Clin Oncol* **16**: 197–203, 1998

(Received on February 5, 2003)
(Accepted on June 14, 2003)

和文抄録

精索平滑筋肉腫の1例

静岡市立静岡病院泌尿器科（科長：佐々木美晴）

川西 博晃，吉田 徹*，公平 直樹，佐々木美晴

静岡市立静岡病院病理科（科長：伊藤忠弘）

伊藤 忠 弘

静岡市立静岡病院放射線科（医長：山本真志）

山 本 真 志

症例は61歳，男性．1年半前より左陰嚢内に腫瘤を自覚，次第に増大してきたため当科を受診した．触診上，腫瘤は精巣と離れており，精索に付着していた．弾性硬であること，超音波検査上内部エコーが不均一なことより悪性が疑われ，高位精巣切除を施行した．病理組織学的検査結果は精索原発の平滑筋肉腫であっ

た．画像的に遠隔移転はみとめなかった．局所再発率が高いことが報告されているため，術後に放射線療法を行った．術後32カ月を経過した現在，再発は認めていない．

(泌尿紀要 49 : 551-554, 2003)

* 現：京都大学医学部泌尿器科