

Title	Solitary fibrous tumor in the retroperitoneum: a case with infiltrative growth
Author(s)	Nakatani, Tatsuya; Tamada, Satoshi; Iwai, Yoshihito; Tanimoto, Yoshiaki
Citation	泌尿器科紀要 (2002), 48(10): 637-641
Issue Date	2002-10
URL	<a href="http://hdl.handle.net/2433/114835">http://hdl.handle.net/2433/114835</a>
Right	
Type	Departmental Bulletin Paper
Textversion	publisher

## SOLITARY FIBROUS TUMOR IN THE RETROPERITONEUM: A CASE WITH INFILTRATIVE GROWTH

Tatsuya NAKATANI and Satoshi TAMADA

*From the Department of Urology, Osaka City University Graduate School of Medicine*

Yoshihito IWAI and Yoshiaki TANIMOTO

*From the Department of Urology, Isuzu City Hospital*

Solitary fibrous retroperitoneal tumor is rare. We present a case with infiltrative growth in a 56-year-old female patient whose initial symptom was palpable tumor in the lower abdomen. Computed tomography and magnetic resonance imaging indicated a mass in the retroperitoneum under the left kidney with a poorly demarcated infiltrative growth. Surgical findings revealed a gelatinous tumor in the retroperitoneum, which had invaded up to the fatty tissue surrounding the Gerota's fascia and to the fatty tissue surrounding the descending colon. However, as there was no invasion into the Gerota's fascia, it was possible to preserve the left kidney. Pathohistological examination revealed increased cellularity in the tumor tissues as well as tissues with atypical nuclei of the tumor cells with some cell division. Due to these findings, it was diagnosed as malignant solitary fibrous tumor. Only surgical treatment was performed and the patient is alive without recurrence 2 years and 4 months after surgery.

(Acta Urol. Jpn. 48 : 637-641, 2002)

**Key words:** Solitary fibrous tumor, Retroperitoneum, Malignant tumor, Infiltrative growth

### INTRODUCTION

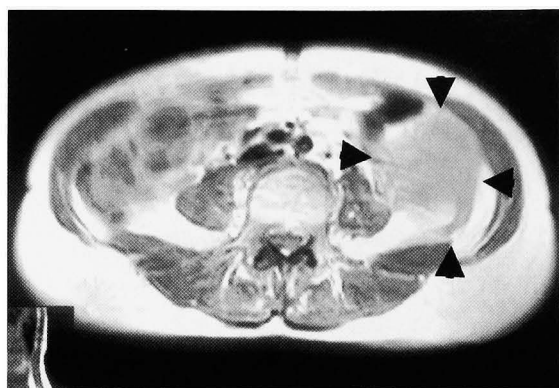
Solitary fibrous tumor (SFT) was first reported in 1931 as a primary neoplasm of the pleura<sup>1)</sup> It is a rare spindle cell tumor that occurs in adults and is known as a benign tumor of the pleura, often described as encapsulated or sharply circumscribed. It rarely occurs in the retroperitoneum, and only 24 cases have been reported in the English-language literature<sup>2-13)</sup>. Among them, only 2 cases were malignant SFT, and our case is the first case of retroperitoneal SFT with infiltrative growth in the surrounding tissues.

### CASE REPORT

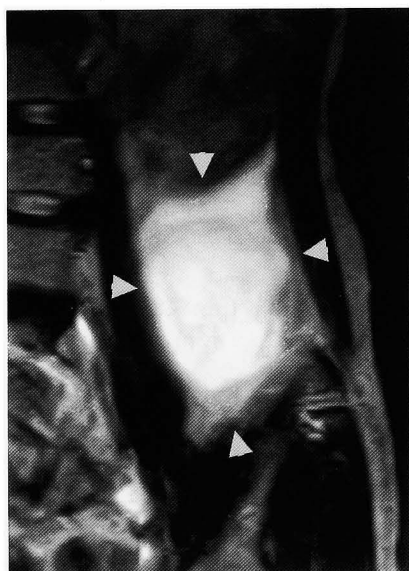
The patient was a 56-year-old female who noticed a mass in the left lower abdomen and visited our hospital. On physical examination, a hard mobile mass was palpable in the left lower abdomen. Values of carcinoembryonic antigen, carbohydrate antigen 19-9 and cancer antigen 125 were normal. Excretory urography indicated no abnormality in the urinary tract. Barium enema revealed a compression figure in the descending colon. Abdominal ultrasonography demonstrated a somewhat poorly demarcated tumor with heterogenous internal echo. Computed tomography (CT) revealed a slightly heterogenous 9×6×6 cm tumor in the retroperitoneum under the left kidney. Enhanced CT showed a tumor with some deep staining. Magnetic resonance imaging (MRI) T1-weighted image were

low intensity similar to the muscles (Fig. 1a), but T2-weighted images were high intensity and internally partly heterogenous (Fig. 1b). The tumor was poorly demarcated with a beak-like component extending posteriorly, closely bordering the intestines and expanding up along the Gerota's fascia. CT as well as MRI revealed no lymph node metastasis around the aorta or hepatic metastasis. Angiography showed an internally hypovascular tumor with an indistinct outline, but no feeding vessels. Malignant teratoma or sarcoma occurring in the retroperitoneum was suspected, and laparotomy was performed. On laparotomy, a partly encapsulated tumor was observed and in the retroperitoneum, a poorly demarcated gelatinous substance had spread diffusively up to the fatty tissue surrounding the Gerota's fascia and the fatty tissue surrounding the descending colon. The tumor was removed along with the fatty tissue in the retroperitoneum containing the gelatinous substance, and part of the descending colon, and the lower half of the Gerota's fascia were excised as well.

In the removed specimen, the encapsulated part of the tumor was filled with a gelatinous substance, but there were no necrotic tissues. Pathohistological examination revealed weakly amplified images with varied cellular intensity, remarkable collagen fiber hyperplasia in the interstitium and some hyalinization. Invasion into the surrounding fatty tissues was also observed (Fig. 2a), and abundant beak-like hemangiopericytoma blood vessels were



a



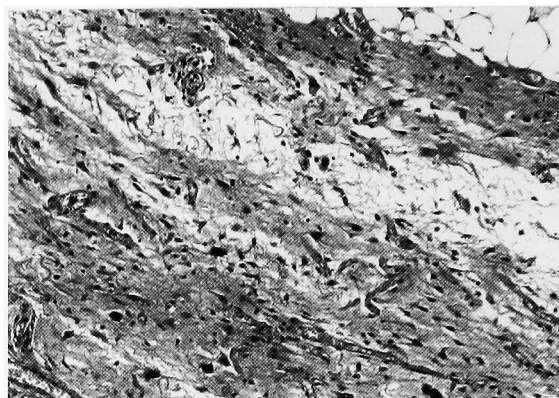
b

Fig. 1. Abdominal MRI. (a) T1-weighted transverse image reveals a tumor (black arrow heads) with a beak-like component extending posteriorly into the fatty tissue and closely bordering the intestines; (b) T2-weighted coronal oblique image shows the high intensity tumor extending up along the Gerota's fascia.

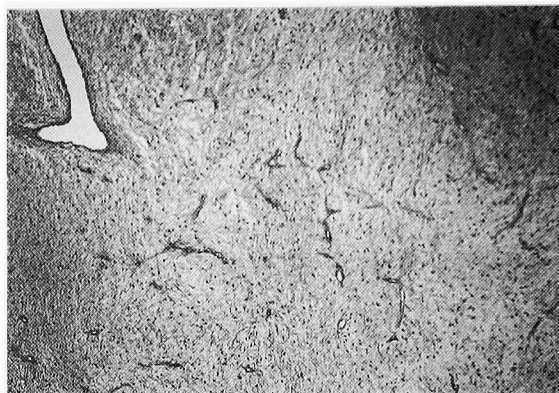observed (Fig. 2b). There were both tissues with weak and strong nuclear atypia, and strongly magnified images of the tissue with strong nuclear atypia revealed cells with spindle shaped nuclei and nuclear atypia with some cell division (1 mitoses/10 HPFs) (Fig. 2c). Immunohistological staining indicated the presence of vimentin and CD34 and absence of S-100, actin and CD68. Accordingly, a diagnosis of retroperitoneal malignant SFT was made. No further treatment was performed, and the patient is alive without recurrence 2 years 4 months after surgery.

#### DISCUSSION

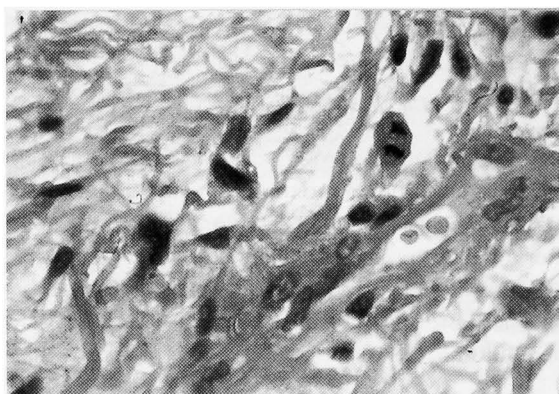
SFT originating in the pleura has been well documented<sup>14)</sup>, and cases of extrapleural SFT have



a



b



c

Fig. 2. Histological findings. (a) Invasion into the surrounding fatty tissue can be observed; (b) Beak-like hemangiopericytoma blood vessels are observed; (c) Nuclear atypia is seen.

also been reported. When the 25 reported cases of retroperitoneal SFT including our present case (Table 1) were examined, there were 11 male and 13 female patients aged 17 to 82 (mean 49.0), with tumor sizes from 2 to 26 cm (mean 10.6 cm). The symptoms in 8 cases were incidental, followed by pain and hypoglycemia in 3 cases. Histologically, 21 were benign and 3 were malignant. Excluding our case, all others were well circumscribed or encapsulated, and ours was the first case of retroperitoneal SFT with infiltrative growth. Surgical excision was performed

Table 1. Cases of retroperitoneal solitary fibrous tumor

Author	Year	Age	Sex	Size (cm)	Symptom	Histology	Margin	Treatment	Outcome
Nevius	1959	48	M	ND	hypoglycemia	ND	ND	ND	ND
Echenique	1988	58	M	14	voiding difficulty	benign	completely encapsulated	SE+radiation	NED
Young	1990	59	F	9	incidental	benign	well-circumscribed	SE	NED
Goodlad	1991	66	M	7	frequency, nocturia	benign	well-circumscribed	SE	NED
		17	F	26	abdominal discomfort	benign	well-circumscribed	SE	NED
Piazza	1996	51	F	7	incidental	benign	well-circumscribed	SE	NED
Fukunaga	1997	33	F	3.5	ND	benign	well-circumscribed	SE	NED
		36	F	2	ND	benign	well-circumscribed	SE	NED
Nielsen	1997	ND	ND	ND	ND	malignant	well-circumscribed	SE	NED
Decouvelaere	1998	40	M	17	ND	benign	well-circumscribed	SE	lung metastasis
		63	F	4.5	ND	benign	well-circumscribed	SE	NED
		70	F	10	painless mass	benign	well-circumscribed	SE	NED
Yokoi	1998	38	M	ND	hypoglycemia	malignant	well-circumscribed	SE	local recurrence
Hasegawa	1999	48	F	5	incidental	benign	well-circumscribed	SE	NED
		38	M	12	lower abdominal pain	benign	well-circumscribed	SE	NED
		76	M	7	incidental	benign	well-circumscribed	SE	NED
		47	M	12	lower abdominal pain	benign	well-circumscribed	SE	NED
		69	M	15	hypoglycemia	benign	well-circumscribed	SE	NED
		37	F	8	incidental	benign	well-circumscribed	SE	NED
		33	F	6	incidental	benign	well-circumscribed	SE	NED
30	F	17	incidental	benign	well-circumscribed	SE	NED		
Morimatsu	2000	82	M	23	ND	benign	well-circumscribed	SE	NED
Clayton	2001	65	M	5	incidental	benign	ND	biopsy	no change
		17	F	15	hip pain	benign	ND	SE+radiation	NED
Present case		56	F	9	abdominal mass	malignant	infiltrative	SE	NED

ND: not described, SE: surgical excision, NED: alive with no evidence of disease.

in 21 cases, and surgical excision and radiation in 2 cases. As for the prognosis, 20 cases had no evidence of disease, 2 cases were alive with disease and 1 case had lung metastasis. These results were compared with those of 223 cases of pleural-based SFT reported by England et al.<sup>14)</sup> Although the age was 8 years younger for retroperitoneal SFT, sex, tumor size and symptoms were similar. The ratio of malignant SFT was 37% for pleural-based SFT, while it was 12.5% for retroperitoneal SFT. As for prognosis, recurrence was observed in 23% and metastasis in 9.8% for pleural-based SFT, while both recurrence and metastasis were 4.2% for retroperitoneal SFT. These results suggest that retroperitoneal SFT may be histologically and clinically more benign compared to pleural-based SFT.

Histological malignancy is unlike biological malignancy, and there have been reports of metastasis even in benign SFT<sup>10)</sup>. Even if it were malignant, complete excision of the tumor is thought to have a favorable prognosis, and resectability is the most important indicator of clinical outcome. In our case, a poorly demarcated gelatinous substance had spread invasively into the surrounding tissues, making it difficult to decide the extent of excision.

Solitary fibrous tumor of the retroperitoneum is rare, and in particular, no reports have been published on retroperitoneal solitary fibrous tumors with infiltrative growth. In our case, although the tumor was histologically malignant and infiltrative, the outcome of surgical treatment without further treatment was good. The patient is without recurrence at 2 years 4 months after surgery. However, due to reported cases of recurrence after surgical excision, this case is being carefully followed on a long-term basis.

#### REFERENCES

- 1) Klemperer P and Rabin CB: Primary neoplasm of the pleura: a report of five cases. *Arch Pathol Lab Med* **11**: 385-412, 1931
- 2) Nevius DB and Friedman NB: Mesotheliomas and extralovarian thecomas with hypoglycemic and nephrotic syndromes. *Cancer* **12**: 1263-1269, 1959
- 3) Echenique J and Graham SD Jr: Pelvic fibrous mesothelioma with obstructive symptoms. *Urology* **31**: 142-146, 1988
- 4) Young RH, Clement PB and McCaughey WT: Solitary fibrous tumors ('fibrous mesotheliomas') of the peritoneum. a report of three cases and a

- review of the literature. Arch Pathol Lab Med **114**: 493-495, 1990
- 5) Goodlad JR and Fletcher CD: Solitary fibrous tumor arising at unusual sites: analysis of a series. Histopathology **19**: 515-522, 1991
  - 6) Piazza R, Blandamura S, Zattoni F, et al.: Solitary fibrous tumor of the retroperitoneum mimicking a renal mass. Int Urol Nephrol **28**: 751-754, 1996
  - 7) Fukunaga M, Naganuma H, Nikaïdo T, et al.: Extrapleural solitary fibrous tumor: a report of seven cases. Mod Pathol **10**: 443-450, 1997
  - 8) Nielsen GP, O'Connell JX, Dickersin GR, et al.: Solitary fibrous tumor of soft tissue: a report of 15 cases, including 5 malignant examples with light microscopic immunohistochemical, and ultra-structural data. Mod Pathol **10**: 1028-1037, 1997
  - 9) Vallat-Decouvelaere AV, Dry SM and Fletcher CD: Atypical and malignant solitary fibrous tumors in extrathoracic locations: evidence of their comparability to intra-thoracic tumors. Am J Surg Pathol **22**: 1501-1511, 1998
  - 10) Yokoi T, Tsuzuki T, Yatabe Y, et al.: Solitary fibrous tumor. significance of p53 and CD34 immunoreactivity in its malignant transformation. Histopathology **32**: 423-432, 1998
  - 11) Hasegawa T, Matsuno Y, Shimoda T, et al.: Frequent expression of bcl-2 protein in solitary fibrous tumors. Jpn J Clin Oncol **28**: 86-91, 1998
  - 12) Morimitsu Y, Nakajima M, Hisaoka M, et al.: Extrapleural solitary fibrous tumor: clinicopathologic study of 17 cases and molecular analysis of the p53 pathway. APMIS **108**: 617-625, 2000
  - 13) Clayson AC, Salomao DR, Keeney GL, et al.: Solitary fibrous tumor: a study of cytologic features of six cases diagnosed by fine-needle aspiration. Diagn Cytopathol **25**: 172-176, 2001
  - 14) England DM, Hochholzer L and McCarthy MJ: Localized benign and malignant fibrous tumors of the pleura. Am J Surg Pathol **13**: 640-658, 1989

(Received on June 14, 2002)  
(Accepted on August 20, 2002)

(迅速掲載)

## 和文抄録

## 浸潤性発育を示した後腹膜孤立性線維性腫瘍の1例

大阪市立大学大学院医学研究科泌尿器病態学教室（主任：仲谷達也助教授）

仲谷 達也, 玉田 聡

和泉市民病院泌尿器科（部長：岩井謙仁）

岩井 謙仁, 谷本 義明

孤立性線維性腫瘍は稀な疾患である。今回われわれは56歳の女性に発生した悪性後腹膜孤立性線維性腫瘍の1例を報告した。主訴は腹部腫瘤触知で、腹部CTおよびMRI検査にて左腎下方に接して、Gerota筋膜に沿うように発育する境界不明瞭な腫瘤を認めた。手術所見では後腹膜腔にゼラチン状の腫瘍を認め、下行結腸周囲の脂肪組織やGerota筋膜周囲の脂肪組織に浸潤していた。Gerota筋膜内への浸潤は認めなかったため左腎は温存した。病理組織像では間質の膠

原線維は著明に増殖し、hemangiopericytoma様のくちばし状を呈する血管も豊富に認められた。腫瘍組織内に腫瘍細胞密度の増加しているところや核異型度が強く分裂像を認める組織が混在しており、また周囲脂肪組織内に浸潤している所見を認めた。以上より、悪性後腹膜孤立性線維性腫瘍と診断した。治療は外科的切除のみを行い、2年4カ月を経過しても再発無く生存中である。

(泌尿紀要 48: 637-641, 2002)