

Title	Ammonium acid urate urinary stone caused by a low-caloric diet: a case report
Author(s)	Nakamura, Kogenta; Kokubo, Hiroto; Kato, Keitaro; Aoki, Shigeyuki; Taki, Tomohiro; Mitsui, Kenji; Yamada, Yoshiaki; Honda, Nobuaki; Fukatsu, Hidetoshi; Kamijo, Ayumi
Citation	泌尿器科紀要 (2002), 48(8): 483-486
Issue Date	2002-08
URL	http://hdl.handle.net/2433/114809
Right	
Type	Departmental Bulletin Paper
Textversion	publisher

AMMONIUM ACID URATE URINARY STONE CAUSED BY A LOW-CALORIC DIET: A CASE REPORT

Kogenta NAKAMURA, Hiroto KOKUBO, Keitaro KATO,
Shigeyuki AOKI, Tomohiro TAKI, Kenji MITSUI,
Yoshiaki YAMADA, Nobuaki HONDA and Hidetoshi FUKATSU
From the Department of Urology, Aichi Medical University Graduate School of Medicine

Ayumi KAMIJO
From the Department of Urology, Nagoya Ekisaikai Hospital

A 32-year-old woman complained of right back pain and pyuria. The plain radiograph (KUB) and drip infusion pyelography (DIP) demonstrated a right renal stone and hydronephrosis. The stone was successfully treated using extracorporeal shock wave lithotripsy. Infrared spectrophotometry revealed that the stone was composed of pure ammonium acid urate. The patient had a 3-year history of excessive anorexia. The low-caloric diet was considered to have caused the disease.

(Acta Urol. Jpn. 48 : 483–486, 2002)

Key words: Ammonium acid urate, Renal stone, Low-caloric diet

INTRODUCTION

The ammonium acid urate stone is a rare stone, which represents only 0.07% of urolithiasis observed in Japan³⁾. However, as weight-reducing diets take on a surge of popularity, the number of patients with ammonium acid urate stones caused by a low-caloric diet due to anorexia nervosa and by indiscriminate use of laxatives has increased. In the present report, we describe a case in a woman with ammonium acid urate stone who had a history of excessive anorexia with a review of the literature.

CASE REPORT

A 32-year-old Japanese woman consulted a practicing urologist because of having right back pain and cloudiness of urine on July 21, 1999. Drip infusion pyelography (DIP) revealed a stone in the right kidney, and she was introduced to the Department of Urology of our hospital to receive extracorporeal shock wave lithotripsy (ESWL). In the past history, urinary occult blood was detected in the pre-operative examination of chronic tonsillitis in April 1991, but had been left untreated. She had urolithiasis in the right urinary tract in March 1997. The stone was naturally discharged, but the details including its components were unknown. On admission she was 157.5 cm in height and 44 kg in weight. The loss of body mass index (BMI) was 5 kg/m² and her menstruation was normal. Hematology, biochemistry, endocrinological tests and blood gas analysis revealed no abnormalities. The 24-hr urinary excretion study revealed a urine volume of 1,000 ml, pH of 6.0, and normal urinary chemistry. Urinalysis revealed more than 100 white

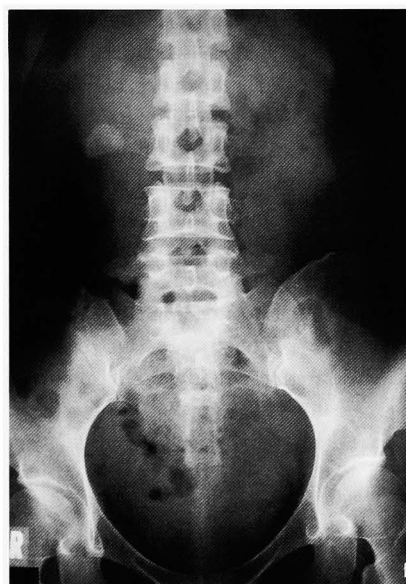

Fig. 1. KUB showing right renal stone.

blood cells and red blood cells per high power field. Urinary culture revealed *Staphylococcus epidermis* and *Enterococcus faecalis*. Plain radiography (KUB) showed a shadow of a stone 24×32 mm in size in her right kidney (Fig. 1). DIP revealed a shadow of a stone in the right renal pelvis accompanied by hydronephrosis (Fig. 2). Based on these findings, she was diagnosed as having a stone in her right kidney.

After indwelling a 6 Fr double J ureteral stent, we treated a stone in the right kidney using ESWL (MFL5000, Dornier) on August 12, 1999. Although sandy stone passage was observed thereafter, KUB demonstrated a residual stone, and ESWL was performed again on September 21, 1999. Stone

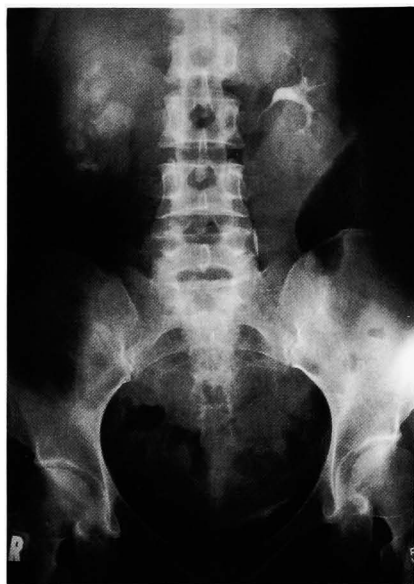

Fig. 2. DIP showing right renal stone and hydronephrosis.

passage was favorable, and DIP confirmed the disappearance of hydronephrosis and complete stone passage on October 9, 1999. Infrared spectrophotometry showed that 98% or more of the total stone mass was composed of ammonium acid urate (Fig. 3).

A survey revealed that the patient had been suffering from excessive anorexia since March 1997 due to separation of family members and recovered after visiting our clinic. Thus one of the reasons for the potential recurrence of urolithiasis was thought to be an excessively low-caloric diet, and she was instructed to eat sufficiently. She had not taken bisacodyl or related medicines. No recurrence has been observed for 22 months, and she is being followed up on an out-patient basis.

DISCUSSION

Ammonium acid urate is often observed as a major

component of a stone in the lower urinary tract in children in Southeast Asia, and is thought to be produced in low phosphoric acid urine caused by low protein and low phosphoric acid diet^{1,2)} Ammonium acid urate stones were frequently observed even in industrialized countries before the 19th century, but patients with these stones markedly decreased with the nutritional improvement¹⁾. Ammonium acid urate stones represent only 0.07% of urolithiasis observed in Japan³⁾ However, as weight-reducing diets take on a surge of popularity, the number of patients with ammonium acid urate stones caused by a low-caloric diet due to anorexia nervosa and by laxative abuse have increased³⁻⁸⁾.

The development of ammonium acid urate stones due to excessive diet control is thought to be caused by the production of severe ammoniuria due to a low protein and low phosphoric acid diet, as observed in a case of a bladder stones in Southeast Asia⁴⁾ In addition, the development of the stone is thought to be promoted by the decrease of urinary output due to vomiting and decreased volume of water intake and the condition of taking a high purine diet due to deviated food habit in the patients with anorexia nervosa. In the present case, because the total urine volume was 1,000 ml/day, development of the stone was thought to be promoted.

Young women sometimes abuse laxatives in order to lose weight or reduce their waistline⁷⁾. The development of ammonium acid urate due to the use of laxatives is thought to be caused by the excretion of water and electrolytes in stools^{5,6)}

Intracellular acidosis occurs because of the supersecretion of aldosterone and loss of potassium due to dehydration and loss of sodium, resulting in the increase of ammonia production in urine. However, in the present case, no indiscriminate use of laxative abuse was observed and plasma aldosterone concentration was normal.

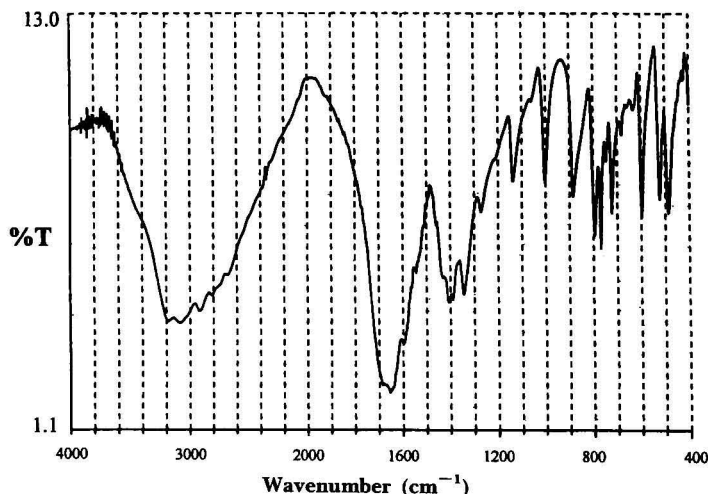


Fig. 3. Infrared spectrophotometry demonstrated that the stone was composed of pure ammonium acid urate.

There are several reports that urinary tract infections can cause ammonium acid urate stones since ammonium acid urate is deposited through release of ammonia due to decomposition of urea by urease-producing bacteria^{2,10,11}). In the present case, a urinary tract infection was observed, but no urease-producing bacteria were detected in the urinary culture. In addition, because calculus analysis revealed an ammonium acid urate content of not less than 98%, the stone in this patient was also thought to be caused by persisting severe ammoniuria due to the decrease of protein and phosphoric acid intake since the patient had been taking a low-caloric diet due to excessive diet control.

Ammonium acid urate stones can be easily crushed using ESWL^{8,9}). However, it was thought necessary to ask the patients about their dietary habits in detail in order to prevent any possible recurrent stone production. Since the patients with anorexia nervosa will increase in the future, urological examinations should be positively performed on those patients with abdominal pain and hematuria.

REFERENCES

- 1) Klohn M, Bolle JF, Reverdin NP, et al. : Ammonium urate urinary stones. *Urol Res* **14** : 315–318, 1986
- 2) Takeuchi H, Okada Y, Yoshida O, et al. : Architecture of ammonium hydrogen urate stones. *Hinyoukigeka* **2** : 491–496, 1989
- 3) Okada Y : Epidemiological studies on rare urinary calculi in Japan. *Hinyoukigeka* **3** : 939–944, 1990
- 4) Saito H, Yoshikawa K, Suzuki T, et al. : Anorexia nervosa complicated with ammonium hydrogen urate stone. *Rinsho Hinyoukika* **51** : 323–325, 1997
- 5) Enomoto Y, Miyazaki J, Minowada S, et al. : A case of ammonium acid urate urinary stone associated with chronic abuse of laxatives. *Rinsho Hinyoukika* **51** : 745–747, 1997
- 6) Dick WH, Lingeman JE, Preminger GM, et al. : Laxative abuse as a cause for ammonium urate renal calculi. *J Urol* **143** : 244–247, 1990
- 7) Wu WJ, Huang CH, Chiang CP, et al. : Urolithiasis related to laxative abuse. *J Formos Med Assoc* **92** : 1004–1006, 1993
- 8) Ishizu K and Naito K : Ammonium urate urinary stone caused by low-caloric diet and laxative use : a case report. *Nishinohon J Urol* **62** : 454–456, 2000
- 9) Kohri K, Takada M, Kurita T, et al. : Ammonium urate urinary stone : its surface structure and incidence in Japan. *Int Urol Nephrol* **21** : 275–279, 1989
- 10) Komori K, Arai K, Fujioka H, et al. : A case of ammonium urate urinary stones with anorexia nervosa. *Acta Urol Jpn* **46** : 627–629, 2000
- 11) Sobble JJ, Hamilton BD and Strem SB : Ammonium acid urate calculi : a reevaluation of risk factors. *J Urol* **161** : 869–873, 1999
- 12) Miyamoto T, Hashimoto H, Terao N, et al. : Pseudo-Bartter syndrome complicated with nephrolithiasis : a case report. *Nishinohon J Urol* **50** : 1045–1049, 1988

(Received on November 30, 2001)
(Accepted on April 13, 2002)

酸性尿酸アンモニウム結石の1例

愛知医科大学医学部大学院泌尿器科学教室（主任：深津英捷教授）

中村小源太，小久保公人，加藤慶太郎
青木 重之，瀧 知弘，三井 健二
山田 芳彰，本多 靖明，深津 英捷

名古屋掖済会病院泌尿器科（主任：西川英二）

上 條 渉

32歳，女性。主訴は右背部痛，膿尿。KUB，DIPにて右腎結石症，右水腎症と診断。体外衝撃波腎結石碎石術（ESWL）施行した。結石成分の結果は，酸性尿酸アンモニウム結石98%以上であった。後の問診の

結果，3年前より過度の拒食症に罹患し低栄養状態が続いていた時期があった。本結石の原因として過度の拒食による低カロリー食が推測された。

（泌尿紀要 48：483-486，2002）