

Title	Encrusted cystitis with ammonium acid urate calculi: a case report
Author(s)	Ito, Masaaki; Kanno, Toru; Kawase, Norio; Taki, Yoji
Citation	泌尿器科紀要 (2002), 48(4): 221-224
Issue Date	2002-04
URL	http://hdl.handle.net/2433/114734
Right	
Type	Departmental Bulletin Paper
Textversion	publisher

ENCRUSTED CYSTITIS WITH AMMONIUM ACID URATE CALCULI: A CASE REPORT

Masaaki ITO, Toru KANNO, Norio KAWASE and Yoji TAKI
From the Division of Urology, Toyooka Public Hospital

We present a case of encrusted cystitis with ammonium acid urate calculi. An 88-year-old man was referred to our hospital to determine the cause of hematuria. He was a patient at another hospital for treatment of interstitial pneumonia with prednisolone. After admission to our hospital, kidney, ureter, bladder X-ray, computed tomography and cystoscopy revealed calcification of about two-thirds of the mucosa of the bladder, and biopsy of the bladder revealed bacterial colonies with inflammation and calcification. Calculographic analysis revealed ammonium acid urate calculi. After treatment with antibiotics and irrigation with solita T1, an acidic solution of pH 3.5–6.5, inflammation and calcification were significantly reduced.

(Acta Urol. Jpn. 48: 221–224, 2002)

Key words: Encrusted cystitis, Ammonium acid urate calculi

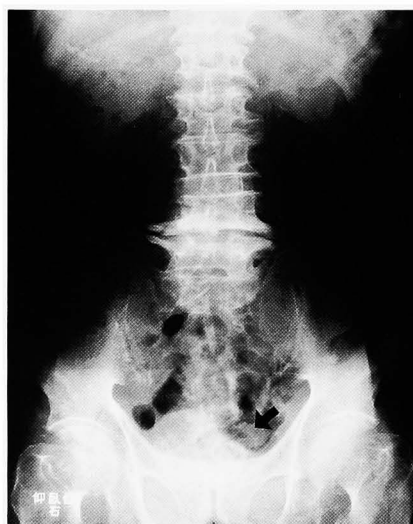INTRODUCTION

We report a case of encrusted cystitis with ammonium acid urate calculi, both of which are rare diseases. Concerning encrusted cystitis, this is the first report in Japan to the best of our knowledge, and the prevalence of ammonium acid urate calculi is only about 0.2–0.3%. The pathophysiological mechanism, clinical features and methods of treatment are also reviewed.

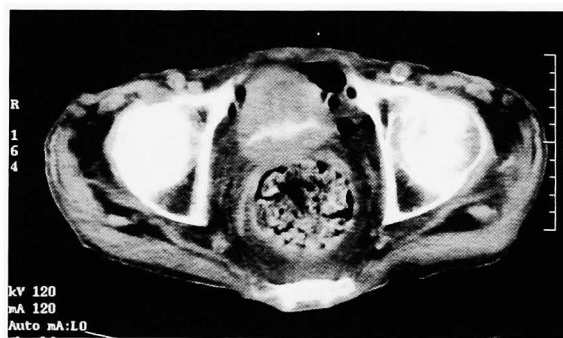CASE REPORT

An 88-year-old man was referred to our hospital for further examination of hematuria. He was a patient at another hospital, and was being treated with prednisolone 40 mg iv/day for interstitial pneumonia. Urine cytology and culture were negative and kidney, ureter, bladder X-ray (KUB) and computed tomographic (CT) examinations revealed calcification of the mucosa of the bladder (Fig. 1a and 1b).

On February 1, 2001, he was admitted to our hospital. Hematological examination was almost normal, except for hyponatremia (133 mEq/ml) and hypouricemia (2.4 mg/dl). However, the urine was severely alkaline (pH 8.5), exhibited hematuria, had a strong odor of ammonia, and clinical examination revealed ulceration and calcification at the urethral meatus. On February 5, we performed cystoscopy and transurethral biopsy of the bladder. There was severe ulceration and encrustation of almost two-thirds of the mucosa of the bladder (Fig. 2), and histopathological examination revealed necrosis, infiltration of inflammatory cells (Fig. 3a), and bacterial colonies (Fig. 3b), but no malignant lesions. Calculographic analysis revealed ammonium acid urate calculi (72%) and calcium phosphate (28%).



a



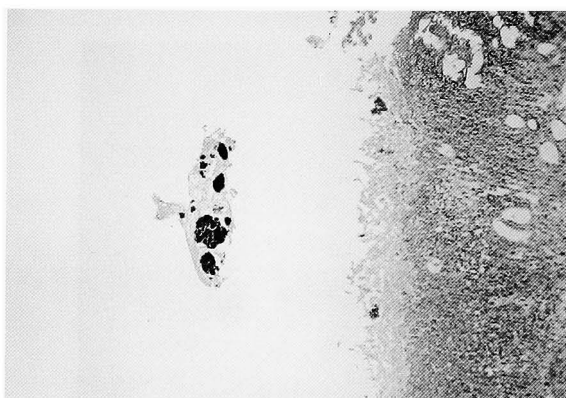
b

Fig. 1. a (KUB) and b (plain CT) show calcification of the mucosa of the bladder.

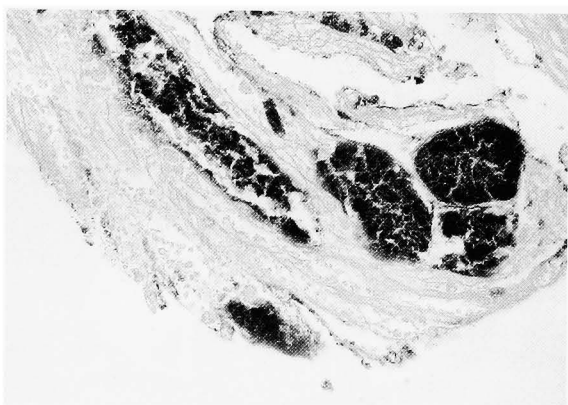
Under the diagnosis of encrusted cystitis, vancomycin was administered at 0.5 g div \times 2/day, since methicillin-resistant staphylococcus aureus (MRSA) was found on the next urine culture, and the bladder was irrigated with solita T1 (pH 3.5–6.5). After 1 week, cystoscopic examination revealed

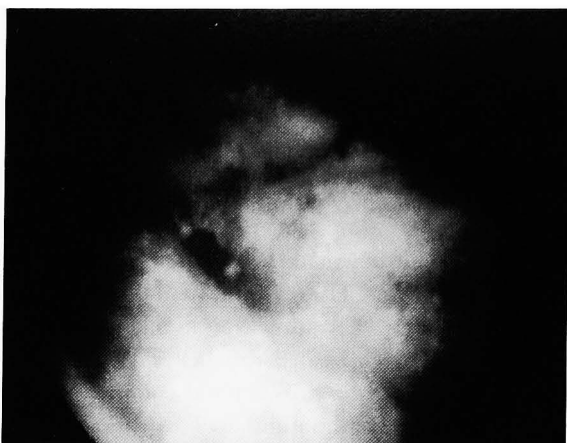

Fig. 2. On cystoscopy, there were severe inflammation and encrustation of almost two-thirds of the bladder mucosa. Figure shows right ureteral orifice.



a



b

Fig. 3. a: Microscopic examination (×100) reveals necrotic tissue and inflammatory cells on the mucosa. b: Microscopic examination (×400) reveals bacterial colonies on the bladder.

significant reduction of encrustation. However, we could not confirm the final result, since the patient died of acute deterioration of interstitial pneumonia about 2 weeks later.

DISCUSSION

Encrusted cystitis develops in the presence of an

alkaline urine, preexisting urological procedure, or urea-splitting bacterial infection^{1,2)} The bacteria deposited on the mucosa of the bladder transform the urea to ammonium and make the urine markedly alkaline, following which alkaline substitutes (for example, struvite and calcium phosphate) deposit on the mucosa of the bladder. Urine always is alkaline, exhibits hematuria and contains calcified mucopurulent debris and has a strong odor of ammonia. Clinical examination reveals ulceration and calcification at the urethral meatus, as in our patient. Urine culture is, in many cases, negative because antibiotics have been given previously or due to lack of cultivation in the usual media (*Corynebacterium* group D2 etc.). In our patient, although urine culture was initially negative, *Corynebacterium* group D2 bacteria may have been present (vancomycin-sensitive) and MRSA was found on the next culture, so we administered vancomycin and confirmed reduction of encrustation.

On radiographic examination, KUB and plain CT revealed calcification along the mucosa of the bladder. On cystoscopy, there was severe ulceration and encrustation, and histologically, necrotic tissue containing calcification in the superficial layer and bacterial colonies and infiltration inflammatory cells (lymphocytes and polymorphonuclear cells) in the deep layer were found.

Treatment consists of 3 elements: treatment of infection with antibiotics, transurethral resection of calcified plaques containing microorganisms, and chemolysis of calcification with acidic solution (Solution G or Thomas C24 solution). We irrigated the bladder with solita T1, since it is acidic (pH 3.5–6.5), and confirmed marked reduction of the lesion. Ammonium acid urate calculus is a very rare stone, the prevalence of which is only about 0.2–0.3%. Conditions predisposing to it include inflammatory bowel disease, laxative abuse, obesity, urinary tract infection (urease-producing bacteria), malnutrition, dehydration and Southeastern Asian infants^{3–6)}. In infectious cases, excess ammonium produced by bacteria combines with uric acid in the urine, and crystals form. In noninfectious cases, loss of potassium into the bowel causes intracellular acidosis, and then ammonia production in the proximal tubular cells of the kidney and elevated ammonia excretion into the urine occur. On the other hand, the loss of sodium and dehydration cause hyperuricosuria. The oversaturated ammonia and uric acid form crystals, and ammonium urate acid calculi grow. Hypophosphamnia, due to malnutrition in many cases, disturbs binding of phosphate and ammonium⁷⁾. Urinary tract infection and increase in the concentration of uric acid in the urine due to dehydration may have been the cause of ammonium urate acid calculi in our case.

The calculi are treated by eliminating the causes and acidification of urine. We gave antibiotics for infection and the bladder was irrigated with acidic fluid, following which the calculi were significantly reduced.

REFERENCES

- 1) Paul M, Arnaud D and Catherine A: Encrusted cystitis and pyelitis. *J Urol* **160**: 3-9, 1998
- 2) Karayannis A, Picramenos D and Sofras F: Encrusted cystitis: aetiology, clinical aspects and management. *Br J Urol* **72**: 571-574, 1993
- 3) Jon JS, Blake DH and Steven BS: Ammonium urate acid calculi: a reevaluation of risk factors. *J Urol* **161**: 869-873, 1999
- 4) William HD, James EL and Glenn MP: Laxative abuse as a cause for ammonium urate calculi. *J Urol* **143**: 244-247, 1990
- 5) Enomoto Y, Miyazaki J, Koyama Y, et al.: A case of ammonium acid urate urinary stone associated with chronic abuse of laxatives. *Rinsho Hinyokika* **51**: 745-747, 1997
- 6) Nishio R, Fujiuchi Y and Nagasawa O: A case of anorexia nervosa with acidic ammonium urate urinary stones. *Jpn J Urol Surg* **14**: 45-47, 2001
- 7) Takeuchi H and Tomoyoshi T: Experimental study on the formation of ammonium acid urate lithiasis. *Acta Urol Jpn* **27**: 1-5, 1981

(Received on September 19, 2001)
(Accepted on December 13, 2001)

和文抄録

酸性尿酸アンモニウム結石を伴った Encrusted cystitis の 1 例

公立豊岡病院泌尿器科（部長：瀧 洋二）

伊藤 将彰，寒野 徹，河瀬 紀夫，瀧 洋二

Encrusted cystitis を発症し，その結石成分として酸性尿酸アンモニウム結石を認めた症例を経験したので報告する。88歳，男性，間質性肺炎に対し他院で治療中血膿尿を認め紹介受診 転院となった。KUB・CT・膀胱鏡にて膀胱内面ほぼ3分の2に石灰化を認め病理所見にて bacterial colony とそれに伴う炎症細

胞の浸潤・石灰化を認めた。またその際の結石分析で酸性尿酸アンモニウム結石と診断された。抗生剤の投与と酸性液であるソリタ T1 による膀胱内灌流で石灰化病変の著明な縮小を認めた。

(泌尿紀要 48 : 221-224, 2002)