

Title	Mesonephric adenocarcinoma of the urinary bladder: a case report
Author(s)	HONDA, Nobuaki; YAMADA, Yoshiaki; NANAURA, Hiroshi; FUKATSU, Hidetoshi; NONOMURA, Hitoshi; HATANO, Yukio
Citation	泌尿器科紀要 (2000), 46(1): 27-31
Issue Date	2000-01
URL	http://hdl.handle.net/2433/114198
Right	
Type	Departmental Bulletin Paper
Textversion	publisher

MESONEPHRIC ADENOCARCINOMA OF THE URINARY BLADDER: A CASE REPORT

Nobuaki HONDA, Yoshiaki YAMADA, Hiroshi NANAURA and Hidetoshi FUKATSU

From the Department of Urology, Aichi Medical University

Hitoshi NONOMURA and Yukio HATANO

From the Department of Urology, Gamagori City Hospital

We report a very rare case of mesonephric adenocarcinoma of the urinary bladder, the origin of which is still uncertain. A non-papillary and broad-based tumor was located in the trigone and bladder neck on cystoscopic examination. Pelvic magnetic resonance imaging in T2-weighted images revealed a mass invading into the muscular layer of the bladder wall. Histologic examination of bladder cup-biopsy specimens showed adenocarcinoma. She underwent total cystectomy and pelvic lymph node dissection. Histologically, the tumor was chiefly composed of cells with eosinophilic cytoplasm and partly of cells with clear cytoplasm or hobnail-shaped cells, arranged in tubular or papillary structures, and infiltrated peri-vesical fat tissues. She died of metastatic disease 22 months after surgery. To the best of our knowledge, the present case is the 19th reported in the literature.

(Acta Urol. Jpn. 46: 27-31, 2000)

Key words: Urinary bladder, Mesonephric adenocarcinoma, Clear cell adenocarcinoma

INTRODUCTION

Mesonephric adenocarcinoma, so-called clear cell adenocarcinoma of the urinary bladder is a very rare neoplasm, resembling nephrogenic adenoma. Concerning the histogenesis of the tumor, various hypotheses have been proposed, but the etiology remains uncertain now.

We herein report a case of locally advanced mesonephric adenocarcinoma of the bladder with poor prognosis and review the literature.

CASE REPORT

A 59-year-old woman was referred to our hospital on April 24, 1992, with the chief complaint of urinary frequency, voiding pain, sense of residual urine and difficulty in urination. Physical examination showed nothing unusual. Laboratory examinations showed elevated erythrocyte sedimentation rate, microscopic hematuria and pyuria, but tumor markers (carcinoembryonic antigen, CA-19-9, α -fetoprotein and basic fetoprotein) were within the normal range except immunosuppressive acid protein. Urinary cytology was positive, suggesting adenocarcinoma. Cystoscopic examination revealed an endophytic non-papillary, solid and broad-based tumor located in the trigone and bladder neck, and the left ureteral orifice was not visible. Histological examinations of cold cup biopsy specimens revealed adenocarcinoma. Detailed examinations of other organs except urinary bladder showed no evidence of malignancy. An excretory urogram revealed left hydronephrosis and a filling defect at the base of the bladder. Pelvic computed tomography (CT) showed a mass at the bladder base protruding beyond the bladder wall.

Pelvic magnetic resonance imaging (MRI) in T2-weighted images revealed a bladder mass invading to the muscular layer with a high signal intensity. A chest radiograph and bone scan survey showed no evidence of metastatic lesion. On June 17, 1992 the patient underwent a radical cystectomy, continent urinary diversion, so-called Indiana pouch and pelvic lymph node dissection. Macroscopically the tumor was chiefly located in the trigone. The tumor appeared non-papillary and sessile in shape and was 4.5×3.5×2 cm in size. Microscopic examination of the removed bladder confirmed the diagnosis of mesonephric adenocarcinoma and disclosed the following characteristic features (Fig. 1); (1) the tumor was composed of tubular glands of various sizes or papillary structures lined with cuboidal or flattened epithelial cells in the vicinity of mucosa (Fig. 1a), (2) tumor cells were small and contained eosinophilic or watery clear cytoplasm with pleomorphic nuclei, forming "hobnail" structure (Fig. 1b), (3) tumor cells infiltrated scirrhously, scatteredly or with unclear glandular space into the muscular layer (Fig. 1c) and they infiltrated peri-vesical fat tissues mildly beyond muscular layer, moreover spreading to the urethra, and (4) mucin production was observed, and partly mucicarmin stained. Pelvic lymph node metastases were not observed.

Postoperatively, the patient was given three courses of systemic combination chemotherapy with cisplatin, doxorubicin and cyclophosphamide at three- to four-week intervals. Her postoperative convalescence was uneventful and routine follow-up studies were done. She was well until 11 months after surgery. However on October 14, 1993 the patient was rehospitalized with right upper thigh pain. A bone

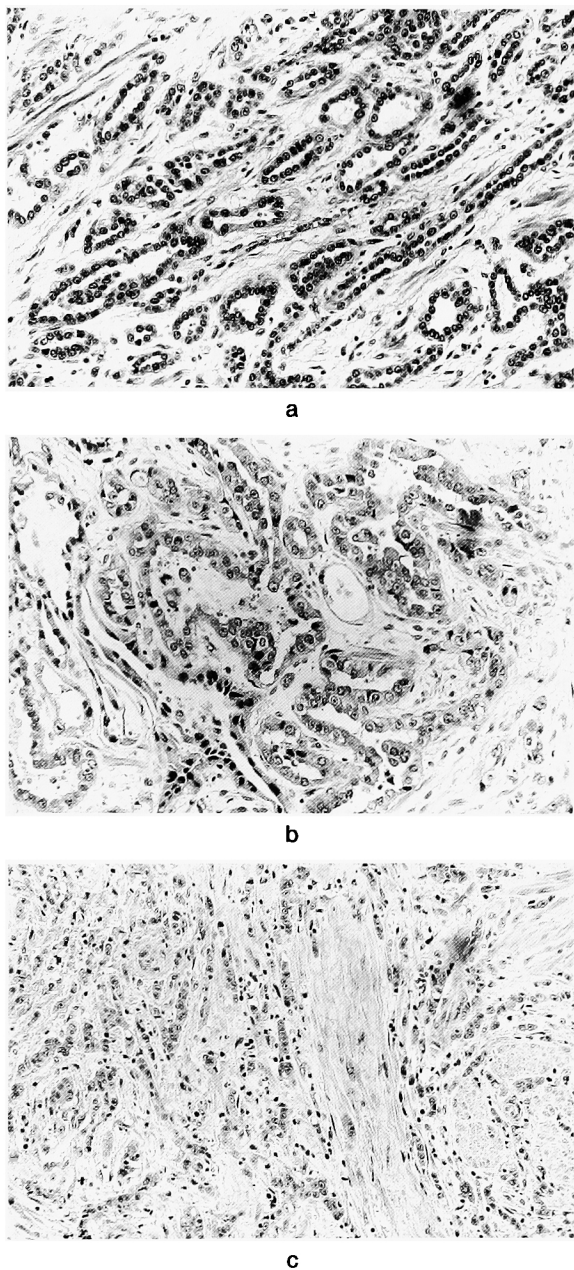


Fig. 1. Microscopic findings of the tumor of removed bladder. a: the tumor was composed of tubular glands of various sizes (HE stain, $\times 200$). b: tumor cells were small and contained eosinophilic or watery clear cytoplasm, forming hobnail structure (HE stain, $\times 200$). c: tumor cells infiltrated scirrhously or scatteredly into the muscular layer (HE stain, $\times 200$).

scan study revealed abnormal hot lesions suspicious of metastasis in the right femur and osteolytic changes, suggesting a metastatic lesion, were recognized at the same site on X-ray film. Subsequently, wide resection of the tumor in the right femur and replacement by artificial femoral head were performed and histological examinations showed the findings of adenocarcinoma consisting of tubular glands consistent with mesonephric

adenocarcinoma of the bladder. Nevertheless, two months after the reoperation, new multiple bone metastases appeared. On April 24, 1994 the patient died of metastatic disease.

DISCUSSION

Mesonephric adenocarcinoma, so-called clear cell adenocarcinoma of the urinary bladder is an extremely rare tumor, first reported as a tumor originating from the mesonephric duct of the trigone by Dow and Young¹⁾ in 1968, and the second case was reported by Misaki et al.²⁾ in 1976 and the third by Skor and Warren³⁾ in 1977. To the best of our knowledge 18 cases have been reported in the literature so far (Table 1).

The term "mesonephric adenocarcinoma" was originally applied by Schiller⁴⁾ to ovarian tumors, characterized histologically by glomerular structures, cystic and tubular structures comprised of hobnail-shaped cells and clear cells similar to renal cell carcinoma, as tumors arose from mesonephric remnants.

However, the histogenesis of the tumor remains uncertain now, and therefore use of the term "mesonephric adenocarcinoma" may be inappropriate. Thus, many authors prefer to use the nomenclature "clear cell adenocarcinoma" to reflect morphological features because of the histological features with similarity to the clear cell adenocarcinoma in female genital organs.

Concerning histogenesis of the tumor, various hypotheses, such as mesonephric duct (wolffian duct) origin, müllerian duct origin or malignant transformation of metaplastic urothelium have been presented. However, no definite view is advocated. Frequent occurrence of the tumor in the trigone, bladder neck and urethra suggests an origin from mesonephric duct^{1,5,6)}, because it is generally accepted that the trigone and primitive urethra between the ureteral orifices and verumontanum stem from the mesonephric duct⁷⁾ That is, the concept of mesodermal origin from mesonephric duct has been generally accepted embryologically. However, not all cases occur in this location⁸⁾ Sugao et al.⁹⁾ and Kuwabara et al.¹⁰⁾ reported that their cases of clear cell adenocarcinoma of the bladder were located in not only the trigone but also posterior wall and left lateral wall in which mesodermal tissue derived from the mesonephric duct is not originally present, suggesting the possibility of malignant transformation of the tissue originating from aberrant müllerian duct as an origin of the tumor as well as most of clear cell carcinomas in female genital organs. Moreover other hypotheses on the histogenesis of the tumor have been proposed. Mostofi¹¹⁾ described that transitional epithelium of the bladder derived from endodermal urogenital sinus was capable of

Table 1. Clinical features of mesonephric adenocarcinoma or clear cell adenocarcinoma of the urinary bladder reported in the literature.

No.	Author	Age	Sex	Symptoms	Tumor location	Treatment	Prognosis	Reference
1	Dow et al.	43	M	urinary frequency urgency, hematuria	rt-lateral wall, neck	R→TC	cancer death (1 Y)	J Urol 100 : 466-469, 1968
2	Misaki et al.	64	F	urinary retention	neck	TUR→R	unknown	Jpn J Urol 67 : 381, 1976
3	Skor et al.	54	F	urinary retention	neck	TC	alive (2 Y)	Urol 10 : 64-65, 1977
4	Kanokogi et al.	53	F	hematuria	posterolateral to rt-ureteral orifice	TC	cancer death (7 M)	J Surg Oncol 22 : 118-120, 1983
5	Sugao et al.	68	F	hematuria	posterior wall lt-lateral wall	PC	alive (3 Y)	Jpn J Urol 74 : 1447-1452, 1983
6	Schultz et al.	70	F	urinary frequency urgency	neck	PE	alive (10 M)	J Urol 132 : 263-265, 1984
7	Minervini et al.	63	M	hematuria recurrent cystitis	lt-lateral wall trigone	TC	alive (2 Y)	Eur Urol 10 : 141-142, 1984
8	Pegoraro et al.	71	F	urinary retention	neck, proximal urethra	R	unknown	J d'Urologie 88 : 531-532, 1982
9	Hausdorfer et al.	57	F	hematuria, urinary frequency, urgency	neck	R→TC	alive (1.5 Y)	Acta Cytol 29 : 823-826, 1985
10	Young et al.	78	F	hematuria, urinary frequency, urgency	trigone	TUR	died of other cause (4 Y)	Am J Surg Pathol 9 : 816-826, 1985
11	Ikemoto et al.	61	F	hematuria	posterior wall	PC	alive (5 Y)	Nishinohon J Urol 48 : 302, 1986
12	Yamashita et al.	62	F	hematuria	superior to lt-ureteral orifice	TUR	unknown	Jpn J Urol 77 : 1216, 1986
13	Funabashi et al.	73	F	urinary retention	posterior wall anterior wall, neck	PE	unknown	Jpn J Pathol
14	Butterworth et al.	53	M	hematuria	posterior wall anterior wall	TUR→R	alive	Histopatho 16 : 601-604, 1990
15	Hiroi et al.	78	F	hematuria	rt-lateral wall, neck	TUR→TC	unknown	Jpn Soc Clin Cytol 30 : 915, 1991
16	Shimizu et al.	72	M	hematuria	trigone, lt-ureteral orifice	TC→R	cancer death (2 Y)	Jpn Soc Clin Cytol 30 : 539-543, 1991
17	Kuwabara et al.	67	M	hematuria	trigone, posterior wall	TC	alive (14 M)	J Clin Urol 47 : 418-421, 1993
18	Shiraishi et al.	80	M	hematuria	neck, lt-ureteral orifice	TUR→C	alive	Nishinohon J Urol 59 : 107-110, 1997

R: radiation, TC: total cystectomy, PC: partial cystectomy, PE: pelvic exenteration, C: chemotherapy.

neoplastic metaplasia into squamous, columnar and cuboidal cells, which may undergo malignant transformation, and metaplasia of urothelium in response to chronic irritation was suggested to be the origin of this tumor. De La Pena et al.¹²⁾ also proposed that the neoplasm derives from epithelial cells which were transformed in a pathological response to chronic irritation.

Histologically, mesonephric adenocarcinoma so-called "clear cell adenocarcinoma" is characteristically composed of clear and hobnail cells, and the tumor cells proliferate arranged in papillary, tubular or solid structure¹³⁾. The neoplasm was comprised of two distinct cell populations¹⁴⁾. A papillary component consisted of cells having a distinct "hobnail" appearance. The second component consisting of clear cells arranged in an alveolar and tubular pattern. In the present case, the tumor is chiefly composed of dark cells with an eosinophilic cytoplasm and partly of cells with a clear cytoplasm and hobnail cells with a papillary and glandular pattern.

Mesonephric adenocarcinoma of the bladder is

relatively easily distinguished from other adenocarcinomas such as those of urachal origin or arising in metaplastic transitional epithelium¹⁴⁾. Adenocarcinoma of the bladder of urachal origin or arising in metaplastic transitional epithelium do not have papillary or clear cell features. The main differential diagnosis is nephrogenic adenoma⁸⁾ and histological evidence of muscular invasion and nuclear atypia is an important distinguishing feature^{6,13)}

The prognosis of the mesonephric adenocarcinoma is unclear because of unusual tumor and inadequate follow-up period. However, it may depend on the depth of invasion in the bladder wall. The treatment of the tumor is advisable according to the general principles of management in carcinomas of the urinary bladder¹³⁾ and radical surgery may be required for a cure⁶⁾.

REFERENCES

- 1) Dow JA and Young JD Jr: Mesonephric adenocarcinoma of the bladder. J Urol **100**: 466-469, 1968
- 2) Misaki T, Kanda T, Sawaki M, et al.: Mesonephric

- adenocarcinoma of bladder neck: a case report. *Jpn J Urol* **68**: 381, 1976
- 3) Skor AB and Warren MM: Mesonephric adenocarcinoma of bladder. *Urology* **10**: 64-65, 1977
 - 4) Schiller W: Mesonephroma ovari. *Am J Cancer* **35**: 1-21, 1939
 - 5) Minervini R, Urbano U and Fiorentini L: Mesonephric adenocarcinoma of bladder. *Eur Urol* **10**: 141-142, 1984
 - 6) Schultz RE, Bloch MJ, Tomaszewski JS, et al.: Mesonephric adenocarcinoma of the bladder. *J Urol* **132**: 263-265, 1984
 - 7) Kanokogi M, Uematsu K, Kakudo K, et al.: Mesonephric adenocarcinoma of the urinary bladder: an autopsy case. *J Surg Oncol* **22**: 118-120, 1983
 - 8) Butterworth DM, Haboubi NY and Lupton EW: Mixed mesonephric adenocarcinoma and transitional cell carcinoma of the bladder. *Histopathology* **16**: 601-604, 1990
 - 9) Sugao H, Suzuki S, Yokokawa M, et al.: Clear cell adenocarcinoma of the bladder. *Jpn J Urol* **74**: 1447-1452, 1983
 - 10) Kuwabara M, Nishitani M, Matsushita K, et al.: Clear cell adenocarcinoma of the bladder: a case report. *Jpn J Clin Urol* **47**: 418-421, 1993
 - 11) Mostofi FK: Potentialities of bladder epithelium. *J Urol* **71**: 705-714, 1954
 - 12) De La Pena A, Oliveres M, Tamaines JM, et al.: Metaplastic and malignant changes of the urothelium. *Br J Urol* **31**: 473-484, 1959
 - 13) Young RH and Scully RE: Clear cell adenocarcinoma of the bladder and urethra: a report of three cases and review of the literature. *Am J Surg Pathol* **9**: 816-826, 1985
 - 14) Hausdorfer GS, Chandrasoma P, Pettross BR, et al.: Cytologic diagnosis of mesonephric adenocarcinoma of the urinary bladder. *Acta Cytol* **29**: 823-826, 1984

(Received on March 15, 1999)
(Accepted on September 18, 1999)

和文抄録

膀胱原発 Mesonephric adenocarcinoma の 1 例

愛知医科大学泌尿器科学教室（主任：深津英捷教授）

本多 靖明，山田 芳彰，七浦 広志，深津 英捷

蒲郡市民病院泌尿器科（部長：羽田野幸夫）

野々村仁志，羽田野幸夫

発生起原が明らかにされていない，きわめて稀な膀胱の mesonephric adenocarcinoma の 1 例を報告した．非乳頭状 広基性腫瘍が膀胱三角部および頸部を中心に存在し，一部尿道への進展がみられた．MRI で腫瘍は筋層に浸潤し，膀胱全摘除術を施行した．病理組織学的には，腫瘍細胞は主に好酸性顆粒状，一部

淡明を有する細胞および hobnail 型の細胞から成り，管状あるいは乳頭状腺癌の構造を示した．手術後 1 年 10 カ月で骨転移のため死亡した．本症例はわれわれの知るかぎり，国内外の文献上 19 例目の報告であった．

（泌尿紀要 46 : 27-31, 2000）