

Title	A case of bilateral testicular calcifications in a bicycle motocross rider accompanied by bulbar urethral injury
Author(s)	Izumi, Kouji; Konaka, Hiroyuki; Seto, Chikashi; Komatsu, Kazuto; Yokoyama, Osamu; Namiki, Mikio
Citation	泌尿器科紀要 (2006), 52(5): 383-386
Issue Date	2006-05
URL	<a href="http://hdl.handle.net/2433/113844">http://hdl.handle.net/2433/113844</a>
Right	
Type	Departmental Bulletin Paper
Textversion	publisher

## A CASE OF BILATERAL TESTICULAR CALCIFICATIONS IN A BICYCLE MOTOCROSS RIDER ACCOMPANIED BY BULBAR URETHRAL INJURY

Kouji IZUMI, Hiroyuki KONAKA, Chikashi SETO,  
Kazuto KOMATSU, Osamu YOKOYAMA and Mikio NAMIKI  
*The Department of Urology, Kanazawa University School of Medicine*

A 21-year-old Japanese man who was a professional bicycle motocross rider injured his perineum during a competition. Chief complaints were gross hematuria, perineal pain, and subcutaneous ecchymosis of the scrotum. Urethrocytography revealed a torn bulbar urethra and extravasation in the same region. Scrotal ultrasonography revealed small calcifications in the bilateral testes. Here, we report a case of bilateral testicular calcifications caused by the continuous shock and vibration of the saddle in an off-road bicycle rider.

(Hinyokika Kyo 52 : 383-386, 2006)

**Key words :** BMX, Testicular calcification, Urethral injury

### INTRODUCTION

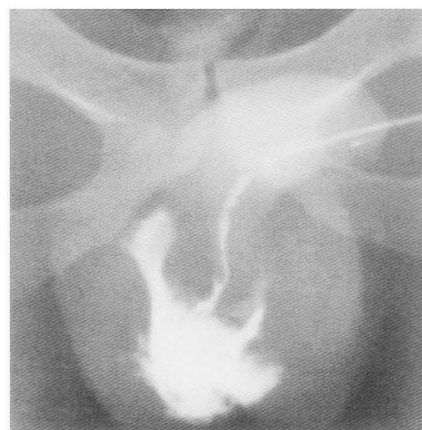Since the early 1970s, off-road bicycles have become increasingly popular worldwide and the bicycle motocross (BMX) was introduced at about the same time in southern California. During BMX races, the riders must manage many jumps and turns in rough terrain. The resultant shocks and vibrations of the saddle due to the rough terrain cause repeated, chronic microtrauma of the perineum.

In the United States, significantly higher incidences of extratesticular and testicular disorders have been demonstrated in off-road bikers than in non-cyclists. In most cases, however, no treatment is required<sup>1)</sup>. Here, we report such a case of a BMX rider with bulbar urethral injury.

### CASE REPORT

A 21-year-old Japanese BMX rider whose perineum was impacted during a BMX competition in California 3 days previously was admitted to our hospital with gross hematuria, perineal pain, and subcutaneous ecchymosis of the scrotum. He rode and jumped with his BMX, and the saddle strongly impacted against his perineum on landing. He had been riding his BMX 4 hours a day for 6 years and had not had any previous urological symptoms. A urethral catheter had already been inserted in his urethra by a doctor in California with a flexible urethroscope.

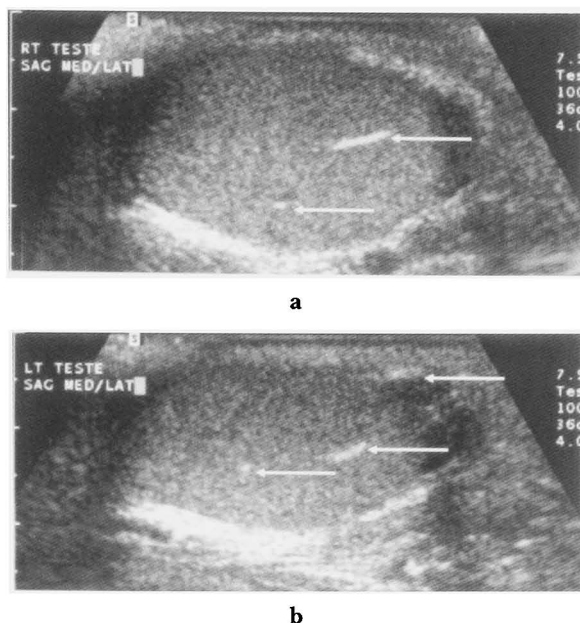
Physical examination did not indicate any other acute injuries, including those of the head, face, neck, abdomen, back, or the extremities, nor any neurological injuries. Neither scrotal tenderness, discomfort, nor abnormal findings were found by palpation (*i.e.*, there was no palpable mass or irregularity on the surface of the scrotal contents). The patient had no history of either severe scrotal trauma or inflammation. Retrograde



**Fig. 1.** Retrograde urethrocytogram. Front projection image showing extravasation from the torn bulbar urethra.

urethrocytography (UCG) revealed a torn bulbar urethra and extravasation in the same region (Fig. 1). The results of urine cultures throughout his period of hospitalization did not suggest any urinary tract infection, but antibiotic treatment was administered for a few weeks to prevent subsequent infection from the indwelling catheter in the urethra.

Scrotal ultrasonography (US) was performed to exclude testicular contusion, and identified bilateral testicular calcifications and the volume of the right (13.1 ml) and left (14.0 ml) testis (Fig. 2a, b). There were no other abnormal findings (*e.g.*, scrotal calculi, epididymal cysts, epididymal calcifications, hydroceles, varicoceles, or testicular microlithiasis (TM)) observed by scrotal US. Three weeks later, the urethral catheter was removed followed by voiding cystourethrography (VCUG), which showed that the extravasation had improved markedly. Incontinence was not recognized after removal of the catheter. Gross hematuria, perineal pain, and subcutaneous ecchymosis of the



**Fig. 2.** Scrotal ultrasonogram. (a) Right longitudinal section. (b) Left longitudinal section. These ultrasonograms show a few calcifications in both testes but no other abnormalities (arrows).

scrotum had already disappeared at this stage. Uroflowmetry was also performed, showing a voiding volume of 280 ml, a maximum flow rate of 23.5 ml/s, an average flow rate of 11.9 ml/s, and a residual volume of a little. The patient was discharged after a hospitalization period of 24 days and was scheduled to be followed up as an outpatient at our hospital.

Two months later, we performed a seminal examination, uroflowmetry, and scrotal US. The sperm count was 55 million for a total volume of 3 ml, sperm motility was 65.5%, and sperm anomaly <10%. The results of uroflowmetry had hardly changed compared with the previous findings. Scrotal US still showed bilateral testicular calcifications. The international index of erectile function score was 23 points. This patient is currently being followed up on an outpatient basis and he shows neither dysuria nor incontinence.

### DISCUSSION

Cycling injuries account for 500,000 visits per year to emergency rooms in the United States. Contusions, sprains, and fractures may occur throughout the body. The handlebar and seat have been implicated in a wide variety of abdominal and genital injuries. Saddle-related problems include chafing, perineal folliculitis and furuncles, subcutaneous perineal nodules, pudendal neuropathy, erectile dysfunction, traumatic urethritis, and a variety of vulvar traumas<sup>2)</sup> BMX riding has a high risk of injury: 1,190 injuries per 1,000 competition hours<sup>3)</sup>.

Scrotal US of a BMX rider with injury to the bulbar urethra revealed bilateral testicular calcifications.

These are found in 3% of healthy individuals<sup>4)</sup> Frauscher et al. first reported that extreme mountain bike riders very frequently (94%) had various abnormalities of the scrotum, *e.g.*, scrotal calculi, epididymal cysts, epididymal calcifications, hydroceles, and varicoceles, and testicular calcifications were found at a frequency of 32% in these subjects<sup>1)</sup> They suggested that calcifications are related to previous trauma, inflammation, and/or degeneration<sup>3)</sup> Repeated testicular microtraumas lead to hematoma and chronic infarct, and may lead to subsequent vascular calcifications. However, their exact nature is not known. We believe our patient also sustained intense impact to the perineum and testes in the same manner as extreme mountain bike riders. However, there have been few reports regarding the relationship between off-road biking and scrotal abnormalities.

Criteria for differential diagnosis of testicular calcifications, which show high echogenicity on scrotal US, include teratoma, epidermoid cysts, hematoceles, mediastina, torsion of the appendix testis, sarcoidosis, orchitis, tuberculosis, syphilitic gumma, and TM.

We diagnosed this case as calcifications caused by repeated microtraumas as no multiple irregular areas of hypoechogenicity caused by testicular trauma accompanied by rupture were observed and the results of physical examination for tumor and infection were negative<sup>5,6)</sup>. Moreover, the patient's career as a BMX rider had been intense. TM appears as scattered tiny punctate echogenic foci, which typically do not produce shadows on US. Many investigators have reported an association between TM and testicular tumors. In the present case, testicular calcifications were different from TM with respect to their number, size, and the presence of acoustic shadows<sup>7)</sup> In the case of 'burned-out' testicular tumors, the findings on palpation may be normal, but US may reveal tumor scars in the form of small highly reflective foci. Additional systemic examination may be required to rule out 'burned-out' testicular tumors<sup>8)</sup>.

Long-term observations of testicular calcifications caused by repeated microtraumas as in our case have not been reported. Whether testicular calcifications per se are clinically significant is not yet clear. However, accumulation of microtraumas sufficient to cause testicular calcifications may lead to morbidity, such as testicular tumor or infertility. Thus, it seems advisable to perform regular US and seminal examination for follow-up in such cases. Whether US should be performed proactively for off-road bikers without scrotal symptoms will depend on the results of further examinations, including long-term screening.

### CONCLUSIONS

We reported a case of bilateral testicular calcifications caused by continuous shock and vibration of the saddle during off-road bicycle riding. Although there were no

symptoms in this case, we need to investigate the significance of testicular calcifications. We should perform scrotal US in extremely intense off-road bikers.

### REFERENCES

- 1) Frauscher F, Klauser A, Stenzl A, et al. : US findings in the scrotum of extreme mountain bikers. *Radiology* **219** : 427-431, 2001
- 2) Mellion MB : Common cycling injuries. management and prevention. *Sports Med* **11** : 52-70, 1991
- 3) Brogger-Jensen T, Hvass I and Bugge S : Injuries at the BMX Cycling European Championship, 1989. *Br J Sports Med* **24** : 269-270, 1990
- 4) Leung ML, Gooding GAW and Williams RD : High-resolution sonography of scrotal contents in asymptomatic subjects. *Am J Roentgenol* **143** : 161-164, 1984
- 5) Howlett DC, Marchbank ND and Sallomi DF : Pictorial review : ultrasound of the testis. *Clin Radiol* **55** : 595-601, 2000
- 6) Gerscovich EO : High-resolution ultrasonography in the diagnosis of scrotal pathology : I. normal scrotum and benign disease. *J Clin Ultrasound* **21** : 355-373, 1993
- 7) Bennett HF, Middleton WD, Bullock AD, et al. : Testicular microlithiasis : US follow-up. *Radiology* **218** : 359-363, 2001
- 8) Shawker TH, Javadpour N, O'Leary T, et al. : Ultrasonographic detection of 'burned-out' primary testicular germ cell tumours in clinically normal testis. *J Ultrasound Med* **2** : 477-479, 1983

(Received on September 1, 2005)  
(Accepted on January 5, 2006)

## 和文抄録

球部尿道損傷を受傷した Bicycle motocross rider に認められた  
両側精巣石灰化の1例

泉 浩二, 小中 弘之, 瀬戸 親  
小松 和人, 横山 修, 並木 幹夫  
金沢大学医学部附属病院泌尿器科

21歳の日本人男性が BMX 競技中に会陰部を強打し、会陰部疼痛、肉眼的血尿、陰囊皮下出血を訴え受診した。逆行性尿道造影にて球部尿道に造影剤の溢流があり、断裂が明らかとなった。陰囊超音波検査では

両側精巣内に複数の小石灰化が認められた。オフロード用自転車のサドルによる持続的な衝撃と振動のために生じた精巣の石灰化の1例を報告する。

(泌尿紀要 52 : 383-386, 2006)