

Title	Mullerian duct remnant involving Wolffian system : a case report and literature review
Author(s)	Kato, Haruaki; Igawa, Yasuhiko; Furuya, Seiji; Nishizawa, Osamu
Citation	泌尿器科紀要 (2005), 51(5): 339-342
Issue Date	2005-05
URL	<a href="http://hdl.handle.net/2433/113608">http://hdl.handle.net/2433/113608</a>
Right	
Type	Departmental Bulletin Paper
Textversion	publisher

## MÜLLERIAN DUCT REMNANT INVOLVING WOLFFIAN SYSTEM: A CASE REPORT AND LITERATURE REVIEW

Haruaki KATO<sup>1\*</sup>, Yasuhiko IGAWA<sup>1</sup>, Seiji FURUYA<sup>2</sup> and Osamu NISHIZAWA<sup>1</sup>

<sup>1</sup>The Department of Urology, Shinshu University School of Medicine

<sup>2</sup>The Department of Urology, Furuya Hospital

A 14-month-old boy with repeated left acute epididymitis was admitted to our department. Ultrasonography detected a midline round cystic mass in a retrovesical region. This was easily opacified by cystourethrography and seen to have a free communication with the posterior urethra. Since urethroscopy revealed a passable orifice in the center of the verumontanum, while a cystic-wall biopsy specimen showed squamous epithelium, we considered this cystic lesion to be an enlarged prostatic utricle. Vasography showed that the bilateral vasa was implanted directly into this cystic lesion, and was the possible cause of his left epididymitis. Ligature of the left vas deferens was performed to prevent left epididymitis. An enlarged prostatic utricle involving the vasa is a rare presentation.

(Hinyokika Kyo 51 : 339-342, 2005)

**Key words** : Müllerian remnants, Enlarged prostatic utricle, Vasa, Ejaculatory ducts

### INTRODUCTION

Ritchev et al. classified abnormalities of the Müllerian duct remnants into two main distinct categories on the basis of clinical manifestations<sup>1)</sup> They noted that in older patients with normal genitalia, a cystic configuration often presents with an incidental rectal mass, whereas in young patients an enlarged tubular structure communicating with the urethra is associated with hypospadias or intersex disorder. On the basis of our previous pathologic study, we agree with their classification and with their suggestion that these two abnormalities have different etiologies<sup>2)</sup> The first type is generally called the Müllerian duct cyst or prostatic utricle cyst, and the second type the enlarged prostatic utricle.

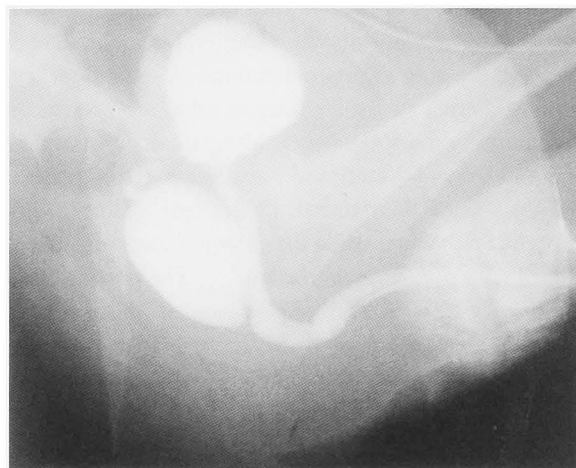Here, we report our recent experience of a patient with an enlarged prostatic utricle, into which the vasa opened directly, and we review the literature relating to Müllerian duct remnants involving the vasa or ejaculatory ducts.

### CASE REPORT

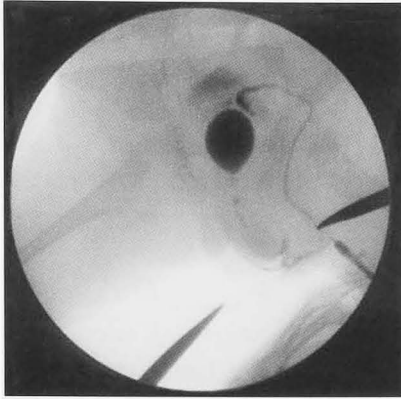
A 14-month-old boy with Down's syndrome was experiencing cardiac problems and was admitted to our department because of repeated acute epididymitis. The external genitalia were normal. Intravenous urography showed normal upper urinary tracts, and ultrasonography showed a round cystic mass behind the bladder. Voiding cystourethrography disclosed a round pouch connecting both with the posterior urethra and with the vasa during voiding (Fig. 1). To prevent left epididymitis, we performed ligature of the left vas deferens through a left scrotal skin incision. Intraoperative left vasography disclosed a pouch in the

midline, and the bladder was also opacified (Fig. 2a).

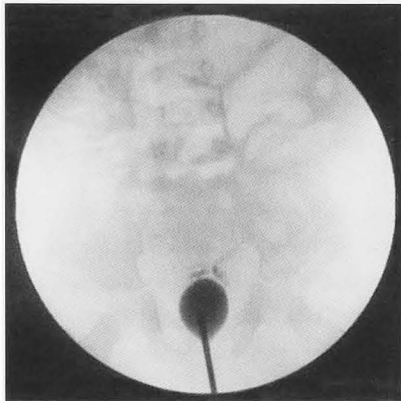
A 10 Fr rigid urethroscope could be introduced into the cavity via an orifice about 5 mm in diameter in the center of the verumontanum. This opened gradually during filling with the irrigating saline, but was otherwise constrictive. Bilateral vasal openings were observed in a symmetrical position in the posterior wall of the pouch. Reflux into both vasa was observed following injection of contrast material into the pouch (Fig. 2b). A small piece of tissue was taken from the pouch wall for biopsy, and the orifice was incised widely to avoid urine stasis in the pouch. Histologically, the tissue proved to be squamous epithelium. Convalescence was uneventful with no episode of contralateral epididymitis. The cystic mass was observed to shrink in size postoperatively.



**Fig. 1.** Voiding cystourethrography shows an opacified pouch (3×2 cm) connecting to the urethra. The vasa are visualized in the cranial part of the pouch.



**Fig. 2a.** Left vasography shows a cystic mass in the midline with the ipsilateral vas deferens. Both the bladder and the urethra are visualized.

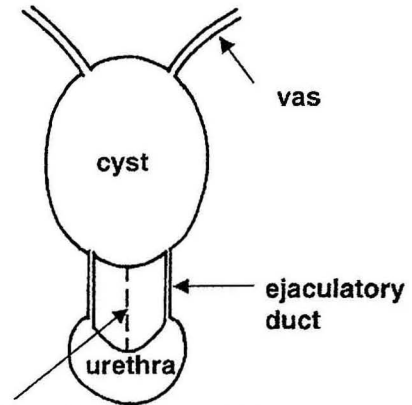


**Fig. 2b.** Injection of contrast material shows the cystic mass as well as reflux up to both Wolffian systems.

### DISCUSSION

According to Ritchey et al.<sup>1)</sup> (see Introduction), a cystic configuration usually seen in older patients with normal genitalia corresponds well to the Müllerian duct cyst, whereas a tubular or vesicular structure communicating with the urethra in younger patients with hypospadias or intersex disorder is compatible with the enlarged prostatic utricle. Earlier, Devine et al. had proposed the term vagina masculinus for use only when other Müllerian structures (uterus, tube) are present in continuity<sup>3)</sup> Furthermore, a histopathologic study, if available, would be an additional support for correct diagnosis since the Müllerian duct cyst is lined with prostatic epithelium, while the enlarged prostatic utricle is lined with squamous epithelium<sup>2)</sup> The present case, in spite of the normal appearance of the external genitalia, was categorized as an enlarged prostatic utricle, since a patent orifice into the urethra was present and its lining proved to be squamous epithelium.

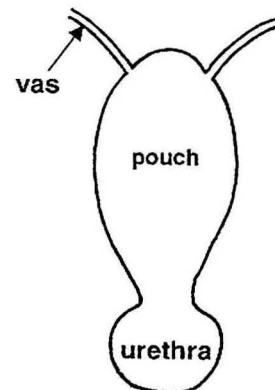
From our literature review, both types of Müllerian duct remnants could involve the ejaculatory ducts or the vasa. Elder and Mostwin reviewed seven cases of the Müllerian duct cyst, including their own case<sup>4)</sup>, in which the ejaculatory ducts were involved, and Yamashita et



**narrowed or obstructed outlet**

#### Type 1

**Fig. 3a.** Schematic drawing of Müllerian duct remnants involving the Wolffian system. In Müllerian duct cyst (prostatic utricle cyst), an enlarged cyst (due to a narrowed or obstructed outlet into the urethra) finally involves the ejaculatory ducts. The verumontanum is completely formed. Anatomical position of the seminal vesicle should be normal.



#### Type 2

**Fig. 3b.** In enlarged prostatic utricle, the position of the ejaculatory ductal orifice gradually regresses by invagination and enlargement of the patent pouch. The position of the seminal vesicle should be cranial to the pouch if it is normally formed.

al. reported a similar case<sup>5)</sup> Such cases have been reported sporadically; however, communication with the ejaculatory ducts in cases of Müllerian duct cyst may not be an unusual finding in subfertile or hemospermic patients<sup>6,7)</sup> On the other hand, cases with an enlarged prostatic utricle, into which the vasa open directly, seem to be extremely rare. Indeed, to our knowledge only nine cases have been clearly described in the five reports in the English-language literature<sup>8-12)</sup>

With regard to the etiologies of Müllerian duct remnants involving the seminal tracts, we speculate that a gradual enlargement of the Müllerian duct or prostatic utricle cyst (due to a narrowed or obstructed midline

outlet) compresses the ejaculatory ducts, and that this finally leads to communication with the cystic cavity (Fig. 3a). Whereas according to our literature review, the vasa implant directly into the enlarged prostatic utricle. We speculate that the orifice of the ejaculatory ducts might initially open into the urogenital sinus normally. However, due to invagination of the urogenital sinus and its enlargement, probably due to feminization, the orifice may regress cranially and perhaps be trapped by the pouch (Fig. 3b).

According to Desautel et al.<sup>13)</sup>, because of technical difficulties surgical intervention for an enlarged prostatic utricle should generally be limited to those with severe symptoms, such as recurrent urinary tract infection due to urinary stasis or urinary retention. The surgical approach--which can be transvesical-transtrigonal, extravesical, perineal, or posterior sagittal--should be selected according to the situation, with transurethral fulguration being another option. When the vasa enter into the enlarged prostatic utricle, they need to be cut for extirpation<sup>8-12)</sup>. In our case, palliative endoscopic incision of the pouch orifice to prevent urine stasis was performed as a temporary treatment since the patient had preexisting cardiac problems.

#### REFERENCES

- 1) Ritchey ML, Benson RC, Kramer SA, et al.: Management of müllerian duct remnants in the male patient. *J Urol* **140**: 795-799, 1988
- 2) Kato H, Komiyama I, Maejima T, et al.: Histopathological study of the müllerian duct remnant: clarification of disease categories and terminology. *J Urol* **167**: 133-136, 2002
- 3) Devine CJ Jr, Gonzales-Serva L, Stecker JF Jr, et al.: Utricular configuration in hypospadias and intersex. *J Urol* **123**: 407-411, 1980
- 4) Elder JS and Mostwin JL: Cyst of the ejaculatory duct/urogenital sinus. *J Urol* **132**: 768-771, 1984
- 5) Yamashita T, Watanabe K and Ogawa A: Retroprostatic midline cyst involving both ejaculatory ducts. *Urol Radiol* **7**: 178-179, 1985
- 6) Hendry WF and Pryor JP: Müllerian duct (prostatic utricle) cyst: diagnosis and treatment in subfertile males. *Br J Urol* **69**: 79-82, 1992
- 7) Furuya S, Ogura H, Shimamura S, et al.: Transurethral endoscopic treatment for chronic hemospermia caused by müllerian duct cyst and ejaculatory duct obstruction. *Acta Urol Jpn* **47**: 839-842, 2001
- 8) McKenna CM and Kiefer JH: Congenital enlargement of the prostatic utricle with inclusion of the ejaculatory ducts and seminal vesicle. *Trans Am Assoc Genito-Urin Surg* **32**: 305-320, 1939
- 9) Polse S and Edelbrock H: Prostatic utricular enlargement as a cause of vesical outlet obstruction in children. *J Urol* **100**: 329-332, 1968
- 10) Siegel JF, Brock WA and Pena A: Transrectal posterior sagittal approaches to prostatic utricle (müllerian duct cyst). *J Urol* **153**: 785-787, 1995
- 11) Monfort G: Transvesical approach to utricular cysts. *J Pediatr Surg* **17**: 406-409, 1982
- 12) Tank ES and Hatch DA: Müllerian remnant causing bladder outlet obstruction. *J Pediatr Surg* **21**: 77-80, 1986
- 13) Desautel MG, Stock J and Hanna MK: Müllerian duct remnant: surgical management and fertility issue. *J Urol* **162**: 1008-1014, 1999

(Received on July 15, 2004)

(Accepted on January 15, 2005)

## 和文抄録

## ミューラー管遺残と精管，射精管との交通：症例報告および文献的考察

加藤 晴朗<sup>1</sup>，井川 靖彦<sup>1</sup>，西澤 理<sup>1</sup>，古屋 聖児<sup>2</sup><sup>1</sup>信州大学医学部泌尿器科学教室，<sup>2</sup>古屋病院泌尿器科

症例は14カ月の男児。繰り返す左精巣上体炎で入院した。超音波検査で膀胱後部に円形の嚢胞性腫瘤を認め、排尿時膀胱造影で後部尿道と交通していた。内視鏡の結果、嚢胞は精阜の中央に尿道との交通を認め、嚢胞壁の生検で扁平上皮と判明したため、拡張した前立腺小子宮と診断した。精管造影と嚢胞造影より、両

側精管が直接、この嚢胞性疾患に開口しており、左精巣上体炎の原因と考えられた。左精管結紮術を施行した。拡張した前立腺小子宮に精管が開口することは、稀な病態である。

(泌尿紀要 51 : 339-342, 2005)