

|             |   |
|-------------|---|
| Title       | Urethral reconstruction using buccal mucosa urethroplasty in the treatment of urethral injury |
| Author(s)   | Hayakawa, Kunihiro; Hayashi, Eiri; Hata, Makoto; Tonogi, Morio                                |
| Citation    | 泌尿器科紀要 (2005), 51(5): 343-346   |
| Issue Date  | 2005-05   |
| URL         | <a href="http://hdl.handle.net/2433/113607">http://hdl.handle.net/2433/113607</a>             |
| Right       |   |
| Type        | Departmental Bulletin Paper   |
| Textversion | publisher   |

## URETHRAL RECONSTRUCTION USING BUCCAL MUCOSA URETHROPLASTY IN THE TREATMENT OF URETHRAL INJURY

Kunihiro HAYAKAWA, Eiri HAYASHI, Makoto HATA and Morio TONOGI

*The Department of Urology and Oral Medicine, Ichikawa General Hospital, Tokyo Dental College*

A 52-year-old Japanese man was referred to us with a urethral injury caused by masturbation. His penis was swollen and about one and a half times its size due to urine extravasation and infection. Foreign bodies were surgically removed, and debridement and excision of necrotic tissue were performed. After confirming that the infection was under control, we planned the reconstruction of the urethra and penis, following endoscopic urethrotomy for the bulbous urethra stricture. A free graft from the buccal mucosa was harvested, placed over the defect and fixed with interrupted suture as ventral onlay. The patient could achieve satisfactory voiding and no complication was seen during the 18-month follow up. In our experience, buccal mucosa is a useful source of urethral grafting material and excellent results can be expected in case of urethral injury.

(Hinyokika Kyo 51 : 343-346, 2005)

**Key words :** Urethral injury, Urethroplasty, Buccal mucosa graft

### INTRODUCTION

Management of infectious urethral injury is sometimes quite troublesome. We describe a case of urethral injury, which was successfully managed using a buccal mucosa graft.

### CASE REPORT

A 52-year-old Japanese man was referred to us with a urethral injury caused by masturbation, which was coaxed by his schizophrenic wife. His penis was swollen and about one and a half times its size due to urine extravasation and infection; it also showed tissue necrosis resembling Fournier's gangrene. The X-ray photograph showed two pieces of cylindrical foreign bodies, one of which was in the bulbous urethra and the other was in the pendulous penile urethra (Fig. 1).

The foreign bodies were surgically removed, and debridement and excision of necrotic tissue were performed until normal tissue was found. Suprapubic diversion was made and the wound was left open for about 6 months.

In this stage a half round defect of about 3 cm in the pendulous urethra, a urethral stricture of the bulbous portion and a urethro-cutaneo fistula were observed in the urethra (Fig. 2). After confirming that the infection was under control, we planned the reconstruction of the urethra and penis following an endoscopic urethrotomy for the bulbous urethra stricture.

Single-stage urethroplasty with an onlay patch graft of buccal mucosa was performed 15 months after his first visit to our hospital.

As for the operative procedure, a two-team approach was used in which one team harvested the graft from the mouth while the other team simultaneously exposed and

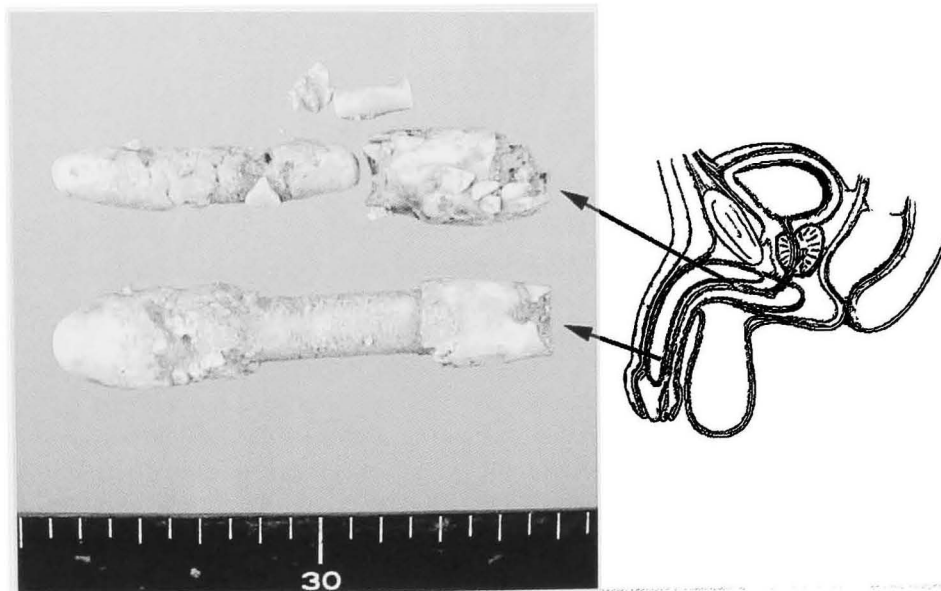
calibrated the urethral defect.

The buccal mucosa free graft was 3.5 cm long and 1.2 cm wide, and was harvested from the left side. It was cut at the sublamina layer and prepared on the bench to have a suitable thin graft. The defective urethra was isolated from the corpora and the graft was placed over the defect and fixed with interrupted suture as ventral onlay (Fig. 3). After the urethro-cutaneo fistula was resected and closed, a skin flap was designed to cover the skin defect around the reconstructed urethra.

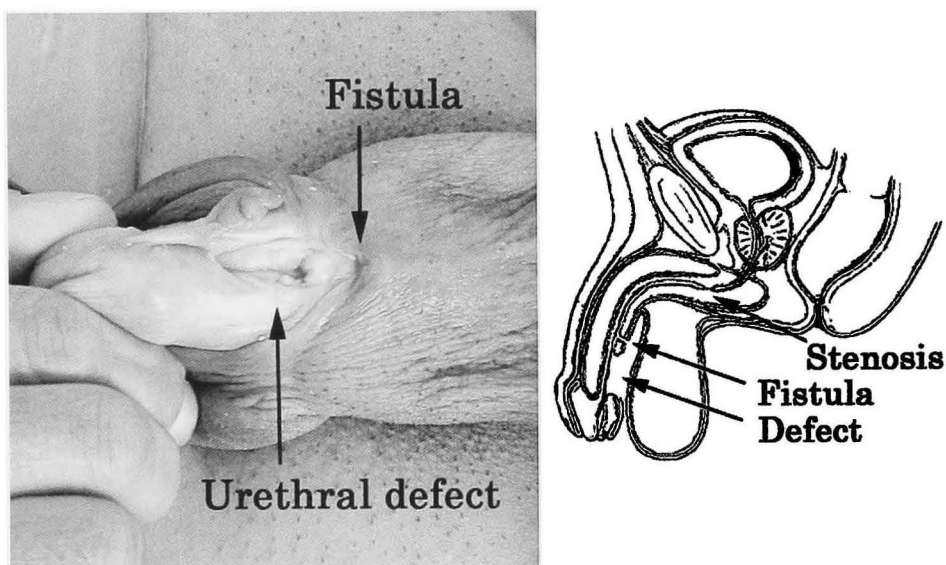
The whole procedure was performed in 309 minutes with a 55 ml blood loss. A transurethral catheter was indwelt and suprapubic drainage maintained for 3 and 15 days, respectively. The patient could achieve good voiding and no complication was seen during the 18-month follow up (Fig. 4)

### DISCUSSION

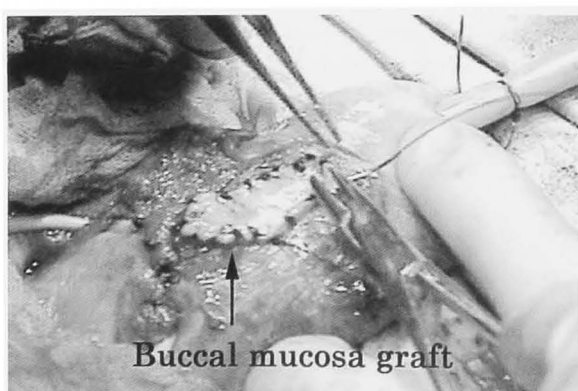
In case of urethroplasty, several kinds of grafts are used as an effective option for urethral reconstruction. These grafts have peculiar characteristics and all of them have both advantages and disadvantages. One of the commonly used grafts in genitourinary reconstructive surgery is the split-thickness skin graft. It has favorable vascular characteristics but tends to contract and becomes brittle when mature. A full-thickness skin graft tends to have more fastidious vascular characteristics but does not contract as much and is more durable when mature. Besides, in the case of a genital full-thickness skin graft, the mass is usually large compared to that of extragenital skin, which makes the graft more fastidious<sup>1)</sup>. In the case of a buccal mucosa graft, there is a panlamina plexus, which allows us to harvest a thin graft, with a sufficient amount of deep lamina to preserve the physical characteristics<sup>1)</sup>.



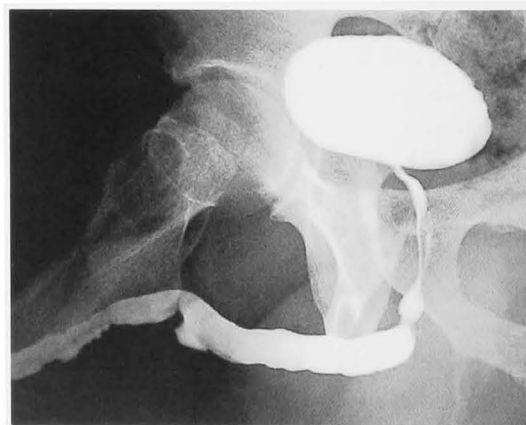**Fig. 1.** Foreign bodies and their locations. One cylindrical foreign body is located in the bulbous urethra and the other in the pendulous penile urethra.



**Fig. 2.** Photograph of urethral injuries and their schema. The urethral defect in the pendulous portion, the urethro-cutaneo fistula and the urethral stricture of bulbous portion are shown.



**Fig. 3.** The intra-operative view. A buccal mucosa graft was used to cover the urethral defect and it was fixed with interrupted suture as a ventral onlay.



**Fig. 4.** Retrograde urethrogram. A retrograde urethrogram, which performed 10 months postoperatively, shows proper urethral construction without any stricture.

In our patient we could use a thin graft, so that the total graft mass was small and did not affect the graft blood circulation; besides it enabled us to easily reconstruct the urethra. The buccal mucosa grafts was easy to harvest, and healing of the donor site was uncomplicated.

Because of its histological characteristics, the buccal mucosa graft is considered to have optimal vascular characteristics for urethral reconstruction. Actually, the majority of the reports about buccal mucosa grafts has described its usefulness in urethroplasty<sup>2-6)</sup> On the other hand few reports have referred to the superiority of a penile skin graft<sup>7,8)</sup>. The reason for the difference of the results is not clear. However, in many cases which showed excellent results, the buccal mucosa was used as a ventral onlay graft<sup>5,6)</sup>

However, in the case of repair of hypospadias in children and/or when buccal mucosa was used as a tube graft, the results were not always satisfactory<sup>7,8)</sup>.

In our patient we used a buccal mucosa graft as a ventral onlay and obtained favorable results without any complications; besides no urethral dilation or instrumentation was subsequently required.

In our experience, buccal mucosa is a useful source of urethral grafting material and excellent results can be expected even in the case of a complicated urethral injury.

#### REFERENCES

- 1) Jordan GH and Schlossberg SM : Surgery of the penis and urethra. In : Campbell's Urology. Edited by Walsh PC, Retik AB, Vaughan ED Jr, et al. 8th ed, pp 3886-3954, Elsevier Science, Philadelphia, 2002
- 2) Pansadoro V, Emiliozzi P, Gaffi M, et al. : Buccal mucosa urethroplasty in the treatment of bulbar urethral strictures. *Urology* **61** : 1008-1010, 2003
- 3) Kropfl D, Tucak A, Prlic D, et al. : Using buccal mucosa for urethral reconstruction in primary and re-operative surgery. *Eur Urol* **34** : 216-220, 1998
- 4) Morey AF and McAninch JW : When and how to use buccal mucosal grafts in adult bulbar urethroplasty. *Urology* **48** : 194-198, 1996
- 5) Kane CJ, Tarman GJ, Summerton DJ, et al. : Multi-institutional experience with buccal mucosa onlay urethroplasty for bulbar urethral reconstruction. *J Urol* **167** : 1314-1317, 2002
- 6) Pansadoro V, Emiliozzi P, Gaffi M, et al. : Buccal mucosa urethroplasty for the treatment of bulbar urethral strictures. *J Urol* **161** : 1501-1503, 1999
- 7) Hensle TW, Kearney MC and Bingham JB : Buccal mucosa grafts for hypospadias surgery : long-term results. *J Urol* **168** : 1734-1737, 2002
- 8) Weinberg G, Williot PE and Leonard MP : The utility of buccal mucosa graft in salvage urethroplasty. *Can J Urol* **9** : 1641-1645, 2002

(Received on October 21, 2004)  
(Accepted on December 10, 2004)

1) Jordan GH and Schlossberg SM : Surgery of the

## 和文抄録

## 外傷性尿道損傷に対し口腔粘膜グラフトを用いて再建した症例

早川 邦弘, 林 英理, 畠 亮, 外木 守雄

東京歯科大学市川総合病院泌尿器科

52歳, 男性. 自慰行為による異物挿入での尿道損傷で当院受診. 尿溢流とそれに伴う感染により陰茎は約1.5倍に腫脹, 自潰していた. 異物除去とデブリードマンを施行. その後, 狭窄となった部に対して内尿道切開を施行. 感染の消失を確認後に尿道と陰茎の再建を行った. 遊離皮弁として口腔粘膜を摘出し, パッチ

を当てるように吸収糸による結節縫合で尿道欠損部に補填した. 患者は良好な排尿が確保され, 現在まで合併症を認めていない. 口腔粘膜は外傷性尿道損傷に対しても有用な素材であり, 尿道再建は良好な結果を得ると考えられた.

(泌尿紀要 51: 343-346, 2005)