

Title	Urethral stent (Angiomed-Memotherm) implantation in high-risk patients with urinary retention
Author(s)	Uchikoba, Takushi; Horiuchi, Kazutaka; Satoh, Mitsuhiro; Oka, Fumiatsu; Saitoh, Yuka; Tsuboi, Narumi; Nishimura, Taiji
Citation	泌尿器科紀要 (2005), 51(4): 235-239
Issue Date	2005-04
URL	http://hdl.handle.net/2433/113598
Right	
Type	Departmental Bulletin Paper
Textversion	publisher

URETHRAL STENT (ANGIOMED-MEMOTHERM®) IMPLANTATION IN HIGH-RISK PATIENTS WITH URINARY RETENTION

Takushi UCHIKOBA^{1,2}, Kazutaka HORIUCHI¹, Mitsuhiro SATOH¹, Fumiatsu OKA¹,
Yuka SAITOH², Narumi TSUBOI² and Taiji NISHIMURA³

¹The Department of Urology, Nippon Medical School Second Hospital

²The Department of Urology, Nippon Medical School Chiba Hokusō Hospital

³The Department of Urology, Nippon Medical School

Transurethral resection of the prostate (TUR-P) has been established as the golden standard for the treatment of urinary retention in patients with benign prostatic hyperplasia (BPH). However, TUR-P is not performed on patients with certain high-risk complications. We have obtained favorable results using urethral stent (Angiomed-Memotherm®) implantation to treat high-risk urinary retention patients. Here, we review the results obtained on 15 patients treated using this procedure. Two patients experienced recurrent urinary retention; in one patient, the stent had to be removed due to stone formation; in the remaining 12 patients, urination was favorable after stent implantation. Also, urethral stent implantation was found to be useful in 4 of the 7 patients with neurogenic bladder (rather than BPH) as the underlying disease. The present technique is convenient and noninvasive, and we strongly believe that it can improve the patient's quality of life (QOL) by facilitating urination in high-risk patients who would otherwise require urethral catheterization.

(Hinyokika Kyo 51 : 235–239, 2005)

Key words : Urethral stent, Urinary retention, High-risk patients

INTRODUCTION

Benign prostatic hyperplasia (BPH) is one of the main reasons for the voiding dysfunction in men. Transurethral resection of the prostate (TUR-P) is performed in cases of BPH in which drug therapy is ineffective. However, in elderly patients or patients with high-risk complications such as heart disease or neuropathy, surgery is not always feasible. When such high-risk patients have urinary retention, urethral catheterization or clean intermittent catheterization (CIC) is generally required. However, catheterization not only increases the risk of urinary tract infection, but also markedly lowers the patient's quality of life (QOL).

Urethral stenting is reportedly as effective as TUR-P¹⁾. We have obtained favorable results from implantation of a permanent urethral stent (Angiomed-Memotherm®) in high-risk patients with urinary retention. In the present study, we examined the results of treatment of such patients by urethral stenting using the Memotherm stent.

SUBJECTS AND METHODS

The subjects were 15 patients in whom the Memotherm stent (Angiomed, Karlsruhe, Germany) was implanted between April 2001 and December 2003 at the Urology Department of the Nippon Medical School Chiba Hokusō Hospital or the Nippon Medical School Second Hospital. The average age of these patients was 71.7 years (range, 56

to 82 years). Table 1 shows the underlying disease and complications of all 15 patients.

In all patients, urethral stent implantation was performed on an outpatient basis. Thirty minutes before the procedure, a non-steroidal antiinflammatory drug (NSAID) suppository was administered, and 10 minutes before the procedure, 10 ml of xylocaine jelly, a surface anesthetic, was injected into the urethra. The length of the prostatic urethra, from the bladder neck to the caruncle, was measured using a cystoscope before stent implantation. The stent that was 5 mm shorter than the prostatic urethra was implanted using a special delivery system (Fig. 1) equipped with a 0° urethroscope.

After stent implantation, NSAID was administered for prevention of pain to these patients, and they were made to carry the card, in which the possible indwelling catheter size (16 Fr for smaller) was written in preparation for the case when urinary retention would occur.

In all patients who could void on their own six months after the stent implantation, we documented International Prostate Symptom Score (IPSS), urinary flow and postvoid residual urine (PVR), and we confirmed the complete epithelialization of the stent under urethroscope.

RESULTS

Immediately after stent implantation, discomfort of the prostatic urethra and urinary incontinence were observed, but these conditions were alleviated by an

Table 1. Clinical course of all patients

Case	Age	Underlying disease	Complications	Size (mm)	IPSS (6M)	Q (6M) max (ave) (ml/sec)	PVR (6M) (ml)	Clinical course following stenting	Period (M)
1	78	BPH	HT, Asthma	20	2	18.0 (11.2)	0	Good	36
2	56	NB	Spondylitis	15	6	25.0 (9.5)	0	Good	35
3	64	NB, BPH	Spondylitis	20	3	10.5 (5.5)	50	Removed due to stone formation	13
4	74	BPH	Lung Ca.	25				Died of underlying disease	6
5	66	NB	C. infarction	20				Urinary retention	6
6	80	BPH	C. infarction	15	16	11.2 (6.2)	60	Good	25
7	82	BPH	C. infarction	30	1	22.8 (11.4)	0	Good	24
8	73	NB	C. infarction	15				Urinary retention	3
9	75	BPH	Lung Ca.	40				Died of underlying disease	3
10	72	NB	C. infarction	35	1	24.0 (11.2)	30	Good	21
11	60	BPH	C. infarction	30	2	25.4 (12.0)	0	Good	22
12	78	NB, BPH	DM	55	2	8.8 (3.9)	30	Good	20
13	70	BPH	Puncreus Ca.	30	1	20.2 (11.0)	0	Good	20
14	80	BPH	Perkinsonism	35	1	16.0 (8.0)	0	Good	20
15	67	NB, BPH	C. infarction	60	2	10.5 (6.4)	20	Good	6

BPH: benign prostatic hyperplasia, NB: neurogenic bladder, HT: hypertension, Ca.: cancer, C. infarction: Cerebral infarction, DM: diabetes mellitus, Qmax: maximal flow rate, Qave: average flow rate, PVR: postvoid residual urine.




Fig. 1. The delivery system for the Angiomed-Memotherm stent. The delivery system is attached to a urethroscope, and the lever is manipulated to push out the stent and position it at the desired location. Since it is knitted of a single wire, the stent can be removed easily by pulling the pin portion, the end of the stent under a urethroscope.

NSAID suppository and anticholinergic agent, respectively. Table 1 shows the clinical course following stent implantation for all patients. Two patients died of complications from malignant cancer within six months after stent implantation. Two other patients had recurrent urinary retention within six months after stent implantation, and subsequently underwent stent removal and urinary catheterization. There was neither bleeding nor pain during and after the stent removal operation.

For the 11 patients who could urinate on their own six months after stent implantation, quantitative data was as follows: average IPSS was 3.4 points (range, 1 to 16 points); mean average flow rate (Qave) was 8.8 ml/sec (range, 3.9 to 12.0 ml/sec); mean maximal flow rate (Qmax) was 17.5 ml/sec (range, 8.8 to 25.4 ml/sec); and mean average PVR was 17.3 ml (range, 0 to 60 ml). In one of those 11 patients (case 3, Table 1), the stent was removed due to stone formation 13 months after stent implantation, but the remaining

ten patients had been able to urinate on their own for an average of 21.9 months after stent implantation (range, 6 to 36 months).

DISCUSSION

When patients with BPH experience voiding dysfunction that is unresponsive to drug therapy, various non-surgical techniques including thermotherapy and balloon dilatation are available. Another useful non-surgical technique is urethral stenting, which is reportedly as effective as TUR-P^{1,2)}. Urethral stenting was first introduced in 1980. The stent developed by Fabian et al. was prone to displacement, infection and stone formation, and it needed to be replaced every six months³⁾. Improvements in materials and shapes led to the development of a permanent stent by Chapple et al. in 1990, which made it possible to establish urethral stenting as an ideal treatment for patients with high operative risk due to severe complications¹⁾

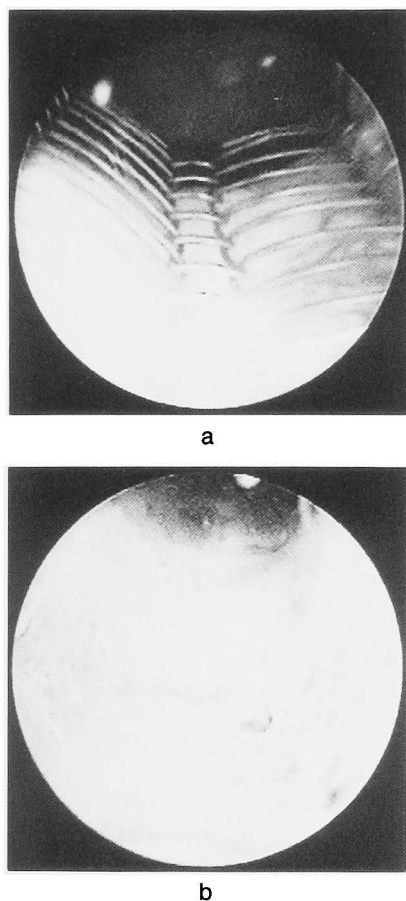


Fig. 2. a : Urethroscopic findings immediately after stent implantation. b : At three months after implantation, the stent had properly expanded, and epithelialization was observed.

The Angiomed Memotherm stent used to treat the present subjects is a permanent stent that consists of a mesh tube made of nitinol, a shape memory alloy consisting of nickel and titanium. After implantation, its diameter increases from 21 to 42 Fr as it warms to body temperature⁵⁾ (Fig. 2a).

There have been several reports of the use of lumbar spinal anesthesia for urethral stent implantation⁵⁻⁷⁾ However, at our institution, stent implantation has been performed with administration of a NSAID suppository and injection of a surface anesthetic into the urethra, without causing much pain to the patients. NSAID suppositories were effective in alleviating the discomfort caused by stent expansion or stimulation. Also, the time required to implant the stent after inserting the urethroscope was less than 15 minutes for all patients (data not shown). Two of the 15 patients experienced recurrent urinary retention and had neurogenic bladder (NB) resulting from the aftereffects of cerebral infarction. However, four of the seven patients in whom NB was believed to be the cause of urinary disturbance were able to urinate on their own (Table 1).

Gesenberg et al. stated that patients with reduced detrusor muscle strength should not be excluded from

urethral stent implantation because a urethral stent can minimize the resistance of the lower urinary tract⁵⁾ The present findings also indicate that urethral stent implantation is meaningful in cases of voiding dysfunction caused by NB.

In one of the present patients (case 3, Table 1), stone formation around the stent was confirmed 13 months after stent implantation. Gesenberg et al. reported stone formation in the area protruding into the bladder in 4 of 123 patients who underwent Memotherm stent implantation⁵⁾ Stone formation around a foreign object in the bladder is a common occurrence, and it is necessary to correct or remove a displaced urethral stent as soon as possible to prevent stone formation⁸⁾

Two of the present patients had terminal lung cancer as the underlying disease (Table 1, cases 4 and 9). After stent implantation, these two patients died of lung cancer, but urination was favorable. Stent implantation was performed on these two patients, despite their poor vital prognoses, because they did not want a urethral catheter. Urethral catheters are extremely unpopular with patients. Consequently, even in patients with terminal cancer, we believe that a urethral stent implantation is indicated if patients strongly desire the ability to urinate on their own.

In patients with urinary retention, urethral stent implantation can easily be performed with minimal invasiveness, and it is a useful procedure for improving the QOL of high-risk patients with severe complications.

REFERENCES

- 1) Maru N, Shitara T, Yamashita H, et al. : Experience with the Memotherm stent in high-risk urinary retention patients. *Jpn J Urol* **94** : 481-486, 2003
- 2) Schöps W and Kierfeld G : Die urologische Spirale und ihr klinischer Stellenwert. *Urologe B* **27** : 308-310, 1987
- 3) Fabian KM : Der intraprostatiche "Partielle Katheter" (urologische Spirale). *Urologe A* **19** : 236-238, 1980
- 4) Chapple C R, Milroy EJ and Rickards D : Permanently implanted urethral stent for prostatic obstruction in the unfit patient. preliminary report. *Br J Urol* **66** : 58-65, 1990
- 5) Gesenberg A and Sintermann R : Management of benign prostatic hyperplasia in high risk patients : long-term experience with the Memotherm stent. *J Urol* **160** : 72-76, 1998
- 6) Noda Y, Ujike T, Oka D, et al. : Urethral stent (Memotherm) for the treatment of benign prostatic hyperplasia. *Acta Urol Jpn* **49** : 645-647, 2003
- 7) Arakawa S, Miyazaki S, Okada H, et al. : Angiomed Memotherm for benign prostatic hyperplasia. *Jpn J Urol Surg* **12** : 263-268, 1999

- 8) Namba Y, Kiuchi H, Fujimoto M, et al. : Vesical stone formation around migrating urethral stent. *Rinsho Hinyokika* **56** : 67-69, 2002

(Received on August 18, 2004)
(Accepted on November 18, 2004)

和文抄録

尿閉を来たしたハイリスク患者に対する尿道ステント
(アンジオメッド メモサーム) の使用経験内木場拓史^{1,2}, 堀内 和孝¹, 佐藤 三洋¹, 岡 史篤¹
齊藤 友香², 坪井 成美², 西村 泰司³¹日本医科大学付属第二病院泌尿器科,²日本医科大学付属千葉北総病院泌尿器科, ³日本医科大学泌尿器科

尿閉を来たした前立腺肥大症の患者に対して TUR-P は golden standerd として確立している治療法である。ところがハイリスクな合併症を有するがために手術の適応から除外される患者も少なくない。

われわれは、尿閉を来たしたハイリスク患者に対して、尿道ステント (アンジオメッド メモサーム) 留置を試みて、良好な結果をえた。

対象症例15例のうち、2名は再度尿閉を来たし、1名はステントへの結石付着が原因でステントを抜去せ

ざるをえなかったが、残る12名はステント留置後から良好な排尿状態を保持することができた。また、BPH だけでなく、原疾患が NGB と思われる症例にも効果を期待できる (4名/7名) ことがわかった。

非侵襲的で簡便なこの手技は、本来尿道カテーテルを留置されるべきハイリスク患者に自排尿を促せる、すなわち QOL を高めることのできる優れた手技であると確信している。

(泌尿器科紀要 51 : 235-239, 2005)