

Title	Malignant pheochromocytoma of the urinary bladder
Author(s)	Segawa, Naoki; Osafune, Takashi
Citation	泌尿器科紀要 (2005), 51(4): 291-296
Issue Date	2005-04
URL	http://hdl.handle.net/2433/113586
Right	
Type	Departmental Bulletin Paper
Textversion	publisher

MALIGNANT PHEOCHROMOCYTOMA OF THE URINARY BLADDER

Naoki SEGAWA and Takashi OSAFUNE
The Department of Urology, Otsu Red Cross Hospital

A case of malignant pheochromocytoma of the urinary bladder is presented. A 54-year-old woman visited our hospital for screening and was found to have an abnormal mass in the bladder on ultrasonography. The patient was not hypertensive. Cystoscopy revealed a broad-based, small fingertip-sized, nonpapillary tumor on the posterior wall of the urinary bladder. Transurethral resection (TUR) was performed without suspicion of pheochromocytoma because of her well-controlled blood pressure and lack of characteristic symptoms. Transient elevation of systolic blood pressure to 240 mmHg occurred during resection of the tumor. Radical resection was therefore not possible. The serum norepinephrine level was elevated postoperatively. Pathologic examination revealed a malignant pheochromocytoma. On January 30, 2003, partial cystectomy of the residual tumor and pelvic lymphadenectomy were performed. She has had no clinical sign of recurrence for 1 year after the second operation.

(Hinyokika Kyo 51 : 291–296, 2005)

Key words : Pheochromocytoma, Bladder tumor, Urinary bladder

INTRODUCTION

Pheochromocytomas are neoplasms arising from chromaffin tissues of the sympathetic nervous system. Primary involvement of the urinary bladder is rare, and accounts for less than 0.06% of all vesical neoplasms¹⁾ and less than 1% of all pheochromocytomas²⁾. Pheochromocytomas are rarely malignant. We present a case of malignant pheochromocytoma of the urinary bladder

CASE REPORT

A 54-year-old woman was admitted to the Department of Internal Medicine in our hospital for screening on December 10, 2002. A urinary bladder tumor was incidentally detected on abdominal ultrasonography. It was a 1.0×1.0 cm well-defined, solid echogenic mass. She was referred to the Department of Urology. She was 160 cm tall and weighed 57.5 kg. Her pulse was 72 beats/min. Her blood pressure was 120/80 mmHg. Findings of physical examination were unremarkable. She had no history of hypertension, and was taking no medications. Laboratory data, including complete blood count, blood urea nitrogen, creatinine, electrolytes and urinalysis, were normal. Urine cytology yielded a class II result. Blood noradrenaline and adrenaline levels were not measured since the tumor had not been diagnosed as a pheochromocytoma of the urinary bladder prior to surgery. Cystoscopic examination revealed a 1 cm broad-based, non-papillary submucosal tumor in the posterior wall of the bladder. The surface was covered by nearly normal mucosa. Pelvic magnetic resonance imaging (MRI) revealed a demarcated

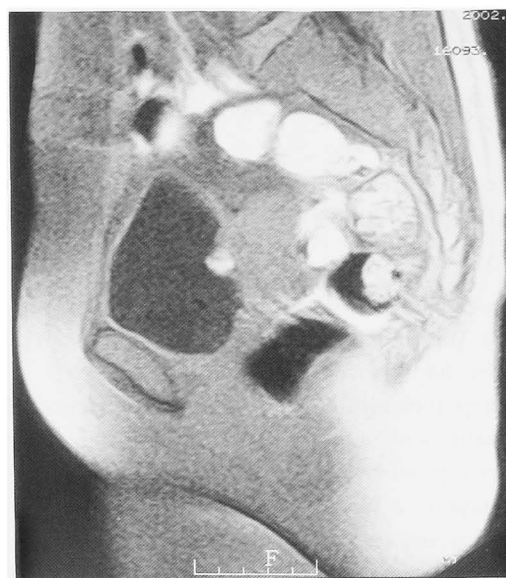

Fig. 1. MRI (sagittal plane) showed a demarcated mass with a high signal intensity on T1-weighted images.

mass with high signal intensity on both T1- and T2-weighted images (Fig. 1). The tumor had clear margins. No extravescicular invasion was observed. Transurethral resection (TUR) was performed for differential diagnosis on December 17, 2002. The patient's systolic blood pressure abruptly increased to 240 mmHg at the beginning of TUR. Complete TUR was considered impossible and biopsy alone was performed. On the day after operation, the serum noradrenaline level was elevated (1,165 pg/ml, normal range: 100–450 pg/ml). Adrenaline and dopamine levels were normal. ¹³¹I-meta-iodobenzylguanidine scintigraphy revealed no uptake of

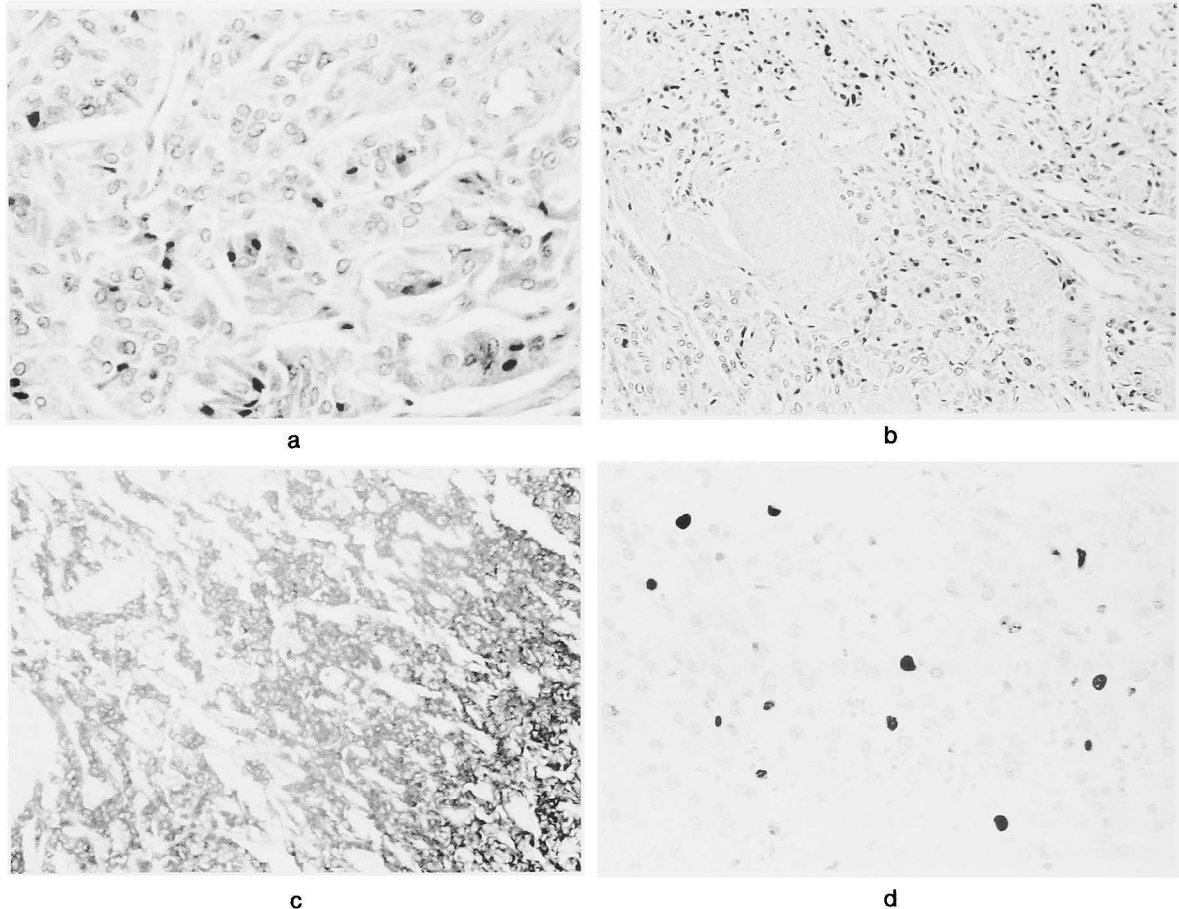


Fig. 2. Histopathological findings of the tumor. (a) HE stain ($\times 400$), (b) HE stain ($\times 200$), (c) Immunohistochemical staining is positive to chromogranin A ($\times 400$), (d) Positive reactivity for MIB-1 is found in 7% of the tumor cells ($\times 400$).

isotope in the urinary bladder. No extravascular uptake was noted. A technetium bone scan was negative for metastasis.

Histopathologically, the tumor cells had granular cytoplasm with a moderately pleomorphic nucleus and were proliferating abundantly to form a spindle-like shape in a piriform honeycomb form (Fig. 2a). They presented the characteristic features of pheochromocytoma. The major portion of the tumor was invading the muscular layer (Fig. 2b). Immunohistologically, the tumor cells were positive for chromogranin A and MIB-1 (Fig. 2c, d). Based on these findings, the tumor was diagnosed as a primary malignant pheochromocytoma of the urinary bladder. The amount of tumor remaining in the deep muscle layer suggested that additional surgical treatment was needed. In preparation for removal of the pheochromocytoma, the patient was treated with a 10-day course of α blockade and intravenous hydration in the hospital. She had no cardiac aberrations and no β blockade was necessary. Partial cystectomy including the mass and limited bilateral pelvic lymphadenectomy were performed under general anesthesia. The incision was circumscribed with a 1-cm margin. Since no extravascular invasion was observed, separation of

the bladder was relatively easy. The surgical margin was free of tumor. No pelvic lymphadenopathy was observed. No fluctuation of blood pressure was noted during the surgical procedures. Postoperatively, her blood pressure was maintained with intravascular volume expansion. Gross-pathologic examination revealed a well-circumscribed, white-yellowish, homogeneous mass within the bladder wall. Final pathologic examination also revealed malignant pheochromocytoma. The surgical margins were free of tumor, as were the lymph nodes. The serum noradrenaline level was normalized and remained normal a month after operation. Her course has remained uneventful up to one year postoperatively without any signs of recurrence or metastasis.

DISCUSSION

It is difficult to judge preoperatively whether a pheochromocytoma is malignant or not based on preoperative morphological features, but the grounds for malignancy include metastasis to the associated lymph nodes and distant metastasis. Histological findings of malignancy include tumor cell necrosis and vascular invasion, absence of hyaline globes within the tumor cells, mitotic figures and cytological

Table 1. Characteristics of patients with malignant pheochromocytoma of the urinary bladder in Japan

Case no.	Authors	Age/gender	Macro-hematuria	Secondary hypertension	Miction-attack	Location of tumor	Preop. diag.	Surgical method	Prognosis	Length of follow-up (months)	Source
1	Katsume (1961)	49/F	-	+	+	Dome	+	Partial cystectomy	Dead of distant metastasis	7	Gan no rinsho 7 : 395-398
2	Tazaki (1963)	66/M	+	-	-	Dome	-	Partial cystectomy	-	-	Nihon hinyokika gakkai zassi 54 : 561
3	Shinbo (1970)	17/F	-	+	-	-	-	Partial cystectomy	ANED	24	Nihon rinsho 28 : 2507-2516
4	Imanaka (1982)	15/F	-	+	-	Posterior, lateral wall	+	Partial cystectomy	ANED	8	Nishinohon J Urol 44 : 315-320
5	Namima (1987)	22/M	+	-	-	Trigone, lateral wall	-	Partial cystectomy	-	-	Igaku no ayumi 142 : 387-391
6	Nagata (1988)	63/M	+	-	-	-	-	Total cystectomy	ANED	-	Nihon hinyokika gakkai zassi 79 : 573
7	Mizuzeki (1991)	29/M	+	-	-	Posterior wall	+	Partial cystectomy	ANED	12	Gan no rinsho 37 : 377-384
8	Takeda (1991)	27/M	-	+	+	Vesical neck, lateral wall	+	Total cystectomy	Distant metastasis	35	Nihon hinyokika gakkai zassi 82 : 826-829
9	Makino (1991)	31/M	+	-	+	Vesical neck	-	Total cystectomy	ANED	16	Acta Urol Jpn 37 : 537-540
10	Kawai (1993)	47/F	+	-	+	Posterior wall	-	Partial cystectomy	Dead of distant metastasis	6	Nishinohon J Urol 55 : 1726-1729
11	Katabami (1994)	28/F	-	-	+	Trigone, vesical neck	+	Total cystectomy	Dead of distant metastasis	-	Nihon naika gakkai zassi 83 : 110-112
12	Hiramoto (1998)	63/M	+	-	-	Lateral wall	-	Total cystectomy	Distant metastasis	120	Nishinohon J Urol 60 : 772-775
13	Present case	54/F	-	-	-	Posterior wall	-	Partial cystectomy	ANED	12	

ANED: alive with no evidence of disease.

anomalies³⁾ Immunohistochemical markers of cell proliferation have been used to evaluate tumor cell populations. Our case did not demonstrate any clinical data that suggested malignancy. The MIB-1 labeling index may be a reliable indicator of malignant behavior. The most commonly studied proliferative marker is Ki-67. MIB-1, a monoclonal antibody to Ki-67, used in formalin-fixed, paraffin embedded sections, recognizes a nuclear antigen present in all phases of the cell cycle except G₀⁴⁾. Recently, several studies on prognostic markers of pheochromocytoma and paraganglioma suggested that MIB-1 labeling index was useful for evaluation of malignant potential^{5,6)}. Van-der-Harst et al. reported that in their 110 cases, 50% of which were malignant, none of the benign pheochromocytomas exhibited MIB-1 indices >2.5%. In half of the metastatic pheochromocytomas, MIB-1 indices were >5%⁵⁾. In other words, MIB-1 expression, when present, was indicative of malignant behavior⁴⁾. We diagnosed the present case as malignant based on the existence of muscular invasion and MIB-1 expression. Similar histologic findings have been obtained in other cases of malignancy⁷⁾. The expression of MIB-1 was relatively high (7%) compared with other cases of malignancy⁴⁻⁶⁾. Histologic criteria in malignant pheochromocytoma of the bladder has not been proposed. However, we thought that cases with distant metastasis were clinically malignant and this case was histologically malignant.

In adults, pheochromocytomas are extraadrenal in 15% and multicentric in 15–24% of cases⁸⁾. Das et al. reviewed 100 cases of bladder pheochromocytoma reported up to 1983⁹⁾. Of these, pheochromocytoma was nonfunctional in 17% and malignant in about 15% of the cases. The characteristic clinical symptoms included hypertension in 65%, macroscopic hematuria in 58% and micturitional attack in 46% of the cases. Resection of an unsuspected pheochromocytoma sometimes produced a sudden rise in blood pressure, as occurred in our case. The most common sites of occurrence are the apex and lateral wall. The tumors are mostly solitary. As they arise in the submucosal muscle layer, it is difficult to obtain complete resection with TUR.

The MRI of bladder pheochromocytomas shows an intramural tumor with intermediate signal intensity on T1-weighted images and high signal intensity on T2-weighted images, but this is nonspecific and overlaps with the findings of other intramural bladder tumors¹⁰⁾. In our case, MRI showed an almost characteristic appearance. Our patient with pheochromocytoma of the urinary bladder had no history of hypertension and no characteristic symptoms related to micturition. Thus, pheochromocytoma was not suspected until a serious hypertensive crisis occurred during the TUR procedure. Pheochro-

mocytoma should be suspected in cases of intramural bladder tumor. We do not recommend TUR alone for treatment of pheochromocytoma of the urinary bladder, because of the possibility of serious hypertensive crisis and the difficulty of complete resection with TUR alone.

The treatment of pheochromocytoma of the bladder is surgical excision. Open surgery permits complete resection and a more thorough examination of the surrounding structures and regional lymph nodes. Most of the reported cases were removed by partial cystectomy. Total cystectomy with lymph node dissection is performed when the lesion is clearly malignant. In a review of 100 cases of pheochromocytoma of the urinary bladder, Das et al. also recommended pelvic lymph node dissection in all cases of bladder pheochromocytoma to exclude metastatic disease. While most cases were treated with partial cystectomy, 7 were treated with radical cystectomy because of confirmed metastatic lymphadenopathy, and 7 with TUR⁹⁾. Fifteen patients were reported to have malignant pheochromocytoma. The pathological evidence of malignancy remains unconfirmed.

Only a few more than 20 malignant cases excluding those in Japan have been previously reported¹¹⁾. We calculated the number of Japanese cases of malignant pheochromocytoma of the urinary bladder. Since Katsume et al. described the first case of malignant pheochromocytoma in Japan, the patient described in the present report is, we believe, the 13th malignant case in Japan (Table 1). This disease occurs over a wide range of ages extending from 15 to 66 years. The characteristic clinical symptoms are secondary hypertension in 31%, macrohematuria in 54% and miction-attack in 38% of cases. The mortality rate has not been particularly high, with 3 deaths among 13 cases.

In conclusion, pheochromocytoma of the urinary bladder is rare. Long-term follow-up with monitoring of blood pressure and signs and symptoms as well as catecholamine assays is essential since it is not possible histologically to differentiate benign and malignant pheochromocytomas⁹⁾. We maintain an expectant attitude by performing catecholamine determinations monthly and imaging and scintigraphic studies every 6 months to avoid any delay in the case of relapse.

REFERENCES

- 1) Leestma JE and Price EB Jr: Paraganglioma of the urinary bladder. *Cancer* **28**: 1063–1073, 1971
- 2) Heiken JP, McClennan BL and Distantis DJ: Nontransitional cell tumors of the bladder. In: *Radiology*. Edited by Taveras JM and Ferrucci JT, pp 1–7, Lippincott, Philadelphia, 1994
- 3) Linnolla RI, Keiser HR, Steinberg SM, et al.:

- Histopathology of benign versus malignant sympathoadrenal paragangliomas: clinicopathological study of 120 cases including unusual histologic features. *Hum Pathol* **21**: 1168–1180, 1990
- 4) Brown HM, Komorowski RA, Wilson SD, et al.: Predicting metastasis of pheochromocytomas using DNA flow cytometry and immunohistochemical markers of cell proliferation. *Cancer* **86**: 1583–1589, 1999
 - 5) Van-der-Harst E, Bruining HA, Jaap-Bonjer H, et al.: Proliferative index in pheochromocytomas: does it predict the occurrence of metastases? *J Pathol* **191**: 175–180, 2000
 - 6) Nagura S, Katoh R, Kawaoi A, et al.: Immunohistochemical estimations of growth activity to predict biological behavior of pheochromocytomas. *Mod Pathol* **12**: 1107–1111, 1999
 - 7) Hiromoto Y, Fuji K, Inoue K, et al.: Malignant pheochromocytoma of the urinary bladder associated with renal cell cancer: a case report. *Nishinohon J Urol* **60**: 772–775, 1998
 - 8) Whalen RK, Althausen AF and Daniels GH: Extra-adrenal pheochromocytoma. *Urology* **147**: 1–10, 1992
 - 9) Das S, Bulusa NV and Lowe P: Primary vesical pheochromocytoma. *Urology* **21**: 20–25, 1983
 - 10) Warshawsky R, Bow SN, Waldbaum RS, et al.: Bladder pheochromocytoma with MR correlation. *J Comput Assist Tomogr* **13**: 714–716, 1989
 - 11) Piedrola G, Lopez E, Rueda MD, et al.: Malignant pheochromocytoma of the bladder: current controversies. *Eur Urol* **31**: 122–125, 1997

(Received on August 16, 2004)
(Accepted on December 10, 2004)

膀胱悪性褐色細胞腫の1例

瀬川 直樹*, 長船 崇

大津赤十字病院泌尿器科

症例は54歳, 女性. 当院の検診を受け, 超音波検査にて膀胱に異常腫瘤を指摘され, 泌尿器科を受診した. 膀胱鏡検査で膀胱後壁に小指頭大の非乳頭状広基性腫瘍を確認し, 経尿道的膀胱腫瘍切除術を施行した. 切除開始時, 収縮期血圧が 240 mmHg まで急激に上昇し, 切除続行は困難と判断し手術を中止した. 術後, 血清ノルアドレナリン濃度の上昇がみられた.

病理組織学的診断は悪性褐色細胞腫であった. 術前, 血圧は安定しており褐色細胞腫を疑わせる症状はなかった. 2003年1月30日, 膀胱部分切除術および骨盤内リンパ節郭清術を施行した. 術後1年を経過し, 再発の徴候はない.

(泌尿器科紀要 51 : 291-296, 2005)

* 現 . 静岡済生会総合病院泌尿器科