

Title	Reconstruction of posterior urethral disruption : tips for success from our experience and from a literature review
Author(s)	Kato, Haruaki; Kobayashi, Shinya; Kawakami, Masako; Inoue, Hiroo; Iijima, Kazuyoshi; Nishizawa, Osamu
Citation	泌尿器科紀要 (2004), 50(10): 729-735
Issue Date	2004-10
URL	<a href="http://hdl.handle.net/2433/113463">http://hdl.handle.net/2433/113463</a>
Right	
Type	Departmental Bulletin Paper
Textversion	publisher

# RECONSTRUCTION OF POSTERIOR URETHRAL DISRUPTION: TIPS FOR SUCCESS FROM OUR EXPERIENCE AND FROM A LITERATURE REVIEW

Haruaki KATO, Shinya KOBAYASHI, Masako KAWAKAMI,  
HIROO INOUE, Kazuyoshi IJIMA and Osamu NISHIZAWA  
*From the Department of Urology, Shinshu University School of Medicine*

Repair of a posterior urethral disruption associated with a pelvic fracture is a challenge for urologic surgeons. Here, we provide surgical and strategic tips to facilitate the delayed surgical repair of urethral distraction defects. Nine patients each with a traumatic posterior urethral distraction defect underwent delayed transperineal or transperineoabdominal bulboprostatic anastomosis. Four patients had previously undergone multiple procedures. Seven patients regained satisfactory urination without incontinence, although one other patient is suffering from incontinence. In one patient, urethral disruption occurred again after removal of the urethral catheter, and he is being managed by suprapubic catheter. In our experience, the key to success is to perform a true bulboprostatic mucosa-to-mucosa anastomosis without tension. For this purpose, a transperineoabdominal approach is of particular importance when the healthy mucosa of the prostatic apex cannot be revealed through a perineal approach due to dense fibrous scar or fractured bone. A partial pubectomy may be necessary according to the situation. By the transperineoabdominal approach, the scar tissue can be bypassed through a broad sub-pubic-arch tunnel, and a reliable anastomosis achieved.

(Acta Urol. Jpn. 50 : 729–735, 2004)

**Key words:** Urethra, Disruption, Pelvis, Fracture

## INTRODUCTION

The reconstruction of a posterior urethral disruption associated with a pelvic fracture requires significant expertise and surgical skill because of the difficult conditions and the variety of clinical situations encountered among individual patients. Many published articles on anastomotic urethroplasty for this injury originated from countries outside Japan<sup>1–5)</sup> and several surgeons with experienced hands have described their surgical technique, although this seems to involve a knack that is difficult to explain in words.

However, no report at all has come from Japan, perhaps implying that we are not familiar with this type of injury or its management. This being so, we thought it worthwhile to review the literature, to try to simplify the steps involved in the procedures, and to detail a strategy for obtaining satisfactory results.

In this paper, we take the procedures step by step, and on the basis of both our own experience and the report already in the literature we summarize the key points, and also the pitfalls we need to overcome for successful results. In this way, we hope to simplify the complicated procedures needed to perform a reliable bulboprostatic anastomosis, which we believe to be a key to success.

## METHODS

### *Patients*

Nine male patients (age range, from 17 to 78 years) each with a traumatic posterior urethral distraction defect associated with a pelvic fracture (single or multiple pubic bone fractures) underwent delayed bulboprostatic anastomotic urethroplasty. Each of them had a complicated history of associated injuries or multiple previous urologic surgeries (Table 1). Length of the defects measured on the combined cystourethrogram was varied and most of them were distracted. For the final urethroplasty, we used a transperineal approach in four patients, and a combined perineoabdominal approach in the other five. Each patient presented with a complete loss of the erectile function before operation. In two patients, preoperative cystography showed an open bladder neck.

### *Procedures*

#### 1) Transperineal approach

For this approach, we placed the patient in a low lithotomy or supine position. Extirpation of the cystostomy tract and a small cystostomy were performed through a suprapubic incision to facilitate manipulation from the bladder neck. Then, with the patient in a high lithotomy position an inverted U-shaped incision was made in the perineum. The

Table 1

Case No.	Age	Cause	Associated injury and treatment	Delay until repair	Previous procedures	Defect* (cm)
1	61	work A	rectal injury, colostomy	5 years	perineal urethroplasty repeated TUR & stent	2
2	34	work A	ileal perforation, bladder perforation	1 year	none	3
3	33	work A	perineal injury, rectal injury, TAE, colostomy	2 years	none	4
4	38	work A	pelvic abscess (MRSA), TAE	1 year	perineal urethroplasty	1
5	77	work A	ileal perforation	1 year	perineal urethroplasty	2.5
6	52	work A	none	1 year	repeated urethrotomy	1.5
7	17	traffic A	Femoral fracture	6 months	none	3
8	48	work A	Sacral fracture	5 months	none	3
9	78	work A	none	7 months	none	1

A: accident, TAE: transarterial embolization. \* Length of the defect was measured on combined cystourethrogram.

Table 2

Case No.	Final approach	Operating time	Blood loss (ml) (including urine)	Follow-up (months)	Results	Problems
1	T-PA	5 hr 21 min	1,000	15	good	none
2	T-P	3 hr 05 min	340	53	good	none
3	T-PA	4 hr 20 min	1,200	31	good	none
4	T-PA	5 hr 05 min	1,700	30	patent	incontinence
5	T-PA	6 hr 42 min	1,200	31	failed	cystostomy
6	T-P	2 hr 50 min	200	23	good	none
7	T-PA	4 hr 08 min	1,800	19	good	none
8	T-P	4 hr 22 min	1,400	3	good	none
9	T-P	3 hr 20 min	600	3	good	none

T-PA: transperineoabdominal, T-P: transperineal. None of the patients received homologous blood.

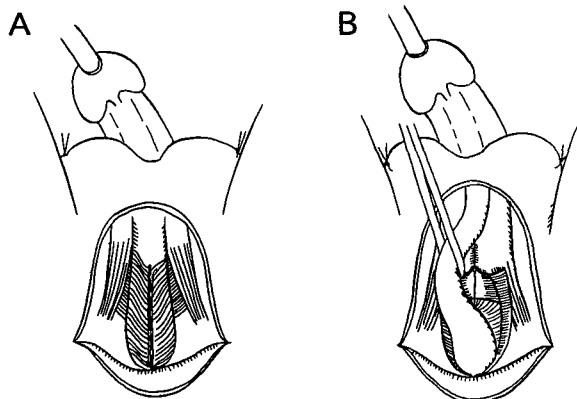


Fig. 1. A: Exposure of bulbar urethra is shown. Broken line indicates incision of bulbo-cavernosus muscle. B: The bulbar urethra is secured and mobilized.

bulbar urethra, which was exposed through a vertical incision of the bulbo-cavernosus muscle, was secured and circumferentially mobilized (Fig. 1). The membranous urethra was secured within the pubourethral space, and the remaining bulb was clamped and divided (Fig. 2). Turner-Warwick described a pubo-urethral space, at the entrance of the pelvic floor between the membranous urethra and the subpubic arch, into which a fingertip can be inserted<sup>1)</sup> In our experience, only the membranous

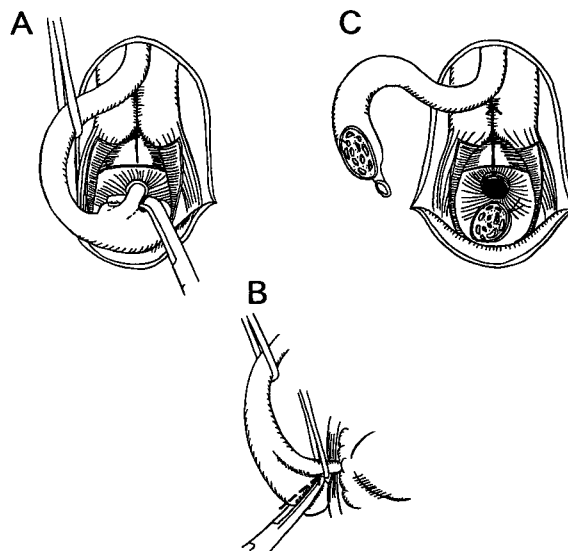


Fig. 2. A: The membranous urethra is secured at the pubo-urethral space by penetrating with a right-angle forceps. B: The remaining bulb is clamped and divided by means of a diathermy (broken line). C: The membranous urethra is dissected at the disruption site. The broken line indicates separation of the corporal bodies.

urethra can be secured at this level, and the remaining bulb tissue is clamped and divided to avoid

injury to the bulbar arteries. However, this space is sometimes obliterated due to scar tissue or the result of a previous operation, and then meticulous dissection of the bulbar urethra is required. The membranous urethra was further dissected until its mucosa was detached from the disruption site. Then, the bulbar urethra was further dissected distally at the level of the suspensory ligament, and the corporal bodies separated to create a space for exposure of the prostatic apex (Fig. 2). Next, an antegrade urethral metal sound was passed through the internal meatus.

If the stricture is short and the scar tissue around the prostatic apex is minimal, the tip of the sound can be felt at the space created in the perineum. The scar tissue now needs to be punched out and removed, and the sound can then penetrate into the perineal space. This tract can be gradually dilated by the introduction of a number of consecutive metal sounds antegradely, and the remaining scar tissue removed. Finally, a long nasal speculum can be introduced into the prostatic urethra from the perineal side, and its mucosal edge and the verumontanum need to be confirmed.

At this point, it was clear to us whether or not a simple perineal approach for bulboprostatic anastomosis was possible. If it was, the end of the bulbar urethra was spatulated on its dorsal side and a bulboprostatic anastomosis created using interrupted 4-0 vicryl sutures over a 16 Fr. catheter. To take stitches from the prostatic urethra, a J-shaped needle was employed, penetrating from the outside to the inside of the mucosa<sup>5)</sup>. It is of great importance not to compromise in the making of a complete mucosa-to-mucosa anastomosis. However, if the tip can hardly be felt or is felt in a different direction it is better to convert immediately to the transabdominal approach.

## 2) Transperineoabdominal approach

Among our cases, the simple transperineal approach described above was performed in only four patients. In the remaining five, the tip of the antegrade sound could not be felt at the space in the perineum due to a long defect with distraction that was replaced by dense fibrotic scar. A fractured pubic bone formed an obstacle for a simple transperineal approach in one case. In these five cases, we used an additional transabdominal approach in combination with the perineal approach.

In this procedure, a retropubic space was created with full separation of the bladder and prostate from the pubic bone, using a diathermy knife, until the prostatic apex was exposed. A lower midline incision was made and extended, and the retropubic space dissected down to around the prostatic-apex level. The prostatic apex buried in the scar can be identified by elevation of a tip of the sound inserted

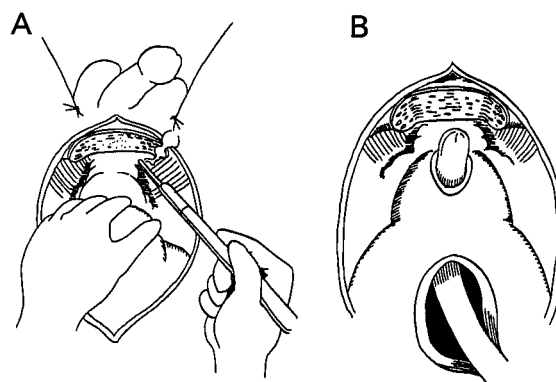


Fig. 3. A: A retropubic space is created using a diathermy. The prostate and bladder, with scar tissue, are separated from the pubic bone. A partial pubectomy is performed. B: The ventral aspect of the prostatic apex is vertically incised onto the tip of a metal sound.

from the internal meatus. Then, the ventral aspect of the healthy prostatic apex on the tip of the sound was vertically incised, and the verumontanum confirmed. The dissection should be close to the periosteum of the retropubis so as not to damage the bladder neck. It has been said that it is not necessary to worry about causing bleeding due to damage to the dorsal vein complex because much of this venous complex has been obliterated by thrombosis as a result of the original injury<sup>2)</sup>

However, it is difficult to perform both the prostatic incision and the later anastomotic procedure due to the limited space. Therefore, a partial pubectomy, in which the inferior aspect of the symphysis is resected toward the prostatic apex using an oscillating bone saw, facilitates these procedures (Fig. 3). Indeed, this was also true in our experience. A subsequent partial pubectomy effectively reveals the area of the prostatic apex, and it is of critical importance to resect the inferior aspect of the pubis toward the prostatic apex, not the superior aspect<sup>2)</sup>. After the partial pubectomy, the mucosal edge of the prostatic apex was taken with the aid of several stitches made using a 4-0 vicryl suture. Then, in order to pass the bulbar urethra into the pelvis a spacious tunnel inferior to the pubic arch (the subpubic arch tunnel) was created between the perineum and the prostatic apex. The creation of this tunnel is facilitated by the use of finger sensation from the two sides, and the tunnel then needs to be widened. The ventral spatulated bulbar urethra was then drawn into the pelvis, and a bulboprostatic anastomosis created over a 16 Fr catheter. In this way, the dense scar tissue around the prostatic apex can be circumvented when this approach is used (Fig. 4, 5).

After the bulboprostatic anastomosis had been made through either of the above approaches, the free

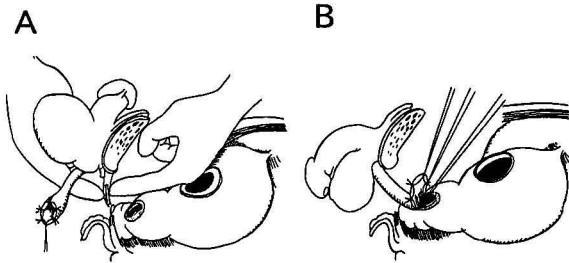


Fig. 4. A: Creation of a wide tunnel in the subpubic-arch area. The correct position is initially confirmed by finger sensation from the two sides. The tunnel is gradually enlarged by removing scar tissue together with thickened diaphragmatic tissue. B: The elastic bulbar urethra can be drawn straightly into the tunnel and anastomosed to the prostatic urethra.

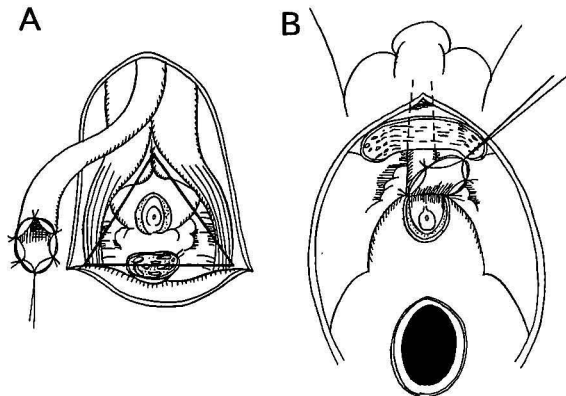


Fig. 5. A: From a perineal view, the newly created triangular tunnel is closely comparable to the urogenital triangle. B: Scar tissue below the level of the prostatic apex can be bypassed through this tunnel.

part of the bulbar urethra on the perineal side was fixed to the adjacent tissues by its edges using a few interrupted sutures. The cystostomy line was closed in two layers with placement of a suprapubic catheter. The two wounds were then closed.

The urethral catheter is removed at 3–4 weeks postoperatively. If a patient with a clamped cystostomy can void for a week with no problems, the suprapubic catheter is then removed.

### RESULTS

With a mean follow-up of 23 months (range 3–53), seven of the nine patients, including the four in which a transperineal approach alone was used, regained satisfactory urination without incontinence. One patient, who had an open bladder neck and the disrupted level seemed to be high on cystourethrogram preoperatively (Fig. 6), has suffered from incontinence. In the remaining patient revised by means of the combined perineoabdominal approach, urethral disruption occurred again after

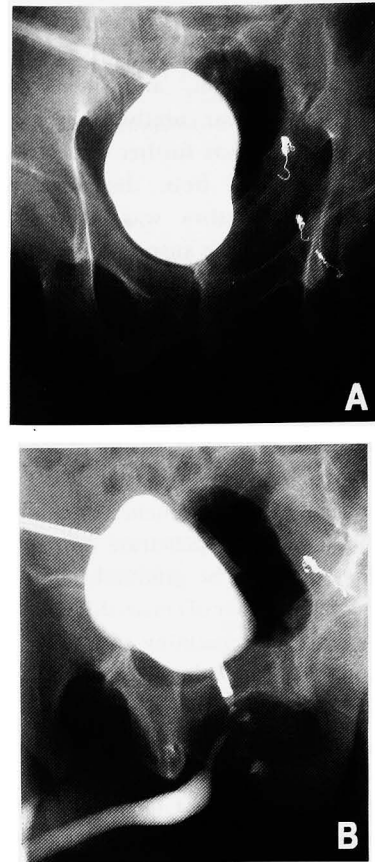


Fig. 6. A: Preoperative cystogram showed an open bladder neck. B: Preoperative combined cystourethrogram showed a remnant of the membranous urethra was delineated on the bulbar urethral site, which suggested the disruption was high around the prostatic apex (case 4).

removal of urethral catheter, and he has since been managed by resorting to a suprapubic catheter. The cause of the failure in that case might have been ischemia, since the separated bulbar urethra being unhealthy due to a previous operation and urine leakage continuing from the anastomosis site postoperatively. In the seven successful cases, a voiding cystogram or ascending urethrogram showed a patent anastomosis (Fig. 7), while urethroscopy showed healthy mucosa at the anastomosis site. However, recovery from the erectile dysfunction was not seen during the follow-up period in any patient.

### DISCUSSION

For a full exposition on the subject of traumatic disruption of the prostatic urethra, several issues would need to be discussed. These include etiologic and anatomic factors, controversies regarding the initial management, options for delayed surgical repair, and complications caused by the injuries<sup>6</sup>. However, in this paper we focus mainly on surgical or strategic tips that should be of help in informing the delayed surgical repair of urethral

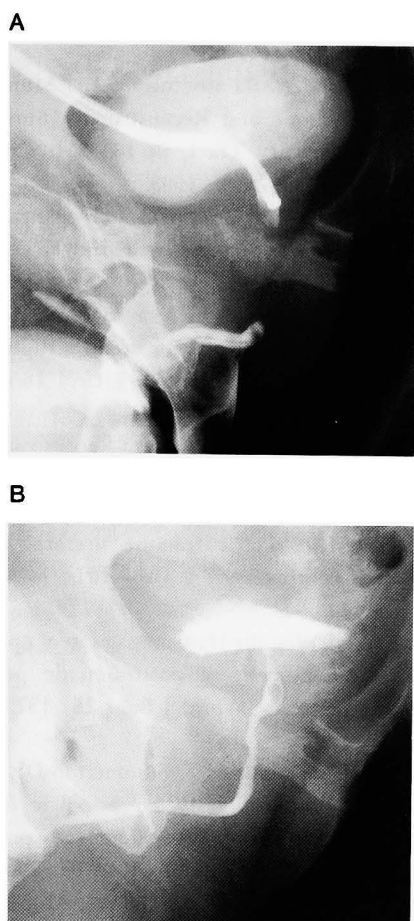


Fig. 7. A: Preoperative combined cystourethrogram showed a long urethral defect in case 3. B: Retrograde urethrogram showed a patent anastomosis site 3 months postoperatively.

distraction defect. Endoscopic repair was excluded from this article since we believe that while it can be adopted for a short segment of stricture, it is hardly applicable to a disrupted urethra replaced by scar tissue<sup>7)</sup> At present, the urethral defect seems to be best substituted only by the urethra. Our approach to a posterior urethral distraction defect is based on the principle of the perineo-abdominal progression approach described by Turner-Warwick<sup>1)</sup> Several other surgeons have followed this approach and devised some modifications<sup>2-5)</sup> These authors have insisted that the current trend is to repair a posterior urethral disruption through a transperineal approach, and indeed that most defects can be corrected only by the transperineal approach. Initially, we always tried to repair this type of injury through the transperineal approach. However, we met with many difficulties that finally resulted in failure. This was due to unexpectedly concrete scar tissues and probably to the acute angle of the pubic arch in the Japanese population. Thereafter, we adopted the perineo-abdominal progression approach. In our hands, this entails the multiple steps of the

transperineal approach, with the addition of the transabdominal approach when the former proves difficult.

#### *Transperineal approach*

It is generally accepted that the optimal method is a one-stage anastomotic repair, preferably performed through the perineum alone<sup>1-5)</sup>

In recent papers<sup>5,8)</sup>, the transperineal approach has been modified to include up to four additional steps according to difficulty of the individual situations: 1) further circumferential mobilization of the distal urethra as far as the suspensory ligament, 2) separation of the corporal bodies as far as possible, 3) inferior pubectomy, and 4) supra-crural re-routing of the distal urethra from the lateral surface of the corporal body. In our experience, the first two steps are generally sufficient for us to reach to the prostatic urethra without tension when the tip of the sound can be passed easily from the perineum, since the healthy bulbar urethra is elastic and can be easily stretched. However, when the distal part of the bulbar urethra is either unhealthy (and needs to be discarded), or shortened due to previous surgery, the last two steps may be required.

#### *Transperineoabdominal approach*

We believe it be a wise decision to convert to the transperineoabdominal approach without hesitation when any difficulty is encountered in the perineal approach. Since in Japanese people the perineal space below the pubic arch is narrow, we advise not to rely on the perineal approach alone. Hence, this combined approach should be in the surgeon's mind before the operation is even begun. This is the concept of the perineo-abdominal progression approach<sup>1)</sup> Actually, the combined approach is rather easier and safer because the anatomical relationships become clearer and more comprehensive, and the space for the anastomosis can be approached from both sides.

It is of utmost importance to create a tunnel in the pelvic diaphragm (probably thickened endopelvic fascia) under the pubic arch and above the level of the prostatic apex. Before making the tunnel, use of both index fingers (from the retropubic space and from the perineal side) enables us to find the best place for penetration of the thick membranous structure (Fig. 4A). Once a pathway has been created, the tunnel should be made as large as possible (for withdrawal of the spatulated bulbar urethra) by dilatation with metal sounds or by removing scar tissue by means of a diathermy (as shown in Fig. 4, 5). The sub-pubic-arch tunnel thus created is triangular in shape from the perineal view, and is closely compatible to the urogenital triangle (the apex of the triangle is the pubic arch and the bottom is the rectum). We believe this maneuver for creating a wide tunnel is the key to success if a proper

anastomosis is to be made in difficult cases. Even if some scar tissues remain caudal to the prostatic apex, the elastic bulbar urethra can easily bypass the scar for the purpose of anastomosis. Finally, the spatulated bulbar urethra is overlapped over the fenestrated mucosal hole in the rather anterior aspect of the prostate, just above the disrupted apex.

The lessons learned from our experience have been summarized here. It could be said that our personal experience is limited and our expertise still developing. However, we believe that the perineo-abdominal progression approach is versatile and can be applied to any difficult case. Although in the western hemisphere experienced surgeons may insist that most defects can be repaired by the perineal approach alone<sup>5,8)</sup>, we in Japan at least ought to keep in mind the possibility of its conversion into the perineo-abdominal approach. The main reasons for this are that in the Japanese population, the perineal triangle is narrow and the angle of the pubic arch apex is acute. Furthermore, the difficulty encountered in urethroplasty cannot be predicted preoperatively by the length of the defect<sup>8)</sup> nor can the degree of concrete fibrosis in the pelvis be predicted beforehand in a survivor of a serious injury. However, using the approach described here we should be able to overcome any difficulty, even if the situation is complicated or multiple procedures have previously failed<sup>9)</sup>.

#### REFERENCES

- 1) Turner-Warwick R: Urethral stricture surgery. In: Glenn JF (ed). Urologic Surgery (4th edition), pp 713–749, JB Lippincott Company, Philadelphia, 1991
- 2) Mundy AR: Urethral strictures. In: Mundy AR (ed). Urodynamics and Reconstructive Surgery of the Lower Urinary Tract, pp 185–251, Churchill Livingstone, Edinburgh, 1993
- 3) Koraitim MM: The lesson of 145 posttraumatic posterior urethral strictures treated in 17 years. *J Urol* **153**: 63–66, 1995
- 4) Corriere JN Jr: 1-stage delayed bulboprostatic anastomotic repair of posterior urethral rupture: 60 patients with 1-year followup. *J Urol* **165**: 404–407, 2001
- 5) Webster GD and Guralnick ML: Reconstruction of posterior urethral disruption. *Urol Clin North Am* **29**: 429–441, 2002
- 6) Koraitim MM: Pelvic fracture urethral injury: unresolved controversy. *J Urol* **161**: 1433–1441, 1999
- 7) Levine J and Wessells H: Comparison of open and endoscopic treatment of posttraumatic posterior urethral strictures. *World J Surg* **25**: 1579–1601, 2001
- 8) Andrich DE, O'Malley KJ, Summerton DJ, et al.: The type of urethroplasty for a pelvic fracture urethral distraction defect cannot be predicted preoperatively. *J Urol* **170**: 464–467, 2003
- 9) Wadhwa SN, Chahal R, Hemal AK, et al.: Management of obliterative posttraumatic urethral strictures after failed initial urethroplasty. *J Urol* **159**: 1898–1902, 1998

(Received on March 24, 2004)  
(Accepted on June 8, 2004)

## 和文抄録

## 後部尿道断裂の再建術：自験例および文献からみた成功のコツ

信州大学医学部泌尿器科（主任：西澤 理教授）

加藤 晴朗，小林 晋也，川上 雅子

井上 博夫，飯島 和芳，西澤 理

骨盤骨折に伴う後部尿道断裂の再建は，泌尿器外科医にとって困難な手術の1つである。われわれは後部尿道断裂で特に偏位を伴う完全断裂例における再建成功の技術的，戦略的コツについて述べる。9例の後部尿道完全断裂症例で，経会陰的あるいは経会陰腹的に修復術を試みた。以前に複数の再建術が不成功であった4例を含む。8例で再建に成功したが，術前，膀胱頸部の開いていた1例は尿失禁が残存している。1例は術後，再断裂し，膀胱瘻での管理となった。われわれの経験より，成功の鍵は球部尿道と前立腺尖部の粘

膜—粘膜吻合を妥協しないことである。そのために経会陰的に前立腺尖部が瘢痕組織や，骨折片により，十分に露出できないときは，引き続き経腹的なアプローチで前立腺尖部を露出することである。必要に応じて，恥骨下面を部分切除する。両アプローチにより，恥骨弓下に広いトンネルを作成し，吻合し易くするとともに，場合によっては瘢痕組織を迂回して球部尿道を前立腺尖部付近に吻合することも可能である。

(泌尿紀要 50 : 729-735, 2004)