

Title	Erosion of an inflatable penile prosthesis due to autoinflation
Author(s)	Kobayashi, Ko; Hisasue, Shin-ichi; Shimizu, Takashi; Itoh, Naoki; Tsukamoto, Taiji
Citation	泌尿器科紀要 (2004), 50(7): 515-517
Issue Date	2004-07
URL	<a href="http://hdl.handle.net/2433/113401">http://hdl.handle.net/2433/113401</a>
Right	
Type	Departmental Bulletin Paper
Textversion	publisher

## EROSION OF AN INFLATABLE PENILE PROSTHESIS DUE TO AUTOINFLATION

KO KOBAYASHI, Shin-ichi HISASUE, Takashi SHIMIZU,  
Naoki ITOH and Taiji TSUKAMOTO

*From the Department of Urology, School of Medicine, Sapporo Medical University*

A 59-year-old man presented with erosion of an inflatable penile prosthesis. The cylinders were not deflated and the right one protruded from the urethra. Autoinflation that causes failure of deflation is an annoying and embarrassing mechanical failure. This failure may cause intraurethral erosion of the prosthesis. Urologists should inform their patients who hope for implantation of an inflatable prosthesis of this potential adverse event prior to surgery.

(Acta Urol. Jpn. 50 : 515–517, 2004)

**Key words:** Erosion, Inflatable prosthesis, AMS700, Autoinflation

### INTRODUCTION

Implantation of a penile prosthesis is highly effective for management of erectile dysfunction (ED). The rate of satisfaction with penile prostheses ranges from 60% to 80%<sup>1)</sup>. However, various complications have been reported. Erosion of the penile prosthesis is one of the late complications. It occurs more frequently with a semi-rigid penile prosthesis than with an inflatable penile prosthesis. We present a case of erosion due to an unusual mechanical failure of an inflatable prosthesis.

### CASE REPORT

A 59-year-old man presented with erosion of a penile prosthesis. He had well-controlled diabetes mellitus, with oral medication. He initially underwent implantation of a semi-rigid prosthesis in 1984. He desired a reimplantation of the inflatable prosthesis (AMS 700, 18 cm cylinder; American Medical Systems, Minnetonka, Minnesota) and received it in 1991. He was satisfied with the inflatable prosthesis for 4 years. In 1995, he received an exchange of the tubing, pump, and reservoir due to mechanical malfunctions (leakage from the tubes). However, in 1999, he underwent reimplantation of the entire device because of malfunction (leakage from the tube and the cylinder), again. At that time, we used a 14 cm cylinder with a rear tip extender, because an 18 cm cylinder was not available. However, in October 2001 the cylinders of the penile prosthesis failed to deflate, and he suffered gradually progressing urethral pain. Finally he felt severe pain and visited our clinic in December 2001.

Physical examination revealed protrusion of the right cylinder of the penile prosthesis through the fossa navicularis of the distal urethra and foreign bodies beneath penile skin, which had no contact with the penile prosthesis (Fig. 1). The cylinders were in an autoinflation status, i.e., not deflated. We

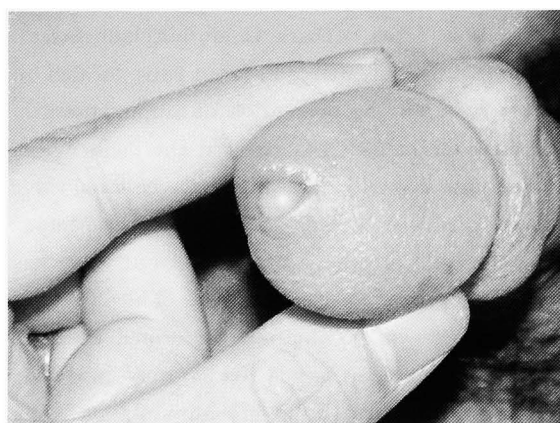


Fig. 1. Eroded penile prosthesis; the right cylinder was eroded from the fossa navicularis of distal urethra.

immediately removed the entire device because of malfunction of the prosthesis. There was no finding of infection in the urethra and the corpus cavernosum. Two years later, a new Mentor Alpha 1 penile prosthesis was implanted. Clinical use of this prosthesis was allowed by the Internal Review Board of our hospital (No. 15–16) and the patient agreed with its use after we fully informed him.

### DISCUSSION

Various complications have been reported in long-term follow-up of patients with penile prostheses. Infection is one of the early complications, and its incidence is reported to be 0.6% to 8.9%<sup>1)</sup>. Erosion of the penile prosthesis is one of the significant late complications. The erosion is related to several factors: a loss of distal penile sensation, over-sizing of the prosthesis, urethral catheterization, or autoinflation<sup>1–3)</sup>. The prevalence of erosion is more frequent with a semi-rigid prosthesis than with an

inflatable prosthesis<sup>2,4)</sup> In the current case, oversizing with inappropriate use of rear tip extenders might have accelerated its erosion during the autoinflation.

Because of improvement of the device, the re-operation rate for mechanical failure of the inflatable prosthesis is 5% at 5 to 10 years after implantation<sup>1)</sup>. In the current case, however, mechanical failure frequently occurred. Finally, failure of deflation due to autoinflation was the main cause of erosion in this patient. Both AMS and Mentor three-piece implants have been reported to have autoinflation as a complication<sup>3)</sup> In a review of the functional outcomes of the AMS 700CX, the incidence of autoinflation was reported to be 2.4%<sup>5)</sup> Mentor Corporation (Santa Barbara, California) launched an inflatable prosthesis with a lock-out valve located on the reservoir for the prevention of autoinflation<sup>1,3)</sup> This new mechanism has reduced the incidence of autoinflation to only 1.3%, while a conventional valve had an incidence of 11%<sup>6)</sup> However, the Mentor Alpha 1 penile prosthesis with a lock-out valve has not been approved for use in Japan. Thus, we used this prosthesis after obtaining informed consent, because the patient hoped for a new inflatable prosthesis to prevent annoying autoinflation. We may consider this prosthesis as a treatment option for the ED patient who desires a prosthesis other than the AMS 700.

A penile prosthesis that promises satisfactory sexual intercourse is the final choice for patients with ED refractory to sildenafil. Thus, urologists should inform patients who are indicated for inflatable penile

prostheses of the potential mechanical problems and adverse events.

### CONCLUSIONS

We encountered a patient with erosion of an inflatable penile prosthesis due to autoinflation. Sufficient information must be given to the patient prior to surgery, with regard to the possible adverse events due to malfunction.

### REFERENCES

- 1) Lewis RW and Jordan GH: Surgery for erectile dysfunction. In: Campbell's Urology. Edited by Walsh PC, Retik AB, Vaughan ED, et al. 8th ed, pp 1674-1688, Saunders, Philadelphia, 2002
- 2) Steidle CP and Mulcahy JJ: Erosion of penile prosthesis: a complication of urethral catheterization. *J Urol* **142**: 736-739, 1989
- 3) Carson CC: Urologic prostheses. Humana Press, Totowa, 2002
- 4) Hisasue S, Sato Y, Horita H, et al.: Erosion of a penile prosthesis due to an indwelling urethral catheter as a late complication. *Int J Urol* **9**: 525-527, 2002
- 5) Carson CC, Mulcahy JJ and Govier FE: Efficacy, safety and patient satisfaction outcomes of the AMS 700CX inflatable penile prosthesis: results of a long-term multicenter study. AMS 700CX Study Group. *J Urol* **164**: 376-380, 2000
- 6) Wilson SK, Henry GD, Delk JR Jr, et al.: The mentor Alpha 1 penile prosthesis with reservoir lock-out valve: effective prevention of auto-inflation with improved capability for ectopic reservoir placement. *J Urol* **168**: 1475-1478, 2002

(Received on January 19, 2004)  
(Accepted on March 15, 2004)

## 和文抄録

## 尿道より脱出したインフレータブル型陰茎プロステーシス

札幌医科大学泌尿器科学講座（主任：塚本泰司教授）

小林 皇, 久末 伸一, 清水 崇  
伊藤 直樹, 塚本 泰司

59歳の男性に尿道より脱出したインフレータブル型陰茎プロステーシスを経験した。プロステーシスの収縮が不可能となっており、外尿道口よりプロステーシスのシリンダー部分が脱出していた。プロステーシスが収縮できなくなる故障である Autoinflation はインフレータブル型の陰茎プロステーシスにおいて問題と

なる故障のひとつである。そしてこの故障はプロステーシスの脱出の原因となりうる。陰茎プロステーシス挿入術を行う前には、起こりうる合併症を理解し、患者に対し十分な説明が必要であると思われた。

(泌尿紀要 50 : 515-517, 2004)