

Title	A case of renal cell carcinoma found after skin metastasis
Author(s)	Mitsubishi, Makoto; Kiyota, Atsuhiko; Yoshimura, Rikio; Matsuyama, Masahide; Nakatani, Tatsuya; Wada, Seiji; Ito, Satoshi; Yoshimoto, Mitsuru; Funao, Kiyooki; Kobayakawa, Hitoshi; Nakao, Nobuki; Nakae, Akira
Citation	泌尿器科紀要 (2004), 50(4): 239-243
Issue Date	2004-04
URL	http://hdl.handle.net/2433/113356
Right	
Type	Departmental Bulletin Paper
Textversion	publisher

A CASE OF RENAL CELL CARCINOMA FOUND AFTER SKIN METASTASIS

Makoto MITSUHASHI, Atsuhiko KIYOTA, Rikio YOSHIMURA,
Masahide MATSUYAMA and Tatsuya NAKATANI
From the Department of Urology, Osaka City University Medical School

Seiji WADA, Satoshi ITO and Mitsuru YOSHIMOTO
From the Department of Urology, Ohno Memorial Hospital

Kiyoaki FUNAO and Hitoshi KOBAYAKAWA
From the Department of Urology, Osaka JR Hospital

Nobuki NAKAO and Akira NAKAE
From the Department of Surgery, Osaka JR Hospital

A case of renal cell carcinoma, found after skin metastasis is presented. A 79-year-old man visited Osaka JR hospital, complaining of a painless nodular mass on his right chest. The mass was resected and histopathological examination revealed a clear cell carcinoma (alveolar type, G1) with no involvement of the mammary gland. Abdominal ultrasound and magnetic resonance imaging revealed a heterogenous lower pole mass in the right kidney. Ultrasound-guided needle biopsy of the right renal mass was performed for histopathological diagnosis, which was clear cell carcinoma (alveolar type, G1). At that time, multiple metastases appeared in bilateral lung fields. The patient is currently receiving interferon- α therapy, without surgical treatment.

(Acta Urol. Jpn. 50: 239–243, 2004)

Key words: Renal cell carcinoma, Skin metastasis

INTRODUCTION

Renal cell carcinoma (RCC) is a significant lesion accounting for most malignant renal parenchymal neoplasms in adults and has been reported at all ages with a peak in the sixth decade¹⁾ Hematoma, abdominal mass, costvertebral angle pain, weight loss, weakness and fever are the most common symptoms of the carcinoma. Most carcinomas are hypervascular tumors that tend to spread either by direct invasion through the renal capsule into the perinephric fat and adjacent visceral structures or by direct extension into the renal vein. The biologic behavior of RCC is characteristically variable and the prognosis is unpredictable²⁾

Clear cell carcinoma is the most common histological subtype, found in approximately three-quarters of all RCC¹⁾ Some renal cell carcinoma may metastasize in the early phase, but skin metastasis, as the first detected lesion of this carcinoma type is still rare.

In this paper, a case of clear cell carcinoma in the right kidney found after skin metastasis detection is presented.

CASE REPORT

A 79-year-old man visited Osaka JR Hospital, complaining of a painless nodular mass in his right chest. The mass was about 1cm in diameter, smooth

surface and was not fixed to skin. He had suffered from diabetes mellitus and diabetic nephropathy for many years, and serum blood biochemistry showed hyperglycemia and high serum levels of creatinine (3.1mg/dL). He was admitted to Osaka JR Hospital and chest computerized tomography (CT) revealed a heterogeneous solitary mass in subcutaneous tissue on the right chest wall (Fig. 1). The mass was resected for histopathological diagnosis. The resected mass was surrounded by adipose tissue (Fig. 2), and histopathological examination revealed a

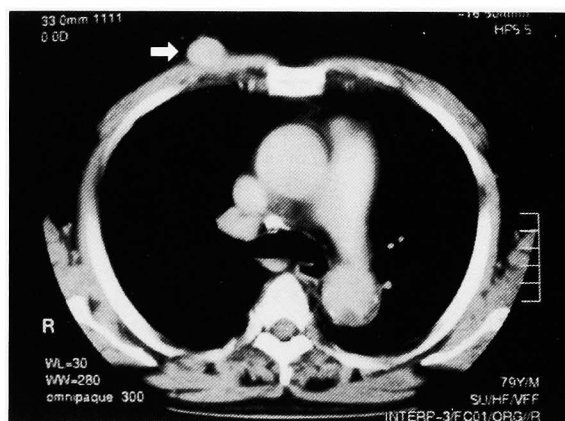


Fig. 1. Chest CT revealed a heterogenous solitary mass (arrow) in subcutaneous tissue on right chest wall.

clear cell carcinoma (alveolar type, G1); the tumor was encapsulated by fibrous and adipose tissues that were neither mammary glands nor lymph nodes (Fig.

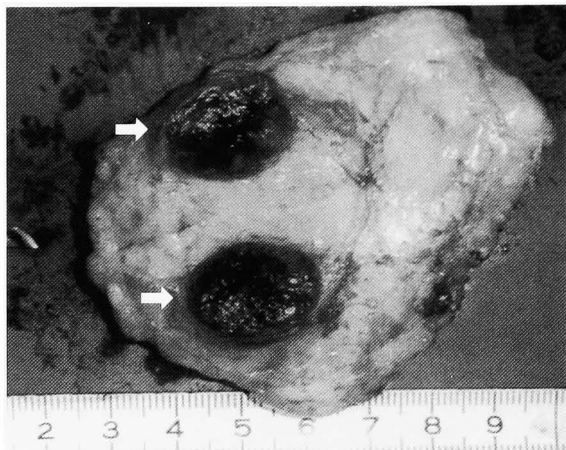


Fig. 2. Macroscopic appearance of the cross section of the resected mass (arrow); the mass was surrounded by adipose tissue.

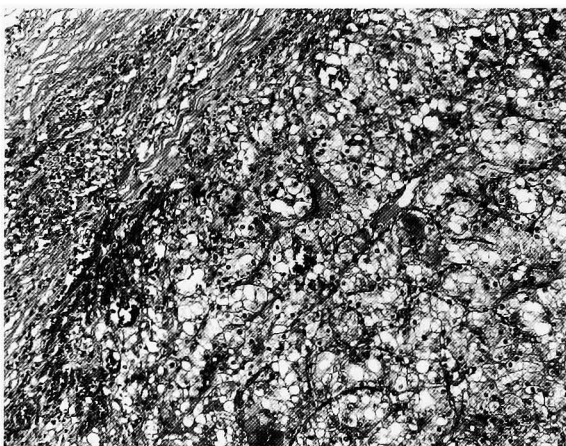


Fig. 3. Histopathological diagnosis of subcutaneous tumor of right chest was clear cell carcinoma, alveolar type, G1. We could not find any accessory organs of skin nor lymph nodes (H & E stain).

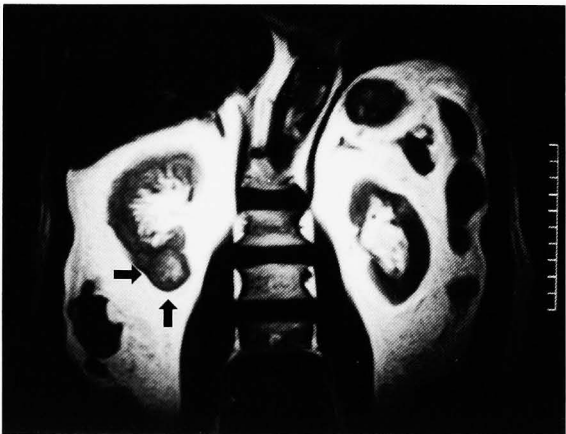

Fig. 4. Abdominal MRI revealed a heterogeneous lower pole mass (arrow) at the right kidney (T2 weighted).

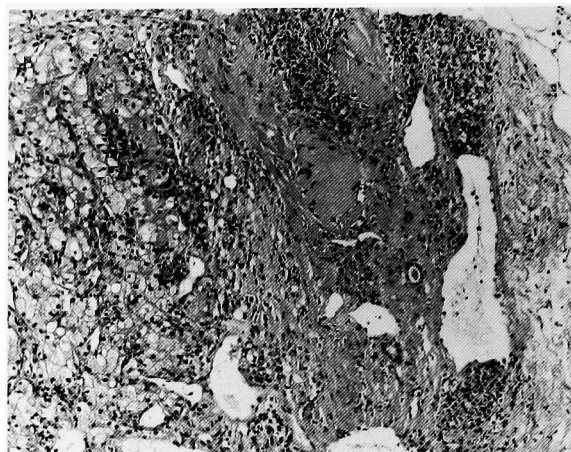


Fig. 5. Histopathological diagnosis of right renal tumor from biopsy samples was also clear cell carcinoma, alveolar type, G1 (H & E stain, $\times 200$).

3). The tumor was considered to be present in chest cutaneous tissue and suspected to be a metastatic lesion; therefore he was referred to the Department of Urology for further examination. Abdominal ultrasound and magnetic resonance imaging (MRI) revealed a heterogeneous lower pole mass (20 \times 20 mm) in the right kidney (Fig. 4). Because of hemodialysis therapy for treatment of chronic renal dysfunction, the patient was introduced to Ohno Memorial Hospital, and ultrasound-guided needle biopsy of right renal mass was performed. Histopathological diagnosis was clear cell carcinoma of the right kidney (alveolar type, G1) (Fig. 5). At the same time, chest computerized tomography revealed multiple metastases in bilateral lung fields. The patient is currently receiving interferon- α (IFN- α) therapy.

Discussion

RCC is the fourth most common tumor to metastasize and approximately one-third (40–50%) of the patients have metastatic disease at the time of diagnosis^{2,3}. Of these patients, 1.6–3.6% will have solitary metastasis⁴. The most common sites are lungs (50%), bone (33%) and contralateral kidney (26.5%)⁵. Regional lymph nodes, liver, adrenals and brain are also frequently involved³; but, cutaneous metastasis from renal cell carcinoma is believed to be rare. The metastases may arrive through the lymphatic or the blood stream⁵.

Brownstein et al.⁶ reviewed the 724 cases of metastatic skin carcinoma in the world and found that RCC was the fifth major cause of it in male humans, and Kishida et al.⁷ also reviewed the 62 cases of skin metastasis of RCC reported in Japan.

Twenty two cases of RCC found after skin metastasis as in our case have been reported in Japan⁸ (Table 1). The age of these patients ranged

Table 1. Case of RCC found after skin metastasis in Japan

Patient No.	Reporter	Year of reported	Age	Sex	Location of skin metastasis	No. of skin metastasis	Size	Location of other metastasis	Primary lesion	Treatment of metastasis	Survival after detection of metastasis
1	Imai et al.	1958	57	Male	Right upper limb	1	Hen's egg size	Lung ?	Left kidney	Skin biopsy only	30 months (death)
2	Morita et al.	1963	63	Male	Left temple	1	25 mm	Lung. bone	Right kidney	Skin biopsy only	6 months (death)
3	Honma et al.	1963	55	Male	Right shoulder, chest, abdomen	20	Soy bean size	Not shown	Right kidney	Skin biopsy only	Not shown
4	Kirimoto et al.	1965	60	Male	Face, head	2	Not shown	Bone ?	Not shown	Skin biopsy only	5 months (death)
5	Saitoh et al.	1967	62	Male	Not shown	Not shown	Not shown	Not shown	Right kidney		Not shown
6	Kon et al.	1968	48	Male	Left back	1	Not shown	Lung ?	Left kidney	Skin biopsy, angiography	Death
7	Miyoshi et al.	1973	48	Male	Right temple	1	20 mm	Not shown	Right kidney	Skin biopsy, angiography	Death
8	Nohara et al.	1974	48	Male	Right temple	1	25 mm	Not shown	Right kidney	Skin biopsy only	Not shown
9	Oguchi et al.	1974	45	Male	Occiput	1	11 mm	Not shown	Right kidney	Skin biopsy, nephrectomy	Not shown
10	Masuda et al.	1977	59	Male	Left chest	1	Not shown	—	Right kidney	Nephrectomy	29 months (alive)
11	Tomokichi et al.	1980	41	Male	Occiput	1	Not shown	Bone	Right kidney	Skin biopsy, nephrectomy	12 months (death)
12	Inai et al.	1986	67	Male	Left latus	1	35 mm	—	Right kidney	Skin biopsy, nephrectomy, IFN	34 months (alive)
13	Inai et al.	1986	71	Female	left shoulder	1	30 mm	Lung	Right kidney	Skin biopsy, nephrectomy, IFN	14 months (death)
14	Fujii et al.	1988	54	Male	Face	1	Not shown	Not shown	Left kidney	Skin biopsy, nephrectomy, IFN	Not shown
15	Akiyama et al.	1988	71	Male	Right femur, back, axilla	3	Not shown	Not shown	Left kidney	Skin biopsy, nephrectomy, IFN	Death
16	Narita et al.	1990	65	Male	Trunk	Multiple	Hen's egg size	Lung	Right kidney	Nephrectomy	4 months (death)
17	Kuwamitsu et al.	1990	64	Male	Abdomen	1	Walnut size	—	Left kidney	Skin biopsy, nephrectomy, IFN	Not shown
18	Minami et al.	1991	54	Female	Left femur	1	13 mm	—	Right kidney	Skin biopsy, nephrectomy, IFN	Not shown
19	Gotoh et al.	1991	53	Male	Right shoulder	1	Not shown	Adrenal gland	Left kidney	Skin biopsy, nephrectomy, IFN	Not shown
20	Umeda et al.	1992	45	Female	Head	1	9 mm	Lung brain	Left kidney	Skin biopsy, nephrectomy, IFN	6 months (alive)
21	Hamamoto et al.	1993	74	Female	Left temple	1	Not shown	—	Left kidney	Skin biopsy, nephrectomy, IFN	Not shown
22	Inoue et al.	1997	76	Female	Left chest	2	18 mm	Lung	Left kidney	skin biopsy, nephrectomy, IFN	36 months (alive)
23	Mitsubishi et al.	2003	79	Male	Right chest	1	15 mm	Lung	Right kidney	IFN	22 months (alive)

from 41 to 79 years old, and the mean age was 59.2 years old (Table 1). The ratio of sex was similar to that of total RCC (Table 1). The skin metastases were solitary in about 16 cases and the scalp was the most common site of skin metastasis, perhaps because the scalp is of rich vascularity but scant subcutaneous soft tissue, followed by abdomen, limb and shoulder. All reported RCC cases first identified from skin metastasis were G1⁸⁾, contrary to our expectation. It was only 5 cases without the metastasis to other organs (Table 1). The prognosis of the cases with metastasis to other organs was poor, but, surgical treatment was effective in the cases without other organ metastasis and better prognosis was achieved⁸⁾.

In general, most skin metastasis of RCC shows soft, clear-margined, hemisphere-shape and painless nodules⁸⁾. However some lesions were with pain and their pulsation palpable⁸⁾. However, a histopathological approach may be needed to make an accurate diagnosis⁸⁾.

In view of the treatment of the cases of RCC found after skin metastasis, it was said that radical surgery should be selected⁸⁾.

In the present case, we could not see any histopathological findings of tumor invasion into the mammary glands and the tumor was encapsulated by fibrous tissue and surrounding adipose tissue. Therefore, it should not be classified as metastasis of the mammary gland. Ability to recognize lesions similar to the present case is important for at least two reasons: 1) they can represent the first manifestation of a primitive lesion otherwise improperly

recognized; and 2) it may obviate radical surgical operations in the presence of widespread disease.

This paper presents a case of clear cell carcinoma of right kidney identified after skin metastasis.

REFERENCES

- 1) Pak CYC: Citrate and renal calculi. *Miner Electrolyte Metab* **13**: 257, 1987
- 2) Thomason PA, Peterson LS and Staniunas RJ: Solitary colonic metastasis from renal cell carcinoma 17 years after nephrectomy. *Dis Colon Rectum* **34**: 709, 1991
- 3) Al-Kassab BM and Foster ME: Recurrent facial metastasis from renal cell carcinoma: review of the literature and case report. *J Oral Maxillofac Surg* **53**: 74, 1995
- 4) Tolia BM and Whitmore WF: Solitary metastasis from renal cell carcinoma. *J Urol* **114**: 836, 1975
- 5) Storey DW and Mc Gowan B: Renal carcinoma metastasis in the salivary gland. *Br J Urol* **58**: 227, 1986
- 6) Browstein MH and Helwig EB: Patterns of cutaneous metastasis. *Arch Dermatol* **105**: 862–868, 1972
- 7) Kishida K, Hara Y, Kitami K, et al.: Renal cell carcinoma with late akin metastasis: a case report. *Surg Urol* **6**: 1067–1068, 1993
- 8) Inoue H, Oka D, Takao T, et al.: A Case of renal cell carcinoma found after skin metastasis. *Acta Urol Jpn* **43**: 723–726, 1997

(Received on June 5, 2003)
(Accepted on January 2, 2004)

和文抄録

皮膚転移によって発見された腎細胞癌の1例

大阪市立大学大学院泌尿器科学教室 (主任: 仲谷達也教授)

三橋 誠, 清田 敦彦, 松山 昌秀,
吉村 力勇, 仲谷 達也大野記念病院泌尿器科 (部長: 和田誠次)
伊藤 聡, 吉本 充, 和田 誠次大阪 JR 病院泌尿器科 (部長: 小早川等)
小早川 等, 舟尾 清昭大阪 JR 病院外科 (部長: 中江 晟)
中江 晟, 中尾 暢希

症例は79歳, 男性. 右胸部の無痛性腫瘍の自覚を主訴として, 大阪 JR 病院外科外来を受診した. 腫瘍を外科的に切除したところ病理組織学的診断は clear cell carcinoma (alveolar type, G1) であり, 乳腺組織との関連性は認められなかったため, 胸部皮膚組織への転移巣と考えられた. 全身検索を行ったところ腹部超音波検査および MRI 検査において右腎下極に内部不均一な腫瘍を認めた. 超音波エコーガイド下に針生検を行い病理組織診断が clear cell carcinoma

(alveolar type, G1) であったため原発巣と考えられた. 同時期になり両側肺野に多発性の腫瘍影が出現し, また患者からは積極的治療への同意をえられなかったため, 現在, インターフェロン- α 療法を施行されている. 当症例は胸部皮膚転移を契機として腎細胞癌が発見された比較的稀な1例であり, わが国では23例目の症例報告となる. よって文献的考察を加えて報告した.

(泌尿紀要 50 : 239-243, 2004)