

Title	Transurethral coil embolization for the management of ureteroarterial fistula : a case report
Author(s)	Takahashi, Akira; Nishiyama, Ryuichi; Kitahara, Mitsuteru; Hiura, Masaru; Kanaoka, Toshio; Hayashi, Tadashi; Hyotani, Genhachi; Matsuo, Yukinori; Tsutsui, Kazushige
Citation	泌尿器科紀要 (2004), 50(1): 53-56
Issue Date	2004-01
URL	<a href="http://hdl.handle.net/2433/113287">http://hdl.handle.net/2433/113287</a>
Right	
Type	Departmental Bulletin Paper
Textversion	publisher

## TRANSURETHRAL COIL EMBOLIZATION FOR THE MANAGEMENT OF URETEROARTERIAL FISTULA: A CASE REPORT

Akira TAKAHASHI, Ryuichi NISHIYAMA, Mitsuteru KITAHARA,  
Masaru HIURA, Toshio KANAOKA and Tadashi HAYASHI

*From the Department of Urology, Japanese Red Cross Society Wakayama Medical Center*

Genhachi HYOTANI

*From the Department of Neurosurgery, Japanese Red Cross Society Wakayama Medical Center*

Yukinori MATSUO and Kazushige TSUTSUI

*From the Department of Radiology, Japanese Red Cross Society Wakayama Medical Center*

A 71-year-old woman who had undergone a total abdominal hysterectomy and pelvic irradiation for cervical cancer and fecal diversion for adhesive ileus was referred to us for a “left” ureteral stone and intermittent gross hematuria. Bilateral ureteral stents had been indwelled because of lower ureteral strictures for a long time. Hematuria continued after the removal of the ureteral stone, and she once went into hypovolemic shock at the time of exchange of the right ureteral catheter. Selective arteriography revealed a “right” ureteroarterial fistula. Endovascular management alone failed to resolve the fistula, but a subsequent transurethral metal coil embolization was effective, and the hematuria was relieved. She is still free from disease at 7-month followup. As far as we know, there has been no previous report of a transurethrally managed ureteroarterial fistula.

(Acta Urol. Jpn. 50: 53–56, 2004)

**Key words:** Ureteroarterial fistula, Coil embolization, Transurethral management

### INTRODUCTION

Ureteroarterial fistula (UAF) is a rare but sometimes life-threatening entity, and is being increasingly reported recently. Most of these cases have some underlying conditions, and the correct diagnosis and proper management are often difficult. We report here the first case of UAF managed by transurethral coil embolization for a pseudoaneurysm.

### CASE REPORT

A 71-year-old woman who had undergone a total abdominal hysterectomy and pelvic irradiation for cervical cancer 9 years before and fecal diversion for adhesive ileus 8 years before was referred to us for a “left” ureteral stone and gross hematuria. Bilateral ureteral stents had been indwelled because of lower ureteral strictures for 18 months, and had been exchanged monthly. A “left” nephrostomy was placed for the treatment of the ureteral stone, and the ipsilateral ureteral stent was removed at a previous institute. Since the hematuria was intermittent and computed tomography (CT), urine cytology, cystoscopy testing did not reveal any abnormalities except for bladder mucosal changes compatible with radiation cystitis, the hematuria was considered to be caused by a “left” ureteral stone or radiation cystitis. Percutaneous nephrolithotripsy (PNL) was per-

formed and the stone was extracted completely. One week later, during an attempt to exchange the “right” ureteral stent, massive hemorrhage was encountered on removal of the stent using the Seldinger method, and the patient went into hypovolemic shock. Her blood pressure was not measurable at first but recovered to 100/60 after 4 units of transfusion. Retrograde ureterography at the time failed to show any bleeding origin. After the replacement of the ureteral stent, the hemorrhage stopped. Four days later, massive hemorrhage appeared again, and an emergent nephrectomy was performed, because renal bleeding (such as renal pelvic or caliceal damage caused by the catheterization maneuver) was suspected at the time. However, since the hemorrhage appeared 10 and 20 days after the nephrectomy, UAF was suspected. An emergent angiogram was performed, and a fistula between the right ureter and right external iliac artery was revealed (Fig. 1-A). Primary surgical repair was considered to be technically difficult because of her previous history of surgery and radiation therapy, so radiological intervention was selected. Two self-expandable Easy Wallstents were positioned to occlude the orifice of the fistula, which was almost excluded from the circulation on the postprocedural iliac arteriogram. One week later, the hemorrhage occurred again, and additional transurethral management was planned. Retrograde uretero-

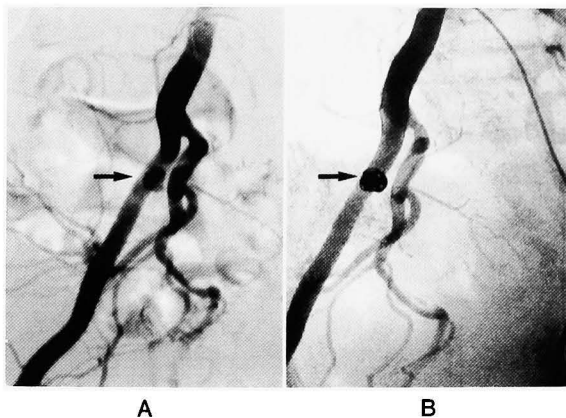


Fig. 1. 1-A: A fistula is shown as a pseudoaneurysm (arrow). 1-B: A pseudoaneurysm is filled with metal coils (arrow).

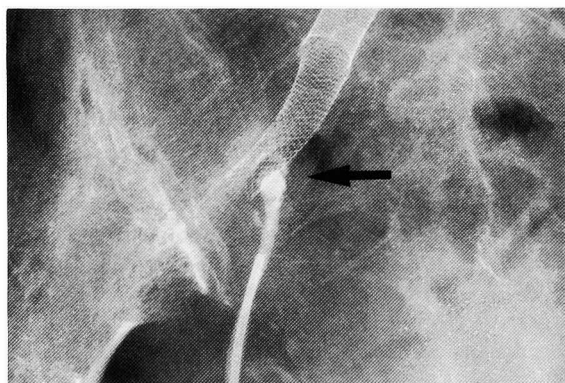


Fig. 2. Retrograde ureterography could show a pseudoaneurysm, and transurethral management was considered to be possible.

graphy showed a pseudoaneurysm (Fig. 2), and 8 metal coils were placed in it through a 5 Fr open-end ureteral catheter. No bleeding occurred after the transurethral procedure, and a follow-up arteriogram 1 month later demonstrated resolution of the fistula (Fig. 1-B). The patient is doing well at 7-month follow-up, without any hematuria or infection.

### DISCUSSION

To date, more than 70 cases of UAF have been reported. The predisposing risk factors for UAF include surgical trauma, previous vascular surgery and disease, pregnancy, urinary diversion, prior radiation and the use of indwelling ureteral stents<sup>1)</sup>. The etiology of UAF in association with indwelling ureteral stents has been attributed to pressure necrosis of the catheterized ureter against a pulsating vascular structure. The correct diagnosis can often be difficult; the reported positive rate of retrograde urography is 60% and that of angiography is only 30%<sup>2)</sup>. To increase the detection rate, some reports recommend a 'provocative arteriogram' with

immediately available surgical backup<sup>3,4)</sup>. The mortality rate is as high as 40% in some reports. Historically, primary surgical repair or vascular bypass was the only treatment modality. But with the development of radiological intervention, endovascular stent-grafts, which are often used for management of aneurysms, provide a less invasive alternative<sup>5-9)</sup>. There are 5 reports of UAF managed by this innovative modality, all of which provided a good prognosis, although long-term results are not yet available. In our case, the bleeding was so emergent that we could not construct a proper stent-graft, an autologous vein or a polytetrafluoroethylene "covered" stent, and thus an Easy Wallstent, a self-expandable metal "mesh" stent often used for the dilation of vascular stenosis, was placed instead. This did not provide complete resolution of the fistula, but played a role in avoiding the migration of transureterally inserted coils into the circulation. It might have been better, retrospectively, for the patient to receive the two procedures in one session, but this minimally invasive option may become the treatment of choice for UAF.

### REFERENCES

- 1) Batter SJ, McGovern EJ and Cambria RP: Ureteroarterial fistula: case report and review of the literature. *Urology* **48**: 481-489, 1996
- 2) Gheiler EL, Tefilli MV, Tiguert R, et al.: Angiographic arterial occlusion and extra-anatomical vascular bypass for the management of a ureteral-iliac fistula: case report and review of the literature. *Urol Int* **61**: 62-66, 1998
- 3) Keller FS, Barton RE, Routh WD, et al.: Gross hematuria in two patients with ureteral-iliac conduits and double-J stents. *J Vasc Interv Radiol* **1**: 69-77, 1990
- 4) Vandersteen DR, Saxon RR, Fuchs E, et al.: Diagnosis and management of ureteroiliac artery fistula: value of provocative arteriography followed by common iliac artery embolization and extraanatomic arterial bypass grafting. *J Urol* **158**: 754-758, 1997
- 5) Feuer DS, Ciocca RG, Nackman GB, et al.: Endovascular management of ureteroarterial fistula. *J Vasc Surg* **30**: 1146-1149, 1999
- 6) Ken-Ryu Han, Pantuck AJ, Siegel RL, et al.: Endovascular stent graft for management of ureteroarterial fistula after orthotopic bladder substitution. *Tech Urol* **5**: 169-173, 1999
- 7) Gibbons M, O'Donnell S, Lukens M, et al.: Treatment of a ureteroiliac artery fistula with an intraluminal endovascular graft. *J Urol* **159**: 2083-2084, 1998
- 8) Kerns DB, Darcy MD, Baumann DS, et al.: Autologous vein-covered stent for the endovascular management of an iliac artery-ureteral fistula: case

- report and review of the literature. *J Vasc Surg* **24**: 680–686, 1996
- 9) Kato N, Kawaguchi T, Kondo T, et al. : Ureteroarterial fistula : endovascular repair with a stent-graft. *Cardiovasc and Intervent Radiol* **25** : 158–159, 2002

(Received on April 30, 2003)  
(Accepted on October 10, 2003)

## 和文抄録

## 尿管腸骨動脈瘻に対し経尿道的にコイル塞栓術を行った1例

日本赤十字社和歌山医療センター第一泌尿器科（部長：林 正）

高橋 彰，西山 隆一，北原 光輝

日裏 勝，金岡 俊雄，林 正

日本赤十字社和歌山医療センター脳神経外科（部長：亀井一郎）

兵 谷 源 八

日本赤十字社和歌山医療センター放射線科（部長：筒井一成）

松尾 幸憲，筒井 一成

72歳，女性．子宮癌に対し子宮全摘術および放射線治療，また癒着性イレウスに対し人工肛門造設術施行．下部尿管狭窄に対し長期間尿管ステント留置されていた．左尿管結石の治療と間欠的な高度の血尿を主訴で紹介．結石摘出後も血尿は持続し，右尿管ステント交換時には出血性ショックになった．選択的腸骨動脈造影にて右尿管腸骨動脈瘻と診断．血管内ステント

留置のみでは瘻孔は閉塞できなかったが，その後の経尿道的金属コイル塞栓術は奏功し，血尿は軽快した．7カ月後の現在，再発は認めていない．同疾患に対し経尿道的処置で軽快した報告は現在まで見当たらない．

(泌尿紀要 50 : 53~56)